

Ibuprofen induced Stevens-Johnson syndrome - toxic epidermal necrolysis in Nepal

Siddheshwar S Angadi¹ and Abhishek Karn^{2,*}

¹College of Nursing, Chitwan Medical College, Bharatpur 44200, Nepal

²Department of Forensic Medicine and Toxicology, Universal College of Medical Sciences and Teaching Hospital, Siddharthanagar 32900, Nepal

Despite the fact that any drug can be an impending cause of hypersensitivity reactions, Ibuprofen, an over-the-counter drug used extensively as an analgesic and antipyretic in Asia, is considered to be relatively safe. But herein we report a rare extremely 'rapid onset' occurrence of a severe case of Stevens-Johnson syndrome (SJS) and toxic epidermal necrolysis (TEN) in a 22-year-old male, induced by 3 doses of 400 mg of Ibuprofen taken at 8-hour interval for eye pain, probably the first case report of rapid onset of TEN by nonsteroidal antiinflammatory drugs in Nepal. SJS and TEN are idiosyncratic, delayed hypersensitivity inflammatory adverse drug reactions that are severe adverse cutaneous drug reactions which predominantly involve the skin and mucous membranes and are linked with high morbidity and mortality. Nevertheless, removal of ibuprofen and its metabolites with plasma exchange and treatment with antibiotics and intravenous corticosteroids along with supportive therapy improved the course of the disorder. This rare case report addresses the fact that severe hypersensitivity reactions can occur with Ibuprofen, which can be potentially dangerous and life threatening. It is thus important for the clinicians to be alert to such severe hypersensitivity reactions even with drugs which are deemed to be probably safe.

Key words: Hypersensitivity; Ibuprofen; Immune System Diseases; Stevens-Johnson Syndrome

INTRODUCTION

Ibuprofen is a common over-the-counter antipyretic-analgesic nonsteroidal antiinflammatory drug whose principal effect is inhibition of cyclooxygenase (prostaglandin-synthase), thus impairing the final transformation of arachidonic

acid to prostaglandins, prostacyclin, and thromboxanes. Hypersensitivity-syndrome associated with ibuprofen is a host-dependent idiosyncratic drug-reaction [1].

Stevens-Johnson Syndrome (SJS) and toxic epidermal necrolysis (TEN) are life-threatening, bullous cutaneous diseases considered as immune-mediated reactions to drugs

Correspondence: Abhishek Karn

Department of Forensic Medicine & Toxicology, Universal College of Medical Sciences and Teaching Hospital, Ranigaon, Siddharthanagar 32900, Nepal

Tel: +977-71-525710

Fax: +977-71-524812

E-mail: dr.abhishekkarn@gmail.com

Received: July 15, 2015

Accepted: December 31, 2015

This is an Open Access article distributed under the terms of the Creative Commons Attribution. Non-Commercial License (<http://creativecommons.org/licenses/by-nc/4.0/>) which permits unrestricted non-commercial use, distribution, and reproduction in any medium, provided the original work is properly cited.

Copyright © 2016. Asia Pacific Association of Allergy, Asthma and Clinical Immunology.

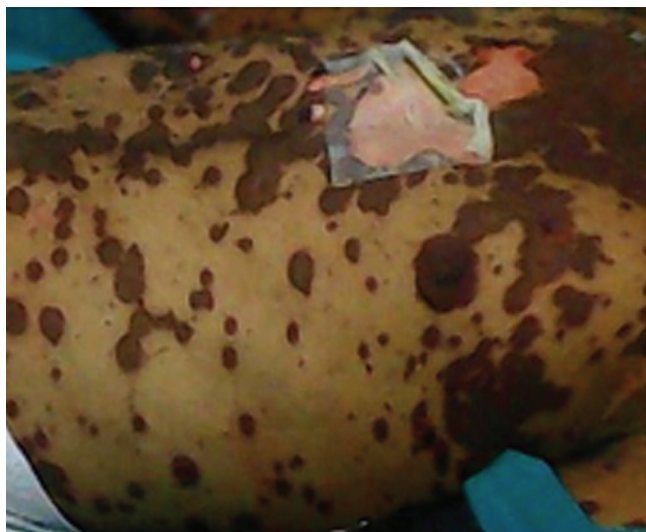


Fig. 1. Generalised erythematous macules on the trunk with few large confluent flaccid blisters and areas of full detachment.

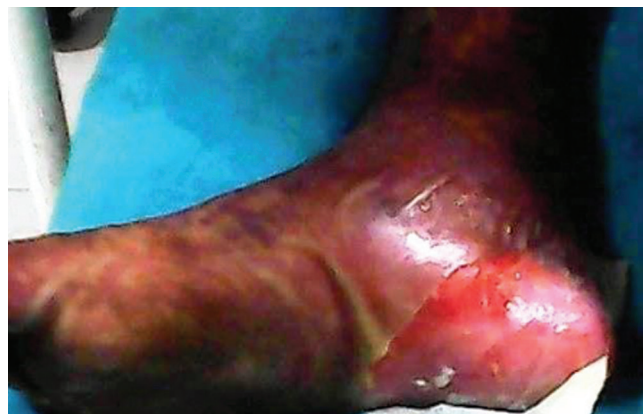

Fig. 2. Large confluent areas of full detachment of epidermis over heels.

characterized by epidermal necrosis, extensive detachment of the epidermis, erosions of mucous membranes and severe constitutional symptoms [2, 3]. This case describes a rare documented rapid-onset hypersensitivity of Ibuprofen causing SJS-TEN in a Nepali male.

CASE REPORT

A 22-year-old Nepali male came to the Emergency Department of a teaching-hospital in central Nepal with chief complaint of sudden appearance of blisters on oral mucosa after taking Ibuprofen 400-mg tablets 8 hourly for 2 days for eye pain. He developed multiple maculae initially over trunk, then chest, face, lower limbs on the third day. He was admitted to the Emergency and upon examination, had extensive erythema (Fig. 1), necrosis, and exfoliating bullous detachment of the epidermis (Fig. 2) and mucous membranes (conjunctival, oral, and genital), with a positive Nikolsky's sign. The body temperature was 38°C, respiratory rate being 24 breaths/min, pulse rate 110 beats/min, blood pressure 130/90 mm Hg, SPO₂ 98%, and glucose random blood sugar 91 mg/dL.

The laboratory analyses are as follows: Na⁺, 138.8 mmol/L; K⁺, 4.02 mmol/L; urea, 41.0 mg/dL; creatinine, 1.0 mg/dL; platelet count, 60,000 mm³, white blood cell, 3,600×10⁶/L; hemoglobin, 11.8 g/dL; prothombin (test), 17.5 seconds; prothombin (control),

13.0 seconds; international normalized ratio, 1.37; packed cell volume, 32.05%; bleeding time, 3 minutes; clotting time, 9 minutes; immunodeficiency virus I&II, nonreactive; hepatitis B surface antigen, nonreactive; urine routine examination, pus cells (8–10); C-reactive protein level, 340 mg/L; aspartate aminotransferase, 85 IU/L; alanine aminotransferase, 150 IU/L; total proteins concentration, 50 g/L; and albumin, 20 g/L.

Skin biopsy revealed prominent cell death with basal vacuolar changes and lymphocyte infiltrates with haziness in the dermo-epidermal junction which corroborated the clinical diagnosis of SJS-TEN.

Ibuprofen was immediately withdrawn and the patient was transferred to the intensive care unit (ICU). On admission to ICU, arterial blood gas analyses are as follows: pH, 7.442; pCO₂, 28.5; pO₂, 95.5; HCO₃, 19.7; blood urea nitrogen, 17.0 mg/dL; blood-sugar random, 162.0; antinuclear antibody enzyme linked immune sorbant assay method, negative.

Patient had extensive sloughing off the face (Fig. 3) painful oral erosions with severe crusting of the lips and increased salivation. The plaques with vesicles, sloughed off more than 50% of body surface area which rendered difficulty to access vein on patients limbs. So, central venous pressure line insertion was done and enteral-nutrition was provided via a nasogastric tube. The patient's specific treatment with plasma exchange and fluid resuscitation with crystalloid infusions (1 mL/kg of body weight per hour) fine-tuned on the bases of the arterial blood pressure (>65 mm Hg), central venous pressure (≤10 mm Hg) and diuresis rate [4] was done. The basis for early plasma exchange was to remove/reduce the level of residual ibuprofen and its metabolites,

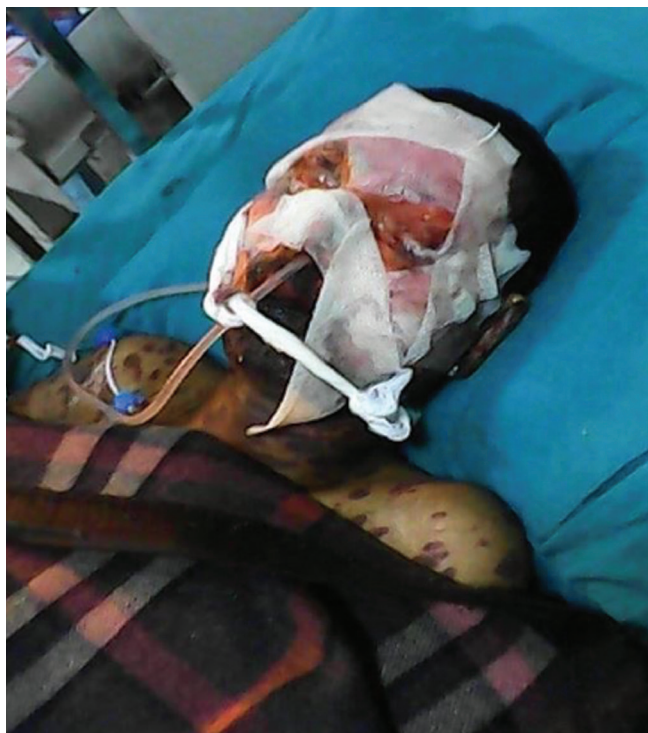

Fig. 3. The patient with nasogastric tube and extensive sloughing off of epidermis of the face.

critical cytokines (tumor necrosis factor- α [TNF- α], interferon- γ [IFN- γ]), and drug-induced inflammatory mediators (perforin, granzyme-B released from cytotoxic T-lymphocytes and granulysin secreted by cytotoxic T-lymphocytes and natural killer cells) from the circulation [4]. However, the plasma exchange remain unsupported by controlled studies [5]. Subsequent systemic treatment included intravenous Ceftriaxone 1.0 gm 12 hourly (microbial findings on skin: *Staphylococcus aureus* and *Pseudomonas aeruginosa*; the symptoms and signs being warm, tender, erythematous, and edematous plaque over lower extremities with ill-defined borders), intravenous immunoglobulins (IVIG) 1.0-g/kg body weight/day infused over 6 hours for 3 successive days and corticosteroids 0.5-mg/kg body weight. Intravenous tramadol 25 mg was given for analgesia as per the patient's condition. The patient recovered completely after 5 weeks of intensive systemic and topical treatment.

DISCUSSION

SJS-TEN is a severe life threatening mucocutaneous syndrome

caused by hypersensitivity to drugs and is associated with significant morbidity and mortality [6]. It is important to suspect the culprit drug by the temporal relationship (2 days to 8 weeks) [7] but the extremely 'rapid onset' in this case. The exact aetiopathogenesis being imprecise, is thought that some noxious metabolites, inflammatory mediators/modifiers, as well as cytotoxic T-lymphocytes, regulatory T cells and dermal-dendrocytes could provoke apoptosis/necrosis of epithelial cells [8-10]. The human leucocyte antigen (HLA) system also plays an important role in the pathogenesis of TEN, since some drugs may bind directly to the HLA-complex and create self-reactivity due to the drug-modified HLA-peptide repertoire [10].

We must take in consideration that regional differences in drug prescription, the genetic background of patients (HLA, metabolizing enzymes) [11, 12], can have an impact on the incidence so a detailed drug history is extremely significant when go-getting to recognize the offender drug in SJS-TEN.

Initial symptoms of SJS-TEN can be unspecific like fever, stinging eyes and discomfort upon swallowing which precede cutaneous manifestations by a few days [13]. Early sites of cutaneous involvement are the presternal region of the trunk, face, palms, and soles. Erythema and erosions of the buccal, genital and/or ocular mucosa occurs in more than 90% of patients, with respiratory and gastrointestinal-tracts affected in few [14].

Prompt removal of causative drug should be the priority and the reported likelihood of a drug causing SJS-TEN can be found in PubMed/MEDLINE or the Litt's-drug-eruption reference manual [15]. Urgent plasma depuration (remain unsupported by controlled studies) [5] with supportive care by management of fluid and electrolyte requirements should be done. Wounds are treated conservatively, without skin debridement as blistered skin acts as a natural biological-dressing which favors re-epithelialization [13]. Topical and systemic medications (antibiotics if infection suspected, IVIG and corticosteroids) should be administered which prevents septicaemia and multisystem organ failure, the major cause of death in SJS-TEN. Recent case reports/series on the use of intravenous methylprednisolone with IVIG, and corticosteroids with infliximab and IVIG have been reported to be effective in arresting progression of TEN and reducing mortality [5].

IVIG, a highly purified IgG possessing anti-Fas activity, anti-infective properties also correcting protein and fluid loss, has for its support multiple, open-label, prospective studies,

retrospective case series, and case reports as evidences [16].

Corticosteroids believed to act by suppressing the cytotoxic T-lymphocytes and inhibiting IFN- γ mediated apoptosis, with pleomorphic effects on the immune system including inhibition of chemokines and numerous cytokines like TNF- α [17], are found useful in achieving early control [18].

REFERENCES

1. Nanau RM, Neuman MG. Ibuprofen-induced hypersensitivity syndrome. *Transl Res* 2010;155:275-93.
2. Auquier-Dunant A, Mockenhaupt M, Naldi L, Correia O, Schröder W, Roujeau JC; SCAR Study Group. Severe cutaneous adverse reactions. Correlations between clinical patterns and causes of erythema multiforme majus, Stevens-Johnson syndrome, and toxic epidermal necrolysis: results of an international prospective study. *Arch Dermatol* 2002;138:1019-24.
3. Bastuji-Garin S, Rzany B, Stern RS, Shear NH, Naldi L, Roujeau JC. Clinical classification of cases of toxic epidermal necrolysis, Stevens-Johnson syndrome, and erythema multiforme. *Arch Dermatol* 1993;129:92-6.
4. Balint B, Stepic N, Todorovic M, Zolotarevski L, Ostojic G, Vucetic D, Pavlovic M, Novakovic M. Ibuprofen-induced extensive toxic epidermal necrolysis: a multidisciplinary therapeutic approach in a single case. *Blood Transfus* 2014;12:438-9.
5. Thong BY. Stevens-Johnson syndrome / toxic epidermal necrolysis: an Asia-Pacific perspective. *Asia Pac Allergy* 2013;3:215-23.
6. Mockenhaupt M. Stevens-Johnson syndrome and toxic epidermal necrolysis: clinical patterns, diagnostic considerations, etiology, and therapeutic management. *Semin Cutan Med Surg* 2014;33:10-6.
7. Kim EJ, Lim H, Park SY, Kim S, Yoon SY, Bae YJ, Kwon HS, Cho YS, Moon HB, Kim TB. Rapid onset of Stevens-Johnson syndrome and toxic epidermal necrolysis after ingestion of acetaminophen. *Asia Pac Allergy* 2014;4:68-72.
8. Yalcin AD, Karakas AA, Soykam G, Gorczynski RM, Sezer C, Bisgin A, Strauss LG. A case of toxic epidermal necrolysis with diverse etiologies: successful treatment with intravenous immunoglobulin and pulse prednisolone and effects on sTRAIL and sCD200 levels. *Clin Lab* 2013;59:681-5.
9. Aires DJ, Fraga G, Korentager R, Richie CP, Aggarwal S, Wick J, Liu DY. Early treatment with nonsucrose intravenous immunoglobulin in a burn unit reduces toxic epidermal necrolysis mortality. *J Drugs Dermatol* 2013;12:679-84.
10. Lee HY, Chung WH. Toxic epidermal necrolysis: the year in review. *Curr Opin Allergy Clin Immunol* 2013;13:330-6.
11. Aguiar D, Pazo R, Duran I, Terrasa J, Arrivi A, Manzano H, Martín J, Rifa J. Toxic epidermal necrolysis in patients receiving anticonvulsants and cranial irradiation: a risk to consider. *J Neurooncol* 2004;66:345-50.
12. Aydin F, Cokluk C, Senturk N, Aydin K, Canturk MT, Turanli AY. Stevens-Johnson syndrome in two patients treated with cranial irradiation and phenytoin. *J Eur Acad Dermatol Venereol* 2006;20:588-90.
13. Harr T, French LE. Toxic epidermal necrolysis and Stevens-Johnson syndrome. *Orphanet J Rare Dis* 2010;5:39.
14. Lebargy F, Wolkenstein P, Gisselbrecht M, Lange F, Fleury-Feith J, Delclaux C, Roupie E, Revuz J, Roujeau JC. Pulmonary complications in toxic epidermal necrolysis: a prospective clinical study. *Intensive Care Med* 1997;23:1237-44.
15. Litt JZ. *Litt's drug eruptions and reactions manual*. 16th ed. London: Informa Healthcare; 2010.
16. Momin SB. Review of intravenous immunoglobulin in the treatment of stevens-johnson syndrome and toxic epidermal necrolysis. *J Clin Aesthet Dermatol* 2009;2:51-8.
17. Kardaun SH, Jonkman MF. Dexamethasone pulse therapy for Stevens-Johnson syndrome/toxic epidermal necrolysis. *Acta Derm Venereol* 2007;87:144-8.
18. Jagadeesan S, Sobhanakumari K, Sadanandan SM, Ravindran S, Divakaran MV, Skaria L, Kurien G. Low dose intravenous immunoglobulins and steroids in toxic epidermal necrolysis: a prospective comparative open-labelled study of 36 cases. *Indian J Dermatol Venereol Leprol* 2013;79:506-11.