

LETTER TO THE EDITOR

Acanthosis Nigricans of the Ears or Terra Firma-Forme Dermatosis?

David R. Berk, M.D.

Division of Dermatology, Department of Internal Medicine and Pediatrics, Washington University School of Medicine and St. Louis Children's Hospital, St. Louis, MO, USA

To the editor,

I read with great interest the case report by Lee et al.¹ describing an obese young man with brown, dirt-like plaques on the sulci of the ears. The lesions were biopsied and diagnosed as acanthosis nigricans, which he also had on the neck, axillae, and groin. I would like to suggest a different diagnosis - terra firma-forme dermatosis. I wonder if slightly more aggressive rubbing with an alcohol swab might have significantly cleared the patient's lesions. I have often observed comparable dirt-like papules or plaques in this location in my patients who are obese and

have darker skin types (Fig. 1). While these lesions may show overlapping features of (or occur in conjunction with) acanthosis nigricans, confluent and reticulated papillomatosis, and terra firma-forme dermatosis, they frequently demonstrate rapid and significant response or clearing with alcohol swabbing (Fig. 2). Finally, the lack of acanthosis in the biopsy of the patient of Lee et al.¹ further puts the diagnosis of acanthosis nigricans in question. Because terra firma-forme dermatosis is rarely biopsied, the literature is lacking in histological descriptions for comparison.

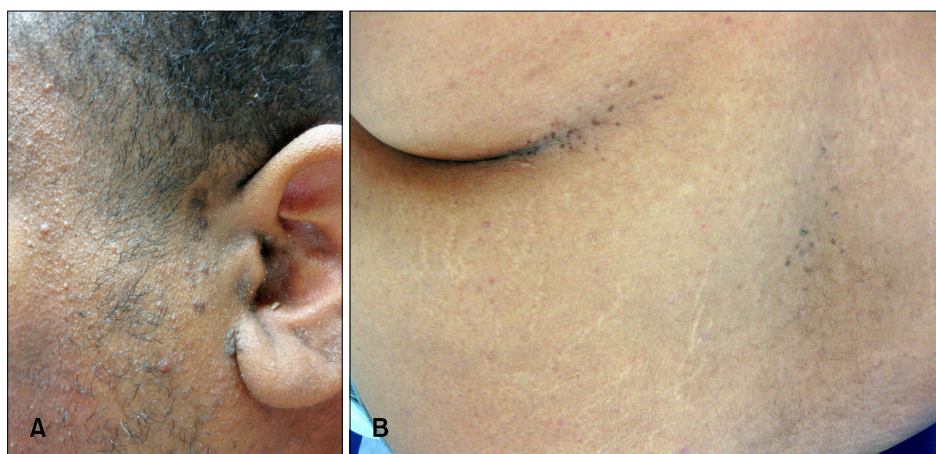


Fig. 1. (A, B) A 32-year-old African-American man with a many year history of bothersome, progressive, dirt-like, brown papules and plaques in the preauricular area, sulci of ear, cheeks, chest, neck, and folds on back, despite normal hygiene and many attempts by the patient to scrub off the lesions with soaps.

Received December 27, 2010, Revised January 11, 2011, Accepted for publication January 11, 2011

Corresponding author: David R. Berk, M.D., Campus Box 8123, 4921 Parkview Place, St. Louis, MO 63110, USA. Tel: 1-314-747-3679, Fax: 1-314-747-8693, E-mail: daveberk_2000@yahoo.com

This is an Open Access article distributed under the terms of the Creative Commons Attribution Non-Commercial License (<http://creativecommons.org/licenses/by-nc/3.0>) which permits unrestricted non-commercial use, distribution, and reproduction in any medium, provided the original work is properly cited.

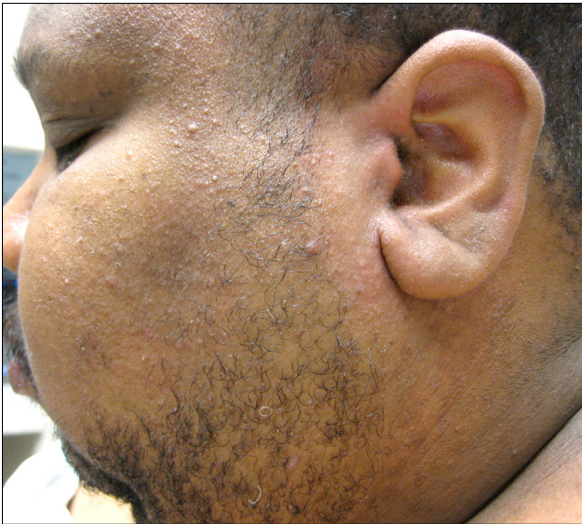

Fig. 2. Most of the patient's lesions, including around and involving the ear, markedly improved or cleared with gentle rubbing with an alcohol swab.

REFERENCE

1. Lee YB, Lee JD, Cho SH. Unusual presentation of obesity-associated dermatoses: acanthosis nigricans involving both auricles. *Ann Dermatol* 2010;22:463-464.