

Three Cases of Facial Atopic Dermatitis Treated with Topical Pimecrolimus (Elidel)

Young Hyun Joo, M.D., Chong Hyun Won, M.D., Kyu Han Kim, M.D.

Department of Dermatology, Seoul National University College of Medicine, Seoul, Korea

Pimecrolimus (Elidel) is an ascomycin derivative macrolide antibiotic, newly developed for the treatment of atopic dermatitis (AD). Three patients with facial AD resistant to other therapies, including topical corticosteroid, were treated with 1% pimecrolimus cream. Their facial lesions rapidly improved within two weeks of applying topical pimecrolimus cream. No appreciable side effects were observed after application of the topical pimecrolimus cream. Topical pimecrolimus is considered to be a good treatment modality for facial AD, especially in the cases resistant to conventional topical therapies including steroids. (*Ann Dermatol* 16(3) 120~124, 2004)

Key Words: Pimecrolimus, Elidel, Facial atopic dermatitis

INTRODUCTION

Topical pimecrolimus (Elidel) is distinct from other medications currently available for the topical treatment of atopic dermatitis (AD). This includes topical corticosteroids. Elidel targets the immunological pathway important for the development of AD, but does not cause any apparent effects on the immune system or cause dermal thinning. The efficacy and safety of Elidel have been demonstrated in patients with mild-to-moderate AD. Successful topical Elidel therapy in Korea has not yet been reported. Here, we report three cases of facial AD treated with 1% Elidel cream, which have had excellent clinical results without significant side effects.

CASE REPORT

Case 1

A 21-year-old woman visited our clinic with

erythematous, pruritic, and scaly skin lesions evenly distributed on her face (Fig. 1). She had a long history of AD since childhood. Her facial lesions initially responded to topical corticosteroid treatment, but then became resistant to this medication. She did not have any special past medical or family history. 1% Elidel cream was applied to her facial lesions twice a day. Within 2 weeks of the applica-

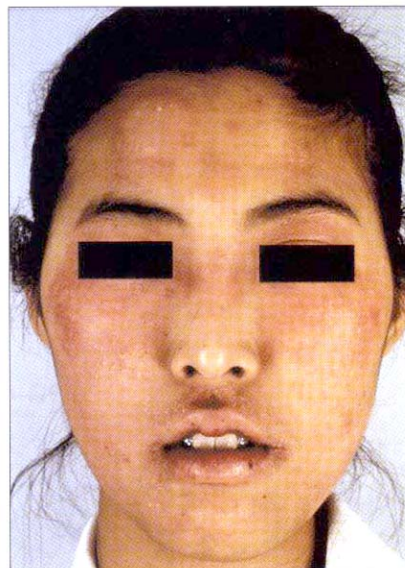

Fig. 1. The facial atopic lesion in Case 1: prior to treatment with Elidel.

Received April 6, 2004

Accepted for publication July 24, 2004

Reprint request to: Kyu Han Kim, M.D., Department of Dermatology, Seoul National University Hospital, 28 Yongon-dong, Chongno-gu, Seoul 110-744, Korea.

Tel. 82-2-760-2417, 2418, Fax: 82-2-742-7344

E-mail. kyuhkim@snu.ac.kr

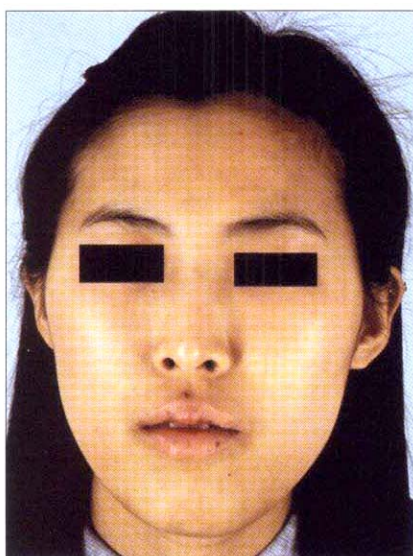


Fig. 2. The facial atopic lesion in Case 1: 2 weeks after the application of 1% Elidel cream.

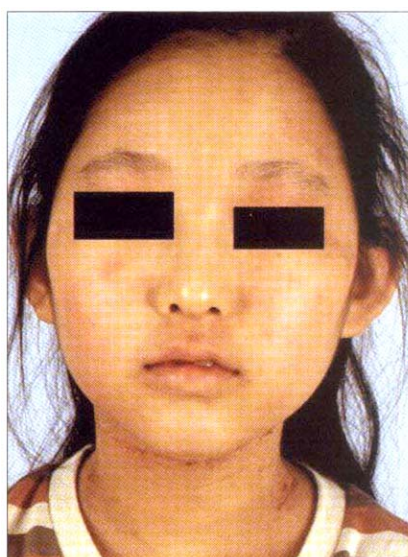

Fig. 3. The facial atopic lesion in Case 2: prior to treatment with Elidel.

tion, dramatic clinical improvement was noted (Fig. 2). Although we treated her with oral antihistamine in combination with Elidel, topical corticosteroid has been used to manage AD lesions on her body area apart from her face. No side effects were observed during the Elidel application. With an intermittent application of topical Elidel, her facial lesions were clinically well maintained.

Case 2

An 11-year-old girl visited our clinic with facial AD. She suffered from frequent relapses and flare-ups while using topical corticosteroids (Fig. 3). We performed a laboratory examination and a skin prick test for food allergens, which all showed normal results except for peripheral blood eosinophilia. After two weeks of a twice-a-day application of 1% Elidel cream to her facial lesions, pruritus and erythema decreased significantly (Fig. 4). Side effects were not observed during the application of Elidel. The recurrence or flare-up of lesions was not observed after 3 months of treatment.

Case 3

A 23-year-old woman visited our clinic with a history of AD which had not responded to conventional topical corticosteroids. Her lesions were primarily on the face but there was an absence of severe pruritus (Fig. 5). As with the former patients, her

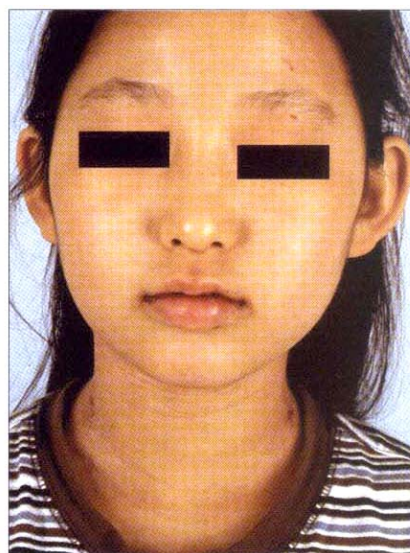

Fig. 4. The facial atopic lesion in Case 2: 2 weeks after the application of 1% Elidel cream.

facial lesions significantly improved within two weeks of applying Elidel cream (Fig. 6). Complications, such as a burning sensation, did not occur.

DISCUSSION

Atopic dermatitis (AD) is a chronic and inflam-

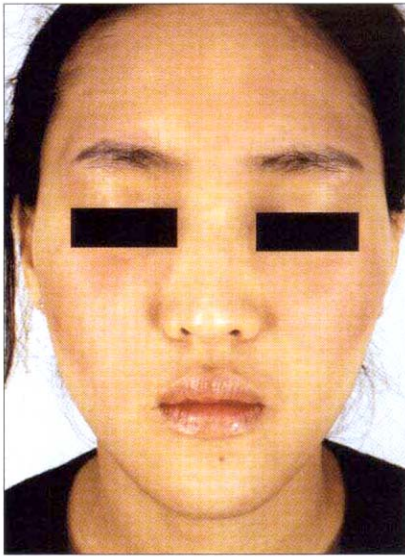

Fig. 5. The facial atopic lesion in Case 3: prior to treatment with Elidel.

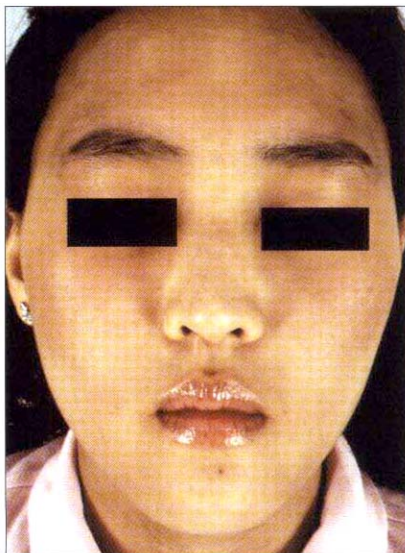

Fig. 6. The facial atopic lesion in Case 3: 2 weeks after the application of 1% Elidel cream.

matory skin disorder characterised by erythematous, eczematous, and highly pruritic lesions. Central to the pathogenesis of AD are hyperreactive cutaneous T cells which release proinflammatory cytokines¹⁻³. The release of cytokines by cutaneous T cells orchestrates the inflammatory process. The pivotal role of T-cell activity in the inflammatory process suggests that their activation might serve as an

important therapeutic target in AD treatment.

Although many drugs are available for AD, all AD drugs have side effects that limit their use. In the treatment of AD with systemic immunosuppressants, for example, the most important acute adverse effect is non-specific immunosuppression that potentially leads to cutaneous and extracutaneous infections.

Similarly, topical corticosteroids are associated with adverse local effects, such as dermal atrophy, acneiform eruption, striae, and telangiectasia. Furthermore, topical corticosteroids have been reported to be associated with the risk of systemic side effects, such as hypothalamic-pituitary-adrenal axis suppression^{4,8}. The most common cause of dissatisfaction with topical corticosteroids is the frequent rebound of AD after a long period of application. This stimulated the search for nonsteroidal alternatives that could safely and selectively suppress the hyper-immune response in AD. The immune suppressor, cyclosporin A, is ineffective as a topical agent because its large molecular size disallows it to be delivered to the AD lesions⁹. Being active in the topical form, the immune suppressor, Tacrolimus, has been shown to be effective in the treatment of AD in clinical trials. However, Tacrolimus, has also been reported to cause frequent local side effects, including transient burning, pruritus, and erythema¹⁰⁻¹².

The ascomycin derivative ASM 981 (pimecrolimus, Elidel) is a macrolide topical immunomodulator with a molecular weight of 810 Da. Elidel binds to macrophilin 12 with high affinity. The complex is a potent inhibitor of the calcium-dependent phosphatase calcineurin^{13,14}. Elidel thus blocks the calcineurin-dependent early transcription of the cytokine genes which are necessary for the activation of T cells. Elidel inhibits the expression of a variety of cytokines such as the T_H2-type cytokines IL-4 and IL-10, as well as the T_H1-type cytokines IL-2 and IFN- γ ¹⁴. In addition, Elidel prevents the release of inflammatory cytokines and effector molecules preformed from mast cells in response to antigen-IgE stimulation *in vitro*¹⁵. Hence, the clinical effects of Elidel are thought to be due to its inhibition of the release of cytokines and other proinflammatory mediators from T cells, basophils and mast cells.

The therapeutic efficacy of topical Elidel in the management of AD has been evaluated in adults, children and infants in eight randomized, double-blind, vehicle-controlled studies¹⁶⁻²⁵. In a 1-year

study of pediatric patients with AD, Elidel significantly reduced the incidence of flare-ups as well as the use of second-line topical corticosteroids²⁶.

The presently known side effects of Elidel are localized burning, the feeling of warmth and headaches in about ten percent of patients^{28,29}. Elidel has a higher overall lipophilicity than tacrolimus. This property may give Elidel a low potential for penetrating through the skin and entering the systemic circulation²⁹. Therefore, Elidel may be more selective for the skin with the low potential in suppression of systemic immune function. In addition, in contrast to its lack of effect on the sensitisation phase, Elidel inhibits the elicitation phase, i.e., the clinical manifestation of AD in a dose-dependent manner with the therapeutic efficacy comparable to tacrolimus³⁰.

In our cases, Elidel was applied to the facial AD lesions that did not respond to topical corticosteroids. Within 2 weeks of a twice-a-day application, Elidel clinically improved the lesions. The patients had less pruritus, less erythema, and less excoriations. In conclusion, 1% Elidel cream may provide clinicians with a safer and more effective nonsteroidal alternative for the management of AD, especially for facial lesions.

REFERENCES

1. Dworzak MN, Froschl G, Printz D, et al.: Skin-associated lymphocytes in the peripheral blood of patients with atopic dermatitis: signs of subset expansion and stimulation. *J Allergy Clin Immunol* 1999;103:901-906.
2. Renz H, Jujo K, Bradley KL, et al.: Enhanced IL-4 production and IL-4 receptor expression in atopic dermatitis and their modulation by interferon-gamma. *J Invest Dermatol* 1992;99:403-408.
3. Yamamoto S, Hamasaki Y, Ishii E, et al.: Unbalanced production of interleukin-5 and interleukin-2 in children with atopic dermatitis. *Ann Allergy Asthma Immunol* 1997;78:517-523.
4. Ellison JA, Patel L, Ray DW, et al.: Hypothalamic-pituitary-adrenal function and glucocorticoid sensitivity in atopic dermatitis. *Pediatrics* 2000;105:794-799.
5. Lutgemeier MD, Lubach D: Development and regression of dermal corticosteroid atrophy. 4. Concentration dependence of the skin thinning effect of triamcinolone acetonide. *Derm Beruf Umwelt* 1987;35:55-57.
6. Oikarinen A, Autio P: New aspects of the mechanism of corticosteroid-induced dermal atrophy. *Clin Exp Dermatol* 1991;16:416-419.
7. Serup J: Characterization of contact dermatitis and atopy using bioengineering techniques. A survey. *Acta Derm Venereol Suppl (Stockh)* 1992;177:14-25.
8. Hardie RA, Waring AJ, Barnetson RS: Atrophic skin striae following the use of clobetasol propionate ointment. *Practitioner* 1997;219:376-378.
9. De Rie MA, Meinardi MM, Bos JD: Lack of efficacy of topical cyclosporin A in atopic dermatitis and allergic contact dermatitis. *Acta Derm Venereol* 1991;71:452-454.
10. Bekersky I, Fitzsimmons W, Tanase A, et al.: Nonclinical and early clinical development of tacrolimus ointment for the treatment of atopic dermatitis. *J Am Acad Dermatol* 2001;44(suppl 1):S17-27.
11. Boguniewicz M, Fiedler VC, Raimer S, et al.: A randomized, vehicle-controlled trial of tacrolimus ointment for treatment of atopic dermatitis in children. Pediatric Tacrolimus Study Group. *J Allergy Clin Immunol* 1998;102:637-644.
12. Paller A, Eichenfield LF, Leung DY, et al.: A 12-week study of tacrolimus ointment for the treatment of atopic dermatitis in pediatric patients. *J Am Acad Dermatol* 2001;44(suppl 1):S47-S57.
13. Elidel [prescribing information]. East Hanover, NJ: Novartis Pharmaceuticals Corp.
14. Grassberger M, Baumruker T, Enz A, et al.: A novel anti-inflammatory drug, SDZ ASM 981, for the treatment of skin diseases: *in vitro* pharmacology. *Br J Dermatol* 1991;141:264-273.
15. Zuberbier T, Chong SU, Grunow K, et al.: The ascomycin macrolactam pimecrolimus (Elidel, SDZ ASM 981) is a potent inhibitor of mediator release from human dermal mast cells and peripheral blood basophils. *J Allergy Clin Immunol* 2001;108:275-280.
16. Luger T, van Leent EJM, Graeber M, et al.: SDZ ASM 981: an emerging safe and effective treatment for atopic dermatitis. *Br J Dermatol* 2001;144:788-794.
17. Van Leent EJM, Graber M, Thurston M, et al.: Effectiveness of the ascomycin macrolactam SDZ ASM 981 in the topical treatment of atopic dermatitis. *Arch Dermatol* 1998;134:805-809.
18. Meurer M, Brautigam M: Pimecrolimus (SDZ ASM

- 981) cream reduces the need for corticosteroids in the long-term management of atopic dermatitis in adults [abstract]. Poster no. 108 presented at the 60th AAD, New Orleans, LA, 2002, pp23-27.
19. Wahn U, Molloy S, Graeber M, et al.: SDZ ASM 981 cream 1%: a new approach to long-term management of atopic dermatitis [abstract no. 863]. *J Invest Dermatol* 2001;117:533.
 20. De Prost Y, Wahn U, Bos JD, et al.: Pimecrolimus (SDZ ASM 981) cream reduces the number of flares and the need for topical corticosteroids in children with atopic dermatitis: a 12-month, double-blind, controlled study [abstract]. Poster no. 95 presented at the 60th AAD, New Orleans, LA, 2002, pp23-27.
 21. Lucky A, Marshall K, Bush C, et al.: SDZ ASM 981 cream 1% is effective and safe in children and adolescents with atopic dermatitis [abstract]. *Clin Exp Dermatol* 2001;26:214.
 22. Whalley D, McKenna S, Huels J, et al.: The benefit of pimecrolimus (Elidel, SDZ ASM 981) on quality of life in the treatment of pediatric atopic dermatitis: results of two 6-week randomized double-blind vehicle-controlled clinical trials in the US [abstract]. *J Eur Acad Dermatol Venereol* 15 Suppl. 2001;2:S112.
 23. Boguniewicz M, Eichenfield L, Honig P, et al.: Pimecrolimus (Elidel, SDZ ASM 981) cream 1% is safe in the long-term management of atopic dermatitis [abstract]. *J Eur Acad Dermatol Venereol* 2001;15 Suppl 2:S110.
 24. Kapp A, Bingham A, De Moor A, et al.: Pimecrolimus (Elidel, SDZ ASM 981) cream 1%: a new approach to long-term management of atopic dermatitis in infants 3 to 23 months of age [abstract]. *J Eur Acad Dermatol Venereol* 2001;15 Suppl 2: S111.
 25. Ho V, Halbert A, Takaoka R, et al.: Pimecrolimus (Elidel, SDZ ASM 981) cream 1% is effective and safe in infants aged 3-23 months with atopic dermatitis [abstract]. *J Eur Acad Dermatol Venereol* 2001;15 Suppl 2:S110.
 26. Wahn U, Bos JD, Goodfield M, Caputo R, Papp K, Manjra A, et al.: Flare Reduction in Eczema with Elidel (Children) Multicenter Investigator Study Group. Efficacy and safety of pimecrolimus cream in the long-term management of atopic dermatitis in children. *Pediatrics* 2002;110:e2.
 27. Allen BR, Lakhapaul M, Morris A, Lateo S, Davies T, Scott G, Cardno M, Ebelin ME, Burtin P, Stephenson TJ.: Systemic exposure, tolerability, and efficacy of pimecrolimus cream 1% in atopic dermatitis patients. *Arch Dis Child* 2003;88:969-973.
 28. Kalthoff FS, Chung J, Musser P, Stuetz A: Pimecrolimus does not affect the differentiation, maturation and function of human monocyte-derived dendritic cells, in contrast to corticosteroids. *Clin Exp Immunol* 2003;133:350-359.
 29. Stuetz A, Grassberger M, Meingassner JG: Pimecrolimus (Elidel, SDZ ASM 981)-preclinical pharmacologic profile and skin selectivity. *Semin Cutan Med Surg* 2001;20:233-241.
 30. Meingassner JG, Fahrngruber H, Bavandi A: Pimecrolimus inhibits the elicitation phase but does not suppress the sensitization phase in murine contact hypersensitivity, in contrast to tacrolimus and cyclosporine A. *J Invest Dermatol* 2003; 121:77-80.