

## Two Cases of Tufted Hair Folliculitis

Mi-Yeon Kim, M.D., Hee Chang Choe, M.D., Hyun Jeong Park, M.D.,  
Jun Young Lee, M.D., Baik Kee Cho, M.D.

*Department of Dermatology, St. Mary's Hospital, College of Medicine, The Catholic University of Korea, Seoul, Korea*

Tufted hair folliculitis is a localized, inflammatory and exudative disease of the scalp characterized by a tufted appearance of the scalp hairs emerging from single follicular openings, and may result in permanent and irreversible scarring alopecia.

We report two cases of tufted hair folliculitis in a 53-year-old woman and a 47-year-old man. They had several areas of scarring alopecia with multiple bundles of hairs emerging from single follicular orifices. Histopathologic findings were typical for tufted hair folliculitis. The patients were treated successively with oral antibiotics and with topical application of clindamycin. (*Ann Dermatol* 14(4) 239~242, 2002).

---

*Key Words* : Tufted hair folliculitis

Tufted hair folliculitis is characterized by the appearance of one or more inflammatory and exudating plaque lesions on the scalp that evolve slowly with peripheral extension. They result in scarring alopecia with sclerotic, erythematous, shining skin, from which tufts of 5 to 30 apparently normal hair shafts emerge through dilated follicular openings<sup>1</sup>. Histologically, it is characterized by a superficial folliculitis that involves several follicles opening into a common ostium from which multiple hairs come out<sup>2</sup>.

### CASE REPORT

#### Case 1

A 53-year-old woman presented with several inflammatory, exudating, and crusted lesions at the parietal and occipital scalp for 3 years. Examination showed several areas of scarring alopecia on

the parieto-occipital region of the scalp. Within this area, scattered tufts composed of 7 to 15 hairs emerging from single, widely dilated follicular ostia remained. Pressure on the perifollicular areas produced the discharge of purulent material through the dilated follicular openings. Careful examination of the scalp did not reveal any developmental anomaly of the hair, such as pili multigemini or trichostasis spinulosa. The patient was in generally good health without palpable cervical lymph nodes. Investigations, including routine blood tests and serological test, such as syphilis serology test and antinuclear antibody, were normal or negative. Fungal cultures from the affected area were negative, but bacterial cultures grew *Staphylococcus aureus*. Examination of a skin biopsy specimen showed an inflammatory process in the perifollicular dermis, with neutrophils, lymphocytes, plasma cells, and eosinophils. There was interfollicular fibrosis in the upper dermis, and the hairs merged into a common follicular ostium. Oral antimicrobials (roxithromycin, doxycycline) for 4 weeks, combined with topical clindamycin, led to resolution of the inflammation, but had no effect on the hair tufting.

#### Case 2

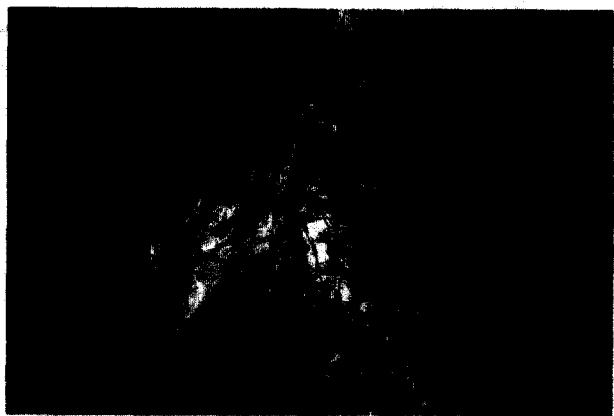A 47-year-old man presented with multiple inflamed, tender, scarred areas of the occipital scalp for

---

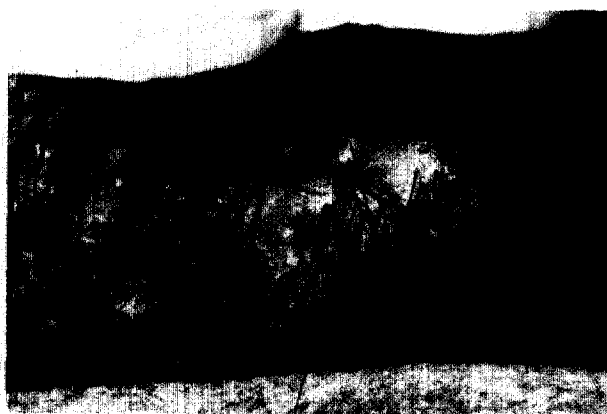
Received April 27, 2002.

Accepted for publication August 22, 2002.


**Reprint request to** : Hyun Jeong Park, M.D., Department of Dermatology, St. Mary's Hospital, College of Medicine, The Catholic University of Korea #62 Youido-dong, Youngdeundpo-gu, Seoul, 150-713, Korea  
Tel. (02)3779-1230, Fax. (02)783-7604  
E-mail. hjpark@cmc.cuk.ac.kr



**Fig. 1.** Case 1. Well-circumscribed erythematous, edematous alopecic patch with bundles of hairs emerging from single follicular openings.



**Fig. 2.** Case 2. Several hair tufts are present within patches of scarring alopecia giving the scalp a "dolly hair" appearance.



**Fig. 3.** Case 1. Convergence of independent hair structures toward a single orifice in epidermis (A) and perifollicular heavy mixed inflammatory infiltrates with fibrosis (B) (H & E,  $\times 40$ ).

several months. He reported suffering from occasional episodes of redness and tenderness of the scalp. He was intermittently treated with folliculitis of the scalp for 3 years. Examination revealed multiple areas of scarring alopecia associated with some perifollicular crusting on the occipital scalp. Within these areas were several tufts of hair, each tuft containing on average 8 to 10 hairs, which appeared to be emerging from a single follicular orifice. He was otherwise well. Investigations, in-

cluding routine blood tests and serological test, as well as mycology and microbiology cultures, were normal or negative. Histology of the affected areas confirmed a cicatricial process but excluded conditions such as lupus erythematosus or lichen planus. He has been treated with topical and systemic antibiotics for over 4 weeks. This treatment produced some improvement, with resolution of suppuration, but mild erythema persisted.

## DISCUSSION

Tufted hair folliculitis is a recurrent, progressive and purulent follicular and perifollicular inflammatory disease characterized by the presence of multiple compound follicles (hair tufts) emerging from an erythematous scalp that leads to the destruction of the follicular units resulting in a scarring alopecia<sup>3</sup>. It occurs in patients of both genders, with a male to female ratio of 2.7:1. In the cases described, patients are usually between the ages of 10 and 68 years, and the lesion is usually located in the parietal and/or occipital areas. Within this area several tufts of 5 to 20 normal-appearing hairs arise out of a single dilated follicular opening. Discrete scaling containing embedded hairs in each tuft may also be observed. Small numbers of follicular pustules and individual follicles in close proximity to each other may also be present. Recurrent exacerbations, consisting of local tenderness, exudation and pruritus appearing without any precipitating factor, may occur over a variable period ranging from weeks to months. During relapses slight pressure on the scalp around involved follicles may produce a purulent discharge at the dilated follicular openings. *Staphylococcus aureus* is usually isolated from the purulent exudation. The condition frequently worsens, with peripheral extension of the inflammation that leads to central area of cicatricial alopecia and new tufts in previously normal scalp areas<sup>3,4,5</sup>.

The cause of tufted hair folliculitis is unknown, but several explanations have been proposed. It is considered by some authors as a variant of folliculitis decalvans<sup>3,6</sup>. Since *Staphylococcus aureus* is almost always isolated in this situation, it may be a recurrent staphylococcal folliculitis with fibrosis in the interfollicular areas and consequent approximation of the follicles, with hairs emerging in tufts<sup>7</sup>. In addition, it has been suggested that tuft formation is due to telogenic hairs being retained around an anagenic follicle, but it has since been demonstrated that most follicles in a tuft are anagenic<sup>8</sup>. It also may be a localized nevroid malformation, with tufts present since birth but becoming apparent only when infection occurs with the destruction of some of the follicles<sup>9</sup>. The compound follicles are more prone to chronic infection by *Staphylococcus aureus*<sup>10</sup>, but this theory does not explain the centrifugal nature of the lesions nor

the appearance of tufts in previously normal scalp areas. Pujol et al<sup>11</sup> suggest that hair tufting may be a nonspecific secondary phenomenon that may occur in several exudative inflammatory diseases of the scalp, including dissecting cellulites of the scalp, folliculitis decalvans, and folliculitis keloidalis. In our second patient, it is likely that the chronic recurrent folliculitis facilitated tufting of hairs.

The most significant fact in the pathology of tufted hair folliculitis is the convergence of several follicles toward a common follicular duct. The lowest portions of the follicles are normal, each with a papilla and independent internal and external root sheaths, which differentiate them from pili multigemini. In the superior and mid dermis, there is an inflammatory infiltrate with neutrophils, eosinophils, lymphocytes, and plasma cells, mostly perifollicular. Rupture of the follicular wall and the presence of hair debris in the macrophage cytoplasm and in multinucleate giant cells have been reported<sup>7,12</sup>. Late lesions display abundant fibroplasias of the dermis surrounding the merged follicles<sup>13</sup>.

The differential diagnosis mainly includes folliculitis decalvans, acne keloidalis nuchae, dissecting cellulites of the scalp, kerion celsi and follicular lichen planus. Folliculitis decalvans shares several clinical, histological and microbiological features with tufted hair folliculitis. But it was suggested that tufted folliculitis should be regarded as a peculiar form of folliculitis decalvans characterized by multiple hair tufts scattered within the patches of scarring alopecia that give the scalp a typical 'dolly hair' appearance. On the basis of clinicohistological study, the presence of keloidal papules and/or plaques in acne keloidalis nuchae and of fluctuant, coalescing nodules composed of dermal and subcutaneous neutrophilic abscesses in dissecting cellulites of the scalp, easily distinguished these diseases from tufted hair folliculitis. Kerion celsi, unlike tufted hair folliculitis, consists of erythematous plaques studded with pustules that are characterized histologically by dense neutrophilic infiltrates around and within follicles that house fungal elements. Follicular lichen planus does not show follicular pustules and is constituted by perifollicular lichenoid infiltrates of lymphocytes. Our cases differed from folliculitis decalvans, acne keloidalis nuchae or dissecting cellulites of the scalp by clini-

cal presentations. And fungal cultures from the affected area were negative. Histology of the affected areas confirmed a cicatricial process but excluded conditions such as lupus erythematosus or lichen planus. So our cases were typical for tufted hair folliculitis.

Antibiotics administered systemically and topically have been the most commonly used treatment. However, complete cures are rare. As a rule, the antibiotics allow reasonable control of the inflammatory signs, but discontinuing their use leads-after a period from weeks to months-to the reappearance of lesions<sup>1</sup>. Isotretinoin<sup>3</sup>, zinc sulfate<sup>3,7</sup>, and rifampin<sup>7</sup> are used without great success. Surgery, while technically feasible, seems to be effective only at an early stage, which is why early diagnosis is essential<sup>9</sup>.

We report two cases of tufted hair folliculitis in a 53-year-old woman and a 47-year-old man, which show typical clinical and histopathological features.

## REFERENCES

1. Fernandes JC, Correia TM, Azevedo F, Mesquita-Guimaraes J: Tufted hair folliculitis after scalp injury. *Cutis* 67:243-245, 2001
2. Annessi G: Tufted folliculitis of the scalp: a distinctive clinicohistological variant of folliculitis decalvans. *Br J Dermatol* 138:799-805, 1998
3. Pujol RM, Matias-Guiu X, Garcia-Patos V, de Moragas JM: Tufted-hair folliculitis. *Clin Exp Dermatol* 16:199-201, 1991
4. Grabczynska SA, Holden CA: Tufted folliculitis in a 10-year-old child. *Br J Dermatol* 140:975-976, 1999
5. al-Jawamis FM, Khalifeh L, Todd DJ: Tufted hair folliculitis in Jordanian patients. *Int J Dermatol* 35:280-281, 1996
6. Powell JJ, Dawber RP, Gatter K: Folliculitis decalvans including tufted folliculitis: clinical, histological and therapeutic findings. *Br J Dermatol* 140:328-333, 1999
7. Luelmo-Aguilar J, Gonzalez-Castro U, Castells-Rodellas A: Tufted hair folliculitis. A study of four cases. *Br J Dermatol* 128:454-457, 1993
8. Tagami H: Numerous multiple hairs. *Arch Dermatol* 102:309-312, 1970
9. Tong AK, Baden HP: Tufted hair folliculitis. *J Am Acad Dermatol* 21:1096-1099, 1989
10. Loewenthal LJA: "compound" and grouped hairs of the human scalp: their connection with follicular infections. *J Invest Dermatol* 8:263-273, 1947
11. Pujol RM, Garcia-Patos V, Ravella-Mateu A, Casanova JM, de Moragas JM: Tufted hair folliculitis: a specific disease? *Br J Dermatol* 130:259-260, 1994
12. Dalziel KL, Telfer NR, Wilson CL, Dawber RP: Tufted folliculitis. A specific bacterial disease? *Am J Dermatopathol* 12:37-41, 1990
13. Petronic-Rosic V, Krunic A, Mijuskovic M, Vesic S: Tufted hair folliculitis: a pattern of scarring alopecia? *J Am Acad Dermatol* 41:112-114, 1999