

# An Unusual Case of Transepidermal Elimination of Calcinosis Cutis

Soo Il Chun, M.D., Sung Ku Ahn, M.D.

*Department of Dermatology, Yonsei University College of Medicine, Seoul, Korea*

**A 45 year-old Korean woman presented with multiple pruritic umbilicated papules on both ankles of 3 months duration.**

**Histopathologic findings showed calcium deposits in the upper dermis and the transepidermal elimination of calcium. This is a very rare presentation of calcinosis cutis. (Ann Dermatol 1:80-82, 1989)**

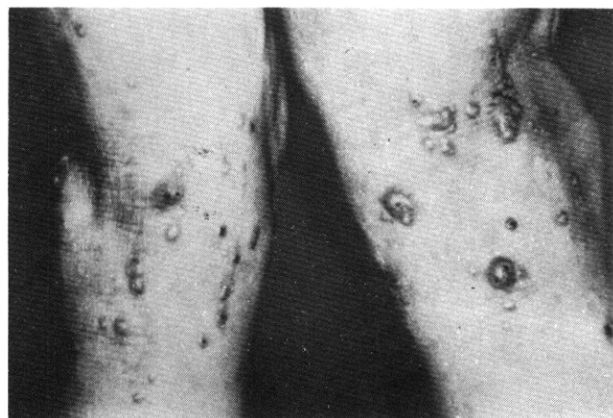
*Key Words:* Calcinosis cutis, Transepidermal elimination

Four forms of calcinosis cutis exist; metastatic, idiopathic, and dystrophic calcinosis and subepidermal calcified nodules.<sup>1</sup> In calcinosis cutis of the nodular type or in calcinosis cutis secondary to contact with calcium chloride, the process of transepidermal elimination of calcium salts can be observed.<sup>2</sup>

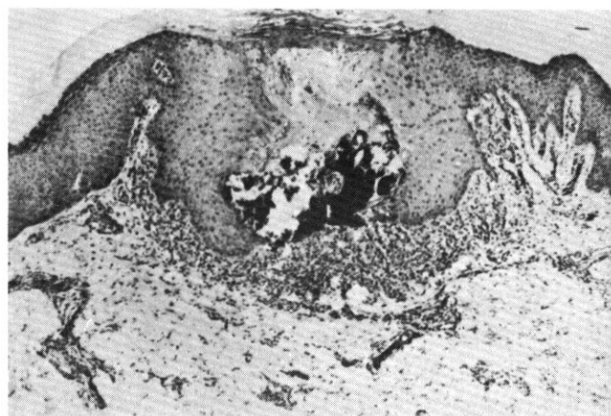
We describe herein a Korean woman having calcinosis cutis of unknown etiology. The lesions showed transepidermal elimination microscopically.

## REPORT OF A CASE

A 45 year-old housewife was first seen on May 6, 1981, because of a pruritic rash involving the anterior aspect of both ankles. The skin eruption had appeared 3 months previously and consisted of erythematous papules with a mild itching sensation. Some topical ointments were applied to the lesion without any effect. Because of increasing severity of itch, the patient received acupuncture treatments. However the skin lesions continued to increase in size and number, and the severe itching sensation persisted. There was no family history of a similar disorder. She has been living in the village where coal was mined. The physical examination was negative except for the rash. The skin lesions consisted of dis-



**Fig. 1.** Erythematous and brown colored papules and umbilicated nodules demonstrating the Koebner phenomenon on the anterior aspect of both ankle.

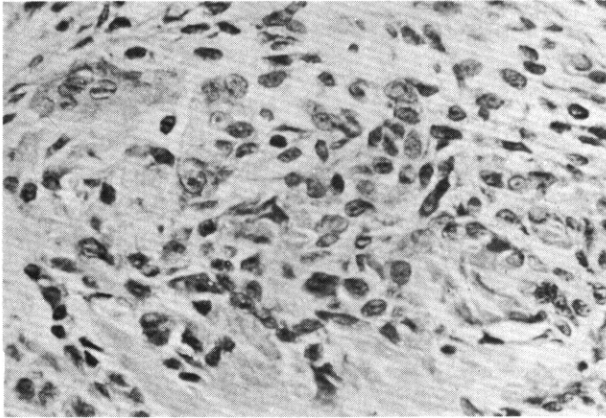


**Fig. 2.** A cup-shaped epidermal depression containing a thick plug of calcifying material and necrotic debris from the umbilicated lesion (H & E stain, ×40).

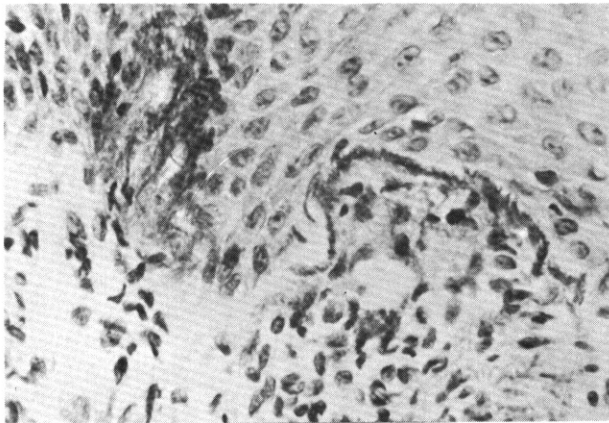
Received April 28, 1989

Accepted for publication June 27, 1989

**Reprint request to:** Soo Il Chun, M.D., Department of Dermatology, Yonsei University College of Medicine C.P.O. Box 8044, Seoul, Korea



**Fig. 3.** Dense infiltration of histiocytes and occasional multinucleated giant cells (H & E stain,  $\times 400$ ).



**Fig. 4.** Basophilic, calcified, degenerating filaments along the dermo-epidermal junction and amorphous basophilic, calcified, degenerating material in the thickened papillary dermis (H & E stain,  $\times 400$ ).

crete, pinhead to peanut sized, erythematous to brown colored papules and umbilicated nodules on the anterior aspect of both ankles. Some papules were arranged in a linear fashion, suggestive of the Koebner phenomenon (Fig. 1). The skin lesions were biopsied for histopathologic examination. The section from a well developed umbilicated lesion showed a cup-shaped epidermal depression containing a thick plug composed of calcified materials and necrotic debris. The wall of the crater was edematous and acanthotic (Fig. 2). The upper dermis showed focal calcium deposits and around the deposits, dense infiltration of histiocytes and occasional multinucleated giant cells were seen (Fig. 3). Many of the collagen bundles in the upper dermis showed basophilic calcifying degeneration and were arranged horizontally or longitudinally. Histopathological examination of other sections from the papules showed basophilic

filaments arranged along the dermo-epidermal junction and amorphous basophilic material in the thickened papillary dermis (Fig. 4), which stained black with the von Kossa method. Some degenerating collagen bundles were extruded through the perforated channel along with many calcium deposits.

All the above changes were characteristic of the transepidermal elimination of calcium salts. Because of the persistent itching sensation, electrocautery was performed and there was no evidence of recurrence of the treated lesions during the following 7 months.

## DISCUSSION

There have been several reports of calcinosis cutis resulting from percutaneous penetration and deposition of calcium.<sup>3</sup> Numerous, 1 to 2 mm sized, light-brown, hard, follicular papules had developed on the dorsa of the hands and fingers of an oil field worker.<sup>4</sup> Histopathologic examination demonstrated the deposition of calcium in the upper dermis with no evidence of transepidermal elimination of the calcium. Yellow-white colored papules and plaques on the antecubital fossae of a farmer using a fertilizer containing calcium nitrate showed microscopic findings similar to have been described.<sup>4</sup> White, small, papular lesions have developed in abrasion wounds contaminated with a solution of calcium chloride.<sup>5</sup> Papules and plaques of calcinosis cutis developed after external contact with dry calcium chloride.<sup>6,8</sup> Histopathologic examination showed the transepidermal elimination of calcium and epidermal hyperplasia.

Calcinosis cutis has also occurred on the scalp following prolonged contact with electroencepharogram electrode paste containing calcium chloride.<sup>9</sup> Microscopic examination showed calcium deposits and transepidermal elimination of calcium.

In addition the minor trauma caused by bending water pipes resulted in a form of calcinosis cutis of the skin below the knee known as "plumber's knee".<sup>10</sup>

Our patient had keratotic papules with umbilication accompanied by severe itching. External trauma from scratching or from the acupuncture therapy may have induced the Koebner's phenomena in this patient. In an attempt to relieve the pruritus, acupuncture was done without any effect. These pruritic keratotic papules and Koebner's phenomena have not

been reported in the previous discussions of calcinosis cutis resulting from percutaneous penetration, minor trauma or of dystrophic origin.

Transepidermal elimination of calcium has been reported in calcinosis cutis.<sup>11</sup> The epidermis has been reported to show areas of pseudoepitheliomatous hyperplasia engulfing masses of calcified material and occasionally forming channels through which particles of calcified material are transported to the surface.

Examination of the umbilicated papules in this case showed features transepidermal elimination of calcium and epidermal hyperplasia as noted in the previous reports. Clinical observation of these lesions suggests that the elimination process will continue until no more calcium impregnated connective tissue exists in the corium. Unfortunately we could not check the serum level of calcium and phosphate because the patient did not return for follow-up.

We do not know the exact cause of calcium deposits in this patient. Exposure to calcium salts may be one possibility as she has been living in a coal mining village. Another predisposing factor for the formation of calcium deposits with transepidermal elimination may have been the acupuncture treatment.

## REFERENCES

1. Lever WF, Schaumburg-Lever GS: *Histopathology of the Skin*. 6th ed, J B Lippincott Co, Philadelphia, 1983, pp 420-422.
2. Mehregan AH: *Perforating dermatosis: A clinicopathologic review*. *Int J Dermatol* 16:19-27, 1977.
3. Wheeland RG, Roundtree JM: *Calcinosis cutis resulting from percutaneous penetration and deposition of calcium*. *J Am Acad Dermatol* 12:172-175, 1985.
4. Christensen OB: *An exogenous variety of pseudoxanthoma elasticum in old farmers*. *Acta Derm Venerol (Stockh)* 58:319-321, 1978.
5. Sneddon IB, Archibald RM: *Traumatic calcinosis of the skin*. *Br J Dermatol* 70:211-214, 1985.
6. Zackheim HS, Pinkus H: *Calcium chloride necrosis of the skin*. *Arch Dermatol* 76:244-246, 1957.
7. Clendenning WE, Auerbach R: *Traumatic calcium deposition in skin*. *Arch Dermatol* 89:361-363, 1964.
8. Schoenfeld RJ, Grekin JN, Mehregan A: *Calcium deposition in the skin*. *Neurology* 15:477-480, 1965.
9. Wiley III HE, Eaglstein WE: *Calcinosis cutis in children following electroencephalography*. *JAMA* 242:455-456, 1979.
10. Ellis IO, Foster MC, Womack C: *Plumber's knee: Calcinosis cutis after repeated minor trauma in a plumber*. *Br Med J* 288:1723, 1984.
11. Mehregan AM: *Transepidermal elimination*. *Curr Probl Derm* 3:124-147, 1970.