

Clinical Efficacy and Tolerability of Terbinafine 1% Cream in Patients with Pityriasis Versicolor

Ho Sun Jang, M.D., Hyun Tae Lee, M.D., Cheon Gi Kim, M.D.,
Kyung Sool Kwon, M.D., Tae Ahn Chung, M.D.

Department of Dermatology, College of Medicine, Pusan National University
Pusan, Korea

Background : There are a number of effective topical therapies for treating pityriasis versicolor, but they are associated with a relatively high recurrence. Topical application of terbinafine 1% cream has been shown to be a more effective short-duration therapy for dermatomycoses of the skin than other topical agents.

Objective : This study was performed to evaluate the efficacy and tolerability of 2-week treatment of pityriasis versicolor with terbinafine 1% cream (Lamisil®).

Methods : Thirty patients of both sexes with mycologically proven pityriasis versicolor were instructed to apply terbinafine 1% cream to the affected area twice daily for 2 weeks. The therapeutic response was evaluated after each week of treatment and at the follow-up visits 2 and 6 weeks after the therapy had ended.

Results : 1. Clinical signs and symptoms resolved rapidly after treatment and continued to resolve during the follow-up period.

2. Negative conversion rates of direct microscopy and culture at week 2 were 90.0% and 70.0%, respectively, and at week 8, 93.3% and 90.0%, respectively. Mycological cure rates were 66.7% at week 2 and 90.0% at week 8.

3. The overall efficacy assessed above moderate at week 8 was 96.7% by the investigator and 93.3% by the patient.

4. The overall tolerability assessed above good at week 8 was 96.7% by the investigator and 90.0% by the patient.

5. Adverse events were reported in 2 patients with itching and burning sensation, but in both symptoms were mild and short-term.

Conclusion : This study shows that a 2-week treatment with terbinafine 1% cream is very effective, safe, and tolerable therapy of pityriasis versicolor.

(Ann Dermatol 8:(3)169~176, 1996).

Key Words : Pityriasis versicolor, Terbinafine

Pityriasis versicolor is a common superficial chronic fungal infection of the skin caused by

Received January 29, 1996.

Accepted for publication March 27, 1996.

Reprint request to : Ho Sun Jang, M.D., Department of Dermatology, College of Medicine, Pusan National University Pusan, Korea

This paper was presented at the 47th Annual Meeting of the Korean Dermatological Association on October 13, 1995.

Malassezia furfur. Lesions are slightly scaly, papular, and nummular or they may be confluent. Color can vary from brown to red, and hypopigmented patches may also be present^{1,2}. There are a number of effective topical therapies for treating pityriasis versicolor, but they are associated with a relatively high recurrence³. Therefore, there is a need for a new, stronger and more effective antifungal agent against *Malassezia furfur*.

Terbinafine (Lamisil) is a synthetic antimycotic

agent from a new class of compounds, the allylamines⁴. It potentially inhibits ergosterol biosynthesis, an essential component of fungal cell membranes, at the step of squalene epoxidation. A lack of ergosterol can interfere with the integrity and growth of the fungal cell wall. Squalene epoxidase inhibition also causes intracellular squalene accumulation that may cause fungicidal activity^{5,6}.

Terbinafine 1% cream has been shown to be an effective treatment for various forms of dermatomycoses, cutaneous candidiasis, and pityriasis versicolor, and has led to mycological cure rates of 73-100% in the various indications⁷⁻⁹. In a single blind randomized trial comparing terbinafine 1% cream with bifonazole 1% cream in the treatment of pityriasis versicolor for a maximum of 4 weeks it was observed that in patients treated with terbinafine a higher mycological cure rate and more rapid clinical response were demonstrated than in those treated with bifonazole¹⁰. More recent placebo-controlled studies of two-week or one-week treatment of tinea pedis, tinea corporis and tinea cruris have shown terbinafine to be highly effective when used for this short duration¹¹⁻¹⁷. Therefore, in treating pityriasis versicolor, terbinafine 1% cream may be used more effectively as these short-duration therapies than other topical agents, but there have been few reports about the treatment of pityriasis versicolor with terbinafine 1% cream.

We report the results of the efficacy and tolerability of terbinafine 1% cream in patients with pityriasis versicolor.

MATERIAL AND METHODS

Patients

Thirty patients of both sexes aged 15 years or over with a diagnosis of pityriasis versicolor were included in the study. Diagnosis was confirmed by positive KOH/Parker ink[®] preparation and mycological culture. Pregnant or breast-feeding women, or women of child-bearing age not using any means of contraception, and patients who had received systemic antimycotic therapy in the previous 6 weeks or topical antimycotic therapy within the previous 7 days were excluded.

Methods

1. Application of drug

Patients were instructed to apply terbinafine 1% cream to the affected area twice daily for 2 weeks and thereafter, were followed up for a further 6 weeks. If multiple lesions were present, the target lesion was used to assess efficacy. No other topical treatment such as cream, lotion or ointment was allowed during the study period.

2. Clinical and mycological evaluation

The mycological response, signs and symptoms of the target lesion were evaluated after each week of treatment and at the follow-up visits 2 and 6 weeks after therapy had ended. Prior to treatment, and at each visit, skin scrapings were obtained for direct microscopy in KOH/Parker ink[®] preparation and culture on Sabouraud dextrose agar overlaid with olive oil. Patients were classified as mycologically cured if they were negative on microscopy and culture. The clinical response to treatment was evaluated at each visit on the basis of signs and symptoms of infection (scaling, pruritus, hyperpigmentation, erythema), scored on the following scale: 0, absent; 1, mild; 2, moderate; 3, severe; to give a clinical score (maximum score of 12).

3. Assessment of overall efficacy and tolerability

At the end of the drug application and follow-up period at week 2 and week 8, both the investigator and patient assessed and compared the overall efficacy and tolerability of the drug with the following scale: 1, very good; 2, good; 3, moderate; 4, poor; 5, none.

4. Assessment of adverse events

At each visit, any adverse events occurring during the study period were recorded through the history taking and physical examination.

5. Statistical analysis

Result were expressed as mean \pm SD and the differences was assessed by paired t test.

RESULTS

Age and sex distribution of patients (Table 1)

The sex ratio of patients was 5:1 (25 male, 5 fe-

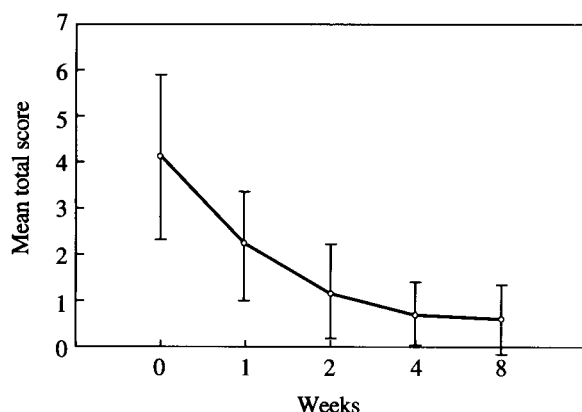
Table 1. Age and sex distribution of patients

Age(Year)	Male	Female	Total(%)
15 ~ 19	5	0	5(16.7)
20 ~ 29	11	0	11(36.7)
30 ~ 39	6	3	9(30.0)
40 ~ 50	2	1	3(10.0)
> 50	1	1	2(6.6)
Total	25(83.3)	5(16.7)	30(100.0)

Table 2. Previous therapeutic modalities

Treatment modality	Number(%)
Oral antifungal agents	*2(6.7)
Topical antifungal agents	3(10.0)
Corticosteroid	*2(6.7)
Unknown	10(33.3)
No treatment	15(50.0)
Total	30(100.0)

* overlap

**Fig. 1.** Mean total score of clinical signs and symptoms in patients with pityriasis versicolor ($p < 0.001$ vs pretreatment group)

male) and the age distribution varied from 15 - 54 years, with the age group of 20 - 39 years being the highest percentage(66.7%).

Usage of other drugs before the treatment (Table 2)

Fifteen patients had had no previous treatment for pityriasis versicolor. Three patients had used topical antifungal agents and two patients had used oral antifungal agents and corticosteroids. Ten patients had had treatments but the exact treatment modalities were not known.

Clinical efficacy

The mean total scores of clinical signs and symptoms before treatment and at the end of treatment were 4.1 ± 1.7 and 1.2 ± 1.1 , respectively. The decrease of score was statistically significant ($p < 0.001$ vs pretreatment group, paired *t* test). During the follow-up period, the mean total scores at week 4 and 8 were reduced to 0.7 ± 0.6 and 0.6 ± 0.7 , respectively (Fig. 1). The clinical

signs and symptoms resolved rapidly after treatment and continued to resolve during the follow-up period (Fig. 2). Hyperpigmentation, the most common sign of all the clinical parameters, was observed in 28(93.3%) patients and disappeared in 15(53.6%) patients at the end of the follow-up period. Hypopigmentation was observed in 10 (33.3%) patients and persisted in 7(70%) patients. It was not included in the assessment of clinical efficacy because of its persistence in spite of the mycological cure. Scaling, the most rapidly improved clinical sign, was observed in 25(83.3%) patients and disappeared in all(100%) patients.

Mycological efficacy

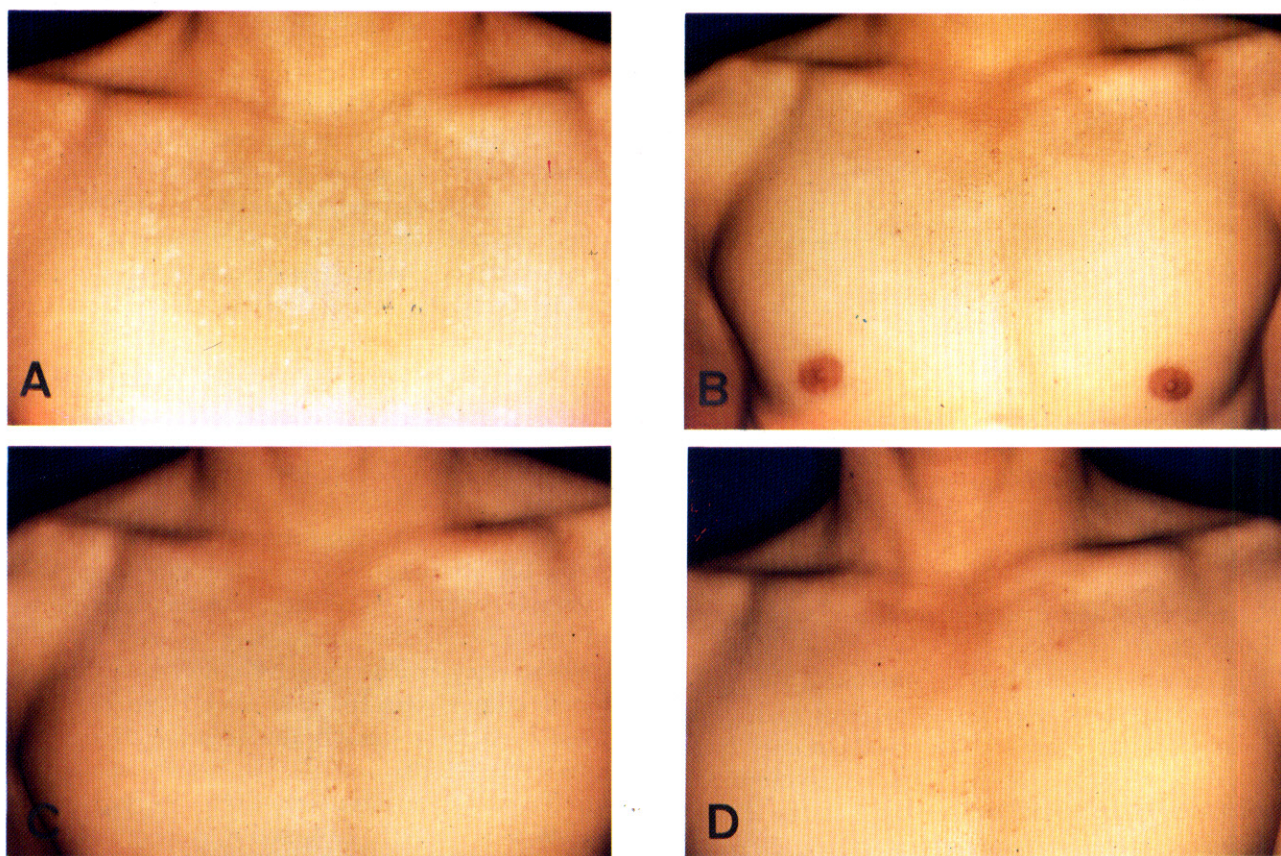
At week 1 and 2, the observed negative conversion rates of KOH/Parker ink® preparation were 36.7% and 90.0%, respectively. Although there was a 100.0% negative conversion rate at week 4, the final negative conversion rate was determined to be 93.3% because there were recurrences in 2 cases at week 8. The negative conversion rates of fungus culture were 26.7% at week 1 and 70.0% at week 2. At week 4 and 8, the negative conversion rates were 86.7% and 90.0%, respectively. The mycological cure rates were 20%, 66.7%, 86.7% and 90% at week 1, 2, 4, and 8, respectively (Fig. 3).

Overall efficacy and tolerability of the treatment

The mean score for overall efficacy at the end of treatment assessed by the investigator and the patient was 2.03 ± 0.78 (moderate to good) and at the end of follow-up period, 1.53 ± 0.78 and 1.67 ± 0.86 (good to very good), respectively. There was no statistical difference between the investigator and the patient ($p < 0.05$). Overall efficacy as-

Table 3. Overall assessment of efficacy and tolerability at week 8 by the investigator and the patient

Assessment	Efficacy(%)		Tolerability(%)	
	Investigator	Patient	Investigator	Patient
Very good	14(46.7)	11(36.7)	16(53.3)	12(40.0)
Good	12(40.0)	13(43.3)	13(43.4)	15(50.0)
Moderate	3(10.0)	4(13.3)	1(3.3)	3(10.0)
Poor	1(3.3)	2(6.7)	0(0.0)	0(0.0)
None	0(0.0)	0(0.0)	0(0.0)	0(0.0)
Total	30(100.0)	30(100.0)	30(100.0)	30(100.0)

**Fig. 2.** Pityriasis versicolor. A, before terbinafine 1% cream treatment; B, after 2 weeks(end of treatment); C, after 4 weeks; D, after 8 weeks (end of follow-up).

essed better than moderate was 96.7% by the investigator and 93.3% by the patient(Fig. 4, Table 3).

The mean score for overall tolerability at the end of the treatment assessed by the investigator and the patient was 1.83 ± 0.74 and 1.77 ± 0.73 (good to very good), respectively and at the end of follow-up period, 1.47 ± 0.63 and $1.57 \pm$

0.61 (good to very good), respectively. There was no statistical difference between the investigator and the patient($p < 0.05$). Overall tolerability assessed better than good was 96.7% by the investigator and 90.0% by the patient(Fig. 5, Table 3).

Adverse events (Table 4)

Of the 30 patients, 2 patients reported adverse

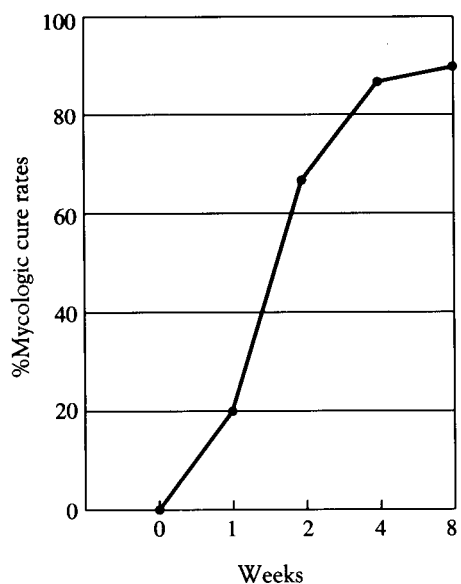


Fig. 3. Mycological cure rate with terbinafine 1% cream treatment.

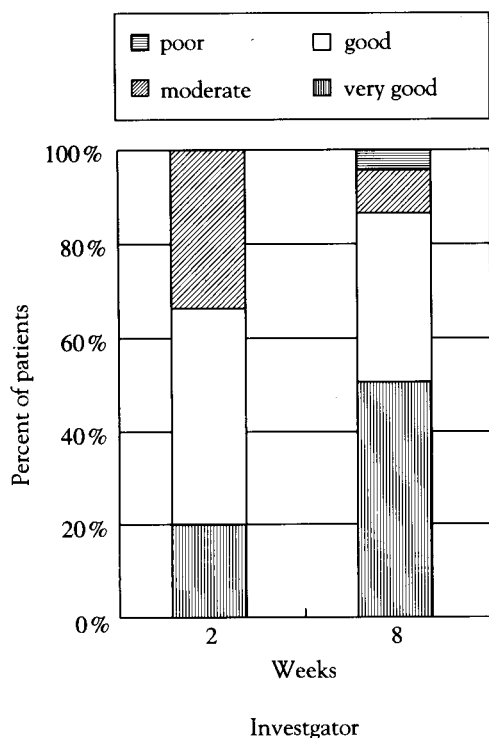


Table 4. Adverse events reported by patient

Adverse events	Number(%)
Itching sensation	1(3.3)
Burning sensation	1(3.3)
Total	2/30(6.6)

DISCUSSION

There are a number of effective topical therapies for treating pityriasis versicolor such as selenium sulfide, zinc pyrithione, sodium thiosulfate, salicylic acid, propylene glycol, haloprogin, ciclopirox olamine, several imidazoles, but each has certain disadvantages. Some require regular applications, some are cosmetically objectionable, and others have an unpleasant odor^{2,6,18}. Also, the treatment must be applied two or three times daily for up to 4 weeks, and the length of time required to obtain a cure is probably due to the primarily fungistatic action of many of these antifungals^{19,20}. According to Faergemann and Fredriksson³, these topical therapies are associated with a relatively

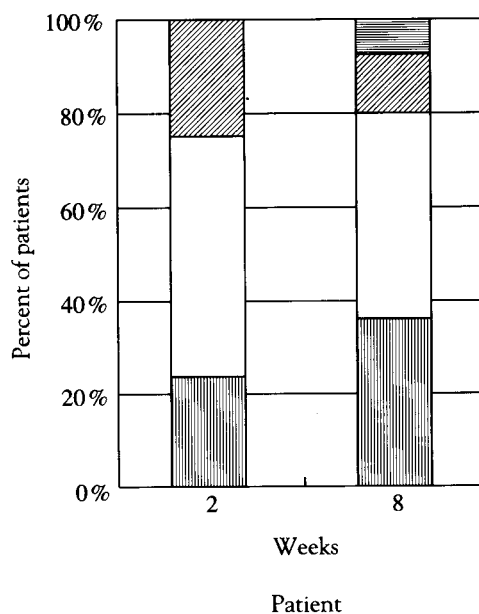


Fig. 4. Assessment of overall efficacy of terbinafine 1% cream treatment at week 2 and 8

events. Although one reported an itching sensation and the other reported burning sensation, both symptoms were mild and short-lived.

high recurrence rate of 60 to 80%.

Terbinafine, a newly developed antifungal agent, has already proved very effective in treating der-

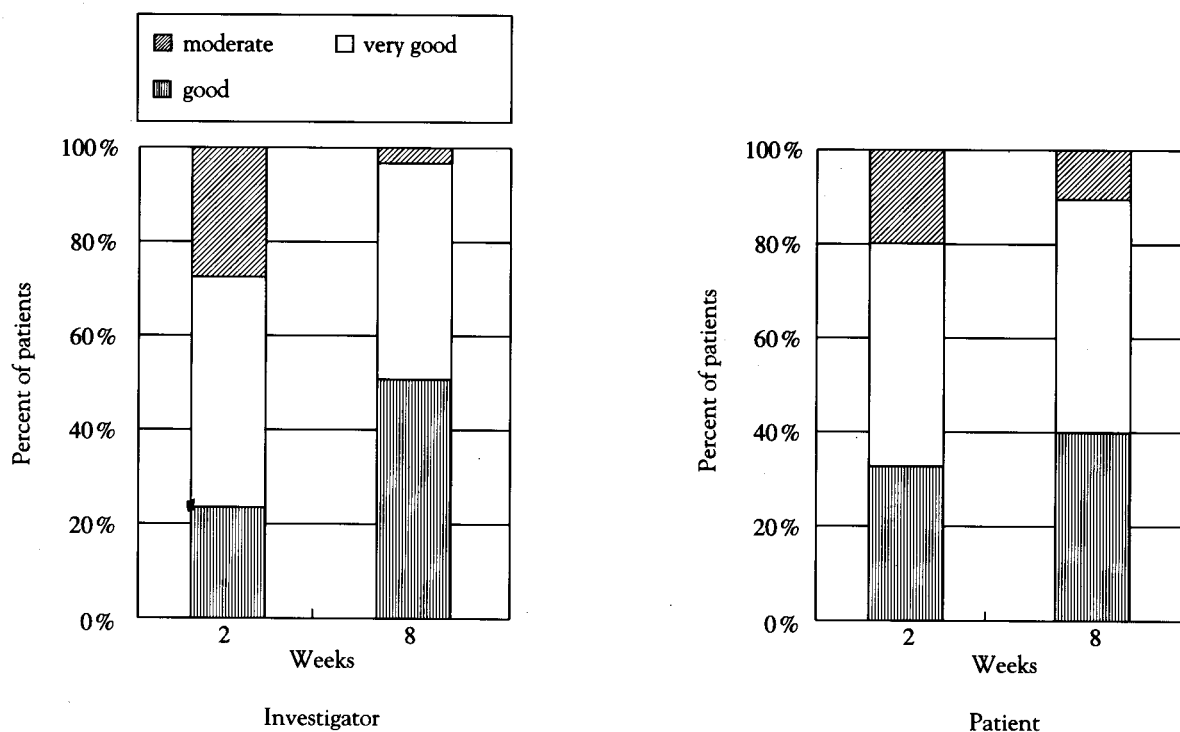


Fig. 5. Assessment of overall tolerability of terbinafine 1% cream treatment at week 2 and 8

matomycoses such as tinea pedis, onychomycosis, tinea cruris and tinea corporis, candidiasis, and sporotrichosis^{7-17,23,24}. Terbinafine has a primary fungicidal action in vitro against most fungal pathogens. Its mechanism of fungicidal action is associated with the inhibition of squalene epoxidase, a key enzyme in the biosynthesis of ergosterol, and causes the following results: first, it inhibits a ergosterol biosynthesis, an essential component of fungal cell membranes, thereby resulting in fungistatic effect in which membrane function and cell growth are suppressed; second, it causes an accumulation of squalene, thereby resulting in a fungicidal effect which causes the weakening of cell membrane, release of lytic enzymes, and eventual cell death^{5,6}. Oral administration of terbinafine is known to be ineffective in treating pityriasis versicolor, possibly because of the failure to reach fungicidal concentrations for *Malassezia furfur* in the stratum corneum, but this disorder responds to the topical application of terbinafine^{9,18,25}. Recently, Sansom et al²⁶ reported that the total *Malassezia furfur* population on normal human skin were not reduced significantly during oral treatment with terbinafine but reductions in the total *Malassezia furfur* population to

the order of 40-fold were observed after 2 weeks topical application of terbinafine. When terbinafine is applied topically it rapidly penetrates the stratum corneum and also enters into the deepest parts of the hair follicle, thus providing effective drug concentration at sites where residual fungi often exist and from which recurrence of infection may occur^{8,25}. The study carried out by Hill et al²⁷ demonstrated that even after a single application, fungicidal levels of terbinafine were reached throughout the stratum corneum and these fungicidal levels were maintained for at least 48 hours after a single application. In those areas which had been treated once daily for 7 days, drug levels exceeding fungicidal concentrations for the common causative organisms of superficial dermatomycoses were detected even 7 days after the cessation of therapy. This information suggests that short treatment courses in dermatomycoses are possible, with the potential for a very low relapse rate, and a few reports on this possibility (one- or two-week treatment of dermatomycoses) have been published in the literatures¹¹⁻¹⁷. In a study of the use of terbinafine orally for the treatment of dermatomycoses⁹, the low rate of relapse of infection was observed after the cure of chronic der-

matophyte infections. Patients who received other antifungal drugs had many more relapses (40-50%) than those receiving terbinafine (6-10%) at long-term follow-up (6-15 months) and the fungicidal action of terbinafine may contribute to this difference. Therefore, short-duration therapy with terbinafine 1% cream in pityriasis versicolor can be tried and the possibility for a very low relapse rate may be expected.

Kagawa²⁵ reported that 88% of pityriasis versicolor patients became mycologically negative and 90% of patients were globally effective in terms of clinical and mycological response when they were treated with terbinafine 1% cream twice daily for 2 weeks. In a comparative study of terbinafine 1% cream vs bifonazole 1% cream for the treatment of patients with pityriasis versicolor, mycological cure rates after 3 weeks of treatment were 70% for terbinafine and 20% for bifonazole patients, and mycological and clinical cure rates at the end of the study (4 weeks) were 100% for terbinafine and 95% for bifonazole patients¹⁰. These results were similar to our mycological cure rates at week 2 (66.7%) and week 4 (86.7%), and the overall efficacy assessed by the investigator at the end of study (96.7%). Thus, a 2-week course of terbinafine was sufficient to treat pityriasis versicolor. With other available topical agents (20% sodium thiosulfate, ketoconazole, sulconazole, oxiconazole, cloconazole), it takes 3 or 4 weeks of treatment to achieve similar results^{20,22}. Also, in our study, the mycological cure rates and mean total score of clinical signs and symptoms at the end of the 6 weeks follow-up were better than at the end of therapy. This may indicate progressive healing after the end of therapy due to the fungicidal drug action and the maintenance of an adequate drug concentration in the skin. Therefore, terbinafine appears to have a therapeutic advantage over slower acting or less effective antifungal agents in terms of convenience and ultimate clinical outcome. The previous two studies had an inadequate or no follow-up period after treatment and our 6 weeks follow-up period was also insufficient. Although the clinical efficacy of topical terbinafine for treating pityriasis versicolor in these studies was thought better than other drugs, longer follow-up studies are needed to verify whether this efficacy might also result in a reduced relapse rate of pityriasis versicolor.

After topical application, less than 5% of terbinafine is absorbed into the systemic circulation, and there is no long-term systemic accumulation of the drug or its metabolites²⁸. When applied for 1 to 4 weeks, side effects consisting of local burning, pruritus, dryness, and erythema occur in approximately 1 to 2% of patients^{7,8,18}. In our study, 2 out of the 30 patients reported side effects of an itching and a burning sensation, but both symptoms were mild and short-term, and disappeared without specific treatment.

Topical antifungal therapy is an effective and well-tolerated method for treating pityriasis versicolor. Although high cure rates can be achieved with topical agents, the number of applications, the duration of treatment, and the common recurrence after treatment often lead to poor compliance and a less than optimal cure rate¹⁵. Therefore, the 2 weeks treatment with terbinafine 1% cream, with its known fungicidal activity, the early appearance of a negative mycological study, and the better clinical efficacy than other topical agents in dermatomycoses, make it another effective therapeutic regimen in treating pityriasis versicolor. Further studies exploring the possibility of a once or twice daily treatment of much shorter duration combined with a longer follow up period need to be conducted.

Acknowledgements

The authors wish to thank Dr. Eul-Hee Han, Dr. Hae-Soo Mok, Dr. Jin-Kwon Kim, Dr. Tae-Kyung Lee, Dr. Hyung-Geun Park and Dr. Myung-Ki Hyun for helpful patients referral.

REFERENCES

1. Ray RJ, Roberts SOB, Mackenzie DWR: Pityriasis versicolor. In Champion RH, Burton JL, Ebling FJG (eds): Textbook of Dermatology. 5th ed, Blackwell Scientific Publications, Oxford, 1992, pp1176-1178.
2. Dante B, Paul HJ, Lexie N: Tinea versicolor: Epidemiologic, clinical, and therapeutic aspects. *J Am Acad Dermatol* 25:300-305, 1991.
3. Faergemann J, Fredriksson T: Tinea versicolor: some new aspects on etiology, pathogenesis, and treatment. *Int J Dermatol* 21:8-22, 1982.
4. Petranyi G, Ryder NS, Stutz A: Allyamine derivatives: new class of synthetic antifungal agents in-

- hibiting fungal squalene epoxidase. *Science* 224: 1239-1241, 1984.
5. Ryder NS. Terbinafine: mode of action and properties of the squalene epoxidase inhibition. *Br J Dermatol* 126(suppl. 39):2-7, 1992.
6. Gupta AK, Sauder DN, Shear NH: Antifungal agents: an overview. part II. *J Am Acad Dermatol* 30:911-933, 1994.
7. Kagawa S: Clinical efficacy of terbinafine in 629 Japanese patients with dermatomycosis. *Clin Exp Dermatol* 14:114-115, 1989.
8. Jones TC: Treatment of dermatomycoses with topically applied allyamines: naftifine and terbinafine. *J Dermatol Treat* 1(suppl. 2):29-32, 1990.
9. Villars V, Jones TC. Clinical efficacy and tolerability of terbinafine(Lamisil®)-A new topical and systemic fungicidal drug for treatment of dermatomycoses. *Clin Exp Dermatol* 14:124-127, 1989.
10. Aste N, Pau M, Pinna L: Clinical efficacy and tolerability of terbinafine in patients with pityriasis versicolor. *Mycoses* 34:353-357, 1991.
11. Evans EGV, Shah JM, Joshipura RC: One-week treatment of tinea corporis and tinea cruris with terbinafine(Lamisil®) 1% cream: a placebo-controlled study. *J Dermatol Treat* 3:181-184, 1992.
12. Evans EGV, James IGV, Joshipura RC: Two-week treatment of tinea pedis with terbinafine(Lamisil®) 1% cream: a placebo-controlled study. *J Dermatol Treat* 2:95-97, 1991.
13. Berman B, Ellis C, Leyden J et al: Efficacy of a one-week twice-daily regimen of terbinafine 1% cream in the treatment of interdigital tinea pedis. *J Am Acad Dermatol* 26:956-960, 1992.
14. Savin R, Atton AV, Bergstresser PR et al: Efficacy of terbinafine 1% cream in the treatment of moccasin-type tinea pedis: Results of placebo-controlled multicenter trials. *J Am Acad Dermatol* 30: 663-667, 1994.
15. Evans EGV, Seaman RAJ, James IGV: Short-duration therapy with terbinafine 1% cream in dermatophyte skin infections. *Br J Dermatol* 130:83-87, 1994.
16. Evans EGV: A comparison of terbinafine(Lamisil®) 1% cream given for one week with clotrimazole (Canesten®) 1% cream given for four weeks, in the treatment of tinea pedis. *Br J Dermatol* 130(suppl. 43):12-14, 1994.
17. Zaia N: The efficacy of 1% terbinafine cream in cutaneous candidiasis and tinea corporis/cruris once a day applications for one week (a double-blind study comparing active cream to vehicle cream). In: *Clinical Dermatology in the Year 2000*. Cited from reference 25
18. Silva-lizma E: Tinea versicolor. *Int J Dermatol* 34:611-617, 1995.
19. Sud IJ, Feingold DS: Mechanisms of action of the antimycotic imidazoles. *J Invest Dermatol* 76:438-441, 1981.
20. Kim JH, Kim JB: Clinical study and therapeutic experience in tinea versicolor(3). *Kor J Dermatol* 66:415-418, 1995.
21. Kim JH, Jun KM, Ro YS, Kim JH: Clinical study and therapeutic experience in tinea versicolor(2). *J Korean Med Assoc* 34:875-880, 1991.
22. Jegosothy BV, Pakes GE: Oxiconazole nitrate: pharmacology, efficacy, and safety of a new imidazole antifungal agent. *Clin Ther* 13:126-141, 1991.
23. Lee KH, Chun SI, Cho BK et al: Efficacy of oral terbinafine in the treatment of onychomycosis. *Kor J Dermatol* 31:567-580, 1993.
24. Hull PR, Vismer HF: Treatment of cutaneous sporotrichosis with terbinafine. *Br J Dermatol* 126 (suppl. 39):51-55, 1991.
25. Finlay AY: Global overview of Lamisil®. *Br J Dermatol* 130(suppl. 43):1-3, 1994.
26. Sansom JE, Burton JL, Leeming JP: Effect of terbinafine on *Malassezia furfur* populations on human skin. *Br J Dermatol*(abstract) 132:650, 1995.
27. Hill S, Thomas R, Smith SG, Finlay AY: An investigation of the pharmacokinetics of topical terbinafine 1% cream. *Br J Dermatol* 127:396-400, 1992.
28. Dykes PJ, Thomas R, Lever L, Marks R: Pharmacokinetics of topically applied terbinafine: results from studies in healthy volunteer subjects and patients with pityriasis versicolor. *J Dermatol Treat* 1 (suppl. 2):19-21, 1990.