

Sensitivity of the Cytomegalovirus Antigenemia Assay to Diagnose Cytomegalovirus Retinitis

Sun In Hong^{1,2}, Taeun Kim², Se Yoon Park³, Jiwon Jung⁴, Joo Yong Lee⁵, Yong Phil Chong², Heungsup Sung⁶, Sang-Oh Lee², Sang-Ho Choi², Yang Soo Kim², Jun Hee Woo², and Sung-Han Kim²

¹Department of Infectious Diseases, Gyeongsang National University Changwon Hospital, Gyeongsang National University School of Medicine, Changwon; ²Department of Infectious Diseases, Asan Medical Center, University of Ulsan College of Medicine, Seoul; ³Division of Infectious Diseases, Department of Internal Medicine, Soonchunhyang University Seoul Hospital, Soonchunhyang University College of Medicine, Seoul; ⁴Division of Infectious Diseases, Department of Internal Medicine, Ulsan University Hospital, University of Ulsan College of Medicine, Ulsan; ⁵Department of Ophthalmology, Asan Medical Center, University of Ulsan College of Medicine, Seoul; ⁶Department of Laboratory Medicine, Asan Medical Center, University of Ulsan College of Medicine, Seoul, Korea

Background: Cytomegalovirus (CMV) retinitis is one of the most important tissue-invasive CMV diseases in immunocompromised patients. Since 1980, non-invasive diagnostic methods, notably the CMV antigenemia assay, have been widely used as adjunct tests to diagnose tissue-invasive CMV diseases. However, there are limited data on the diagnostic value of the CMV antigenemia assay for diagnosing CMV retinitis.

Materials and Methods: We performed a retrospective review of all cases of CMV retinitis at Asan Medical Center, Seoul, South Korea over a 9-year period. The diagnosis of CMV retinitis was made by experienced ophthalmologists according to medical history and an ophthalmoscopic appearance of typical retinopathy, together with absence of an alternative diagnosis.

Results: We analyzed 44 patients with CMV retinitis (affecting 57 eyes) for whom the CMV antigenemia assay was performed. Of the 44 patients, 31 (70%) were HIV-uninfected and 13 (30%) were HIV-infected. The overall sensitivity of the CMV antigenemia assay was 66% (95% confidence interval [CI] 50–80%). The test's sensitivity showed a non-significant trend towards being higher in HIV-infected patients than in HIV-uninfected patients (sensitivity 85% vs 58%, respectively, $P = 0.16$). In a subgroup analysis of the 35 patients without other concurrent tissue-invasive CMV disease, the sensitivity of the CMV antigenemia assay was 57% (95% CI 40–74%).

Conclusions: The CMV antigenemia assay has limited value as a non-invasive diagnostic adjunct test for CMV retinitis. Therefore, the results of the assay need to be interpreted in the context of underlying disease, clinical presentation, and ophthalmoscopic findings.

Key Words: Cytomegalovirus; Retinitis; Diagnosis; Test

Received: May 29, 2016 **Accepted:** September 2, 2016 **Published online:** November 22, 2016

Corresponding Author : Sung-Han Kim, MD

Department of Infectious Diseases, Asan Medical Center, University of Ulsan College of Medicine, 86

Asanbyeongwon-gil, Songpa-gu, Seoul 05505, Korea

Tel: +82-2-3010-3305, Fax: +82-2-3010-6970

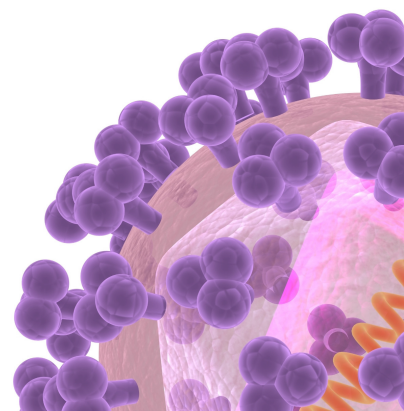
E-mail: kimsunghanmd@hotmail.com

* This paper was presented in part at the 55th Interscience Conference on Antimicrobial Agents and Chemotherapy, San Diego, 17-21 September 2015 (Poster session, abstract no. T-1367).

This is an Open Access article distributed under the terms of the Creative Commons Attribution Non-Commercial License (<http://creativecommons.org/licenses/by-nc/3.0>) which permits unrestricted non-commercial use, distribution, and reproduction in any medium, provided the original work is properly cited.

Copyrights © 2016 by The Korean Society of Infectious Diseases | Korean Society for Chemotherapy

www.icjournal.org



Introduction

Cytomegalovirus (CMV) disease is an important cause of morbidity and mortality among patients with impaired cellular immunity, including patients who have received solid organ transplants (SOT) or hematopoietic stem cell transplants (HCT), are undergoing chemotherapy for malignant disease, or are HIV-infected [1]. Of the various end organ diseases of CMV infection, CMV retinitis is the most common, and is the leading cause of disability in HIV-infected patients [2]. In addition, since the numbers of patients with SOT, HCT, and malignancy undergoing chemotherapy are increasing, the incidence of CMV retinitis is expected to increase [3]. Hence, accurate diagnosis and treatment of CMV retinitis is important in HIV-uninfected immunocompromised patients as well as in HIV-infected patients.

CMV retinitis is diagnosed by experienced ophthalmologists based on the patient's medical history, an ophthalmoscopic appearance typical of CMV retinopathy, and laboratory assessment of immune status that eliminates HIV retinopathy, toxoplasma retinitis, acute retinal necrosis, progressive outer retinal necrosis, and syphilitic retinochoroiditis [4]. The characteristic appearance of the infection is sufficiently distinctive that other diagnostic procedures are rarely needed. However, atypical cases, or infections with other organisms in patients at high risk of CMV retinitis, may require invasive diagnostic tests such as vitreous sampling. Furthermore, even invasive diagnostic tests may fail to establish the diagnosis. Since 1980, non-invasive diagnostic methods, such as the CMV antigenemia assay, have been widely used as adjunct tests for the diagnosis of tissue-invasive CMV diseases. However, data on the diagnostic value of the CMV antigenemia assay for CMV retinitis are limited [5]. Therefore, to assess its value, we compared the sensitivity of the CMV antigenemia assay to diagnose CMV retinitis in HIV-infected and HIV-uninfected patients.

Materials and Methods

1. Patient selection and method of CMV antigenemia assay

We reviewed the medical records of patients diagnosed with CMV retinitis between January 2005 and December 2013 in a 2,700-bed tertiary-care hospital in Seoul, Korea, where the prevalence of HIV infection is low. The CMV antigenemia assays used were the Light Diagnostics CMV pp65 antigenemia

assay (Millipore Corp., Temecula, CA, USA), used from January 2005 to February 2012, and the CINakit Rapid Antigenemia assay (Argene, North Massapequa, NY, USA), used from March 2012 to December 2013. These were performed as previously described [6]. Briefly, about 5 mL of blood was mixed with 1.5 mL of 6% dextran in saline and allowed to sediment. The polymorphonuclear leukocyte-enriched supernatant was extracted. Contaminating erythrocytes were lysed with a 0.8 NH_4Cl solution. After two washing steps, leukocyte suspensions were counted and adjusted to 1×10^6 cells/mL. A total of approximately 2×10^5 cells were spotted on a slide by cytocentrifugation, fixed in a 5% formaldehyde solution, and stained by immunofluorescent assay using a monoclonal antibody directed against the pp65 CMV antigen [7]. Counts were expressed as positive cells per 2×10^5 leukocytes [8, 9].

In kidney transplantation recipients, repeated CMV antigenemia assays were performed to monitor CMV infection at 1, 2, 3, 4, 6, 8, 12, 16, 20, and 24 weeks after transplantation [10]. In patients who underwent HCT, CMV antigenemia assays were performed weekly from day 21 to day 100 post-HCT, then monthly until one year after HCT [11]. Surveillance testing using the CMV antigenemia assay in patients with other underlying diseases was performed at the discretion of the attending physician.

2. Definition of CMV retinitis and outcomes

CMV retinitis was defined as presence of the characteristic ophthalmoscopic picture of necrotizing retinitis with or without hemorrhage, as determined by an ophthalmologist [4]. The diagnosis of CMV retinitis was confirmed by review of fundoscopic findings by an experienced retinal specialist JY Lee.

Best corrected visual acuity (BCVA) was measured using Snellen charts. BCVA was assessed whenever patients visited the ophthalmologist. Stable vision was defined as either the maintenance or improvement of BCVA subsequent to receiving a diagnosis of CMV retinitis. Worsening vision was defined as BCVA declining by ≥ 1 line. Visual loss was defined as a complete lack of light perception. "Default" was defined as being lost to follow-up because of death or transfer to another hospital. "Other" was defined when the result could not be analyzed because of the presence of other ophthalmologic diseases.

3. Literature review

We searched PubMed (which contains citations over the 30 years from 1985 to September 2014) for English-language literature on HIV-uninfected patients aged older than 19 years

with CMV retinitis. We used the search terms "cytomegalovirus", "retinitis", "NOT acquired immunodeficiency syndrome", and "NOT HIV". A total of 196 articles were found; 12 included the results of the CMV antigenemia assays. In addition, we searched the Korean-language literature in KoreaMed in a similar manner.

4. Statistical analysis

All statistical analyses were performed using SPSS version 21.0 (SPSS Inc., Chicago, IL, USA). Categorical variables were compared using Fisher's exact test or Pearson chi-square test, as appropriate. Continuous variables were compared using the Mann-Whitney *U*-test or Student's *t*-test. All tests were

two-tailed and differences were considered significant at *P* < 0.05.

5. Ethics statement

The study was approved by the Institutional Review Board of Asan Medical Center (No. 2013-1040) and the requirement for informed consent was waived because of the retrospective nature of the study.

Results

Fifty-two patients with CMV retinitis were identified. Eight were excluded because they had no CMV antigenemia assay

Table 1. Clinical characteristics and outcomes in patients with CMV retinitis who showed positive and negative CMV antigenemia results

	Total (n = 44)	CMV antigenemia positive (n = 29)	CMV antigenemia negative (n = 15)	P-value
Age, years, mean ± SD	46.1 ± 14.5	48.3 ± 13.5	41.9 ± 16.0	0.19
Bi-ocular involvement	13 (30)	10 (35)	3 (20)	0.49
Underlying disease				
HCT	13 (30)	8 (28)	5 (33)	0.74
Lymphoma	2 (5)	1 (3)	1 (7)	>0.99
Solid organ transplant	10 (23)	5 (17)	5 (33)	0.27
HIV	13 (30)	11 (38)	2 (13)	0.09
Solid tumor ^a	3 (7)	2 (7)	1 (7)	>0.99
Other ^b	3 (7)	2 (7)	1 (7)	>0.99
Anti-CMV therapy				
Systemic antiviral agents	22 (50)	13 (45)	9 (60)	0.34
Combined systemic and intravitreal injection	19 (43)	15 (52)	4 (27)	0.11
Intravitreal injection	2 (5)	0	2 (13)	0.11
None of the above	1 (2)	1 (3)	0	>0.99
Other concurrent CMV disease				
GI CMV disease	8 (18)	8 (28)	0	0.04
CMV hepatitis	1 (2)	1 (3)	0	>0.99
Outcome				
Stable	23 (52)	14 (48)	9 (60)	0.46
Progression	8 (18)	6 (21)	2 (13)	0.55
Visual loss	4 (9)	3 (10)	1 (7)	>0.99
Default	7 (16)	5 (17)	2 (13)	>0.99
Other	2 (5)	1 (3)	1 (7)	>0.99

Data are presented as number (%), unless otherwise indicated.

^aTwo patients had thymomas and one had a pancreatic cancer.

^bOne patient without underlying disease was treated in the intensive care unit for one month because of complicated methicillin-sensitive *Staphylococcus aureus* bacteremia with multiple metastatic infections; another had dyskeratosis congenita, and the third had interstitial lung disease; the latter two patients were treated with cyclosporine. CMV, cytomegalovirus; SD, standard deviation; HCT, hematopoietic stem cell transplants; HIV, human immunodeficiency virus; GI, gastrointestinal.

performed. Of the remaining 44 patients, 31 (70%) were HIV-uninfected. The cutoff value for a positive CMV antigenemia assay was set at one positive cell per 2×10^5 leukocytes. The results were positive in 29 (66%) of 44 patients and negative in the remaining 15 (34%) patients. The baseline clinical characteristics and outcomes of the patients with positive and negative CMV antigenemia results are presented in Table 1. The overall sensitivity of the CMV antigenemia assay was 66% (95% confidence interval [CI], 50–80%) (Table 2), showing a tendency to be higher in the HIV-infected patients (85% [11/13]) than in the HIV-uninfected patients (58% [18/31]), but this effect did not reach statistical significance ($P = 0.16$). Of the 31 HIV-uninfected patients, 10 had undergone SOT and 13 had undergone HCT. CMV retinitis was diagnosed at a median interval of 190 days (interquartile range [IQR] 140–430 days) and 84 days (IQR 44–233 days) post-transplantation in those who received SOT and HCT, respectively. Of these 23 patients, 5 (22%) had neutropenia (absolute neutrophil count ≤ 1.5 cells $\times 10^9$ /L) at the time they were diagnosed with CMV retinitis and 2 (9%) had severe neutropenia (absolute neutrophil count ≤ 0.5 cells $\times 10^9$ /L). The sensitivity of the CMV antigenemia assay in neutropenic patients was 40% (2/5) and in non-neutropenic patients was 61% (11/18). If patients with concurrent CMV diseases ($n = 9$) were excluded from the analysis, the sensitivity of the CMV antigenemia assay was 57% (20/35, 95% CI 40–74%) (Table 2). Twenty-seven of the 35 patients without concurrent CMV diseases were HIV-uninfected; the sensitivity of the assay in HIV-uninfected and HIV-infected patients was 52% (14/27) and 75% (6/8), respectively.

Overall, 23 (52%) patients had stable visual outcomes. Two of these underwent vitrectomy due to vitreous hemorrhage; their BCVAs improved. During the treatment of CMV retinitis, BCVA declined in 8 patients (17%) and 4 (9%) had no light perception. Three patients (7%) with CMV-related retinal detachment underwent retinal re-attachment surgery. The BCVA had deteriorated in 2 of these patients, and the remaining pa-

tient had no light perception. There were no statistically significant differences in outcomes between the HIV-infected and HIV-uninfected patients. The median follow-up duration of the 35 patients who did not default was 16.7 months (IQR 157–1,086 months).

We performed a literature review to determine the performance of the CMV antigenemia assay in CMV retinitis in HIV-uninfected patients (Table 3) [12–27]. CMV antigenemia assay results were available for a total of 18 patients among all the patients included in the 12 articles identified. The overall sensitivity of the CMV antigenemia assay in the literature review was 61% (11/18).

Discussion

The CMV antigenemia assay has been used to detect CMV reactivation in a variety of clinical settings [5, 28]. It has the advantages of providing results within 24 hours and being quantifiable. Its introduction has considerably improved the clinical management of CMV disease in allogeneic HCT and SOT recipients, using a preemptive approach. However, studies of the diagnostic value of the CMV antigenemia assay in CMV retinitis are limited. We previously showed that the CMV antigenemia test was positive in 54% (26/57; 95% CI 41–68%) of patients with CMV gastrointestinal disease and 69% (25/36; 95% CI 52–84%) of patients with CMV pneumonia, suggesting that it has low sensitivity for ruling out these 2 conditions [8, 9]. Xharred et al. [3] reported that the CMV antigenemia test or CMV PCR were negative in all of 6 hematopoietic stem cell transplant patients with CMV retinitis. Eid et al. [29] also found that only 4 of 9 (44%; 95% CI 18–74%) solid organ transplant recipients with CMV retinitis tested positive for CMV PCR or CMV culture. In the present study, the test's sensitivity in HIV-uninfected patients was 58% (18/31; 95% CI 42–74%). If patients with other concurrent CMV infections were exclud-

Table 2. Comparison of the sensitivity of the CMV antigenemia assay in HIV-uninfected and HIV-infected patients with CMV retinitis

	Total (n = 44)			No concurrent CMV disease (n = 35)		
	HIV-uninfected (n = 31)	HIV-infected (n = 13)	P-value	HIV-uninfected (n = 27)	HIV-infected (n = 8)	P-value
Positive CMV antigenemia ^a (%)	18 (58)	11 (85)	0.16	14 (52)	6 (75)	0.42
Peak level of CMV antigenemia (range)	9 (0–46)	7 (7–30)	0.70	4 (0–38)	4 (0–12)	0.89

Data are presented as number (%) or median (interquartile range).

^aOne or more positive cell per 200,000 leukocytes was considered a positive CMV antigenemia assay.

CMV, cytomegalovirus; HIV, human immunodeficiency virus.

ed from the analysis, the sensitivity was 52% (14/27; 95% CI 33–70%), suggesting that the assay is not useful for ruling out CMV retinitis. Interestingly, there was a statistically non-significant trend for the sensitivity in HIV-uninfected patients to be lower (58%) than in HIV infected patients (85%, $P = 0.16$). Such variable sensitivity might possibly reflect differences in the causes of CMV retinitis in HIV-uninfected patients compared with HIV-infected patients. Further studies are needed in this area.

Our study had several limitations. First, by virtue of its retrospective design, we could not gather clinical data at the time of presentation in all of the patients. Furthermore, because the patient population was heterogeneous, follow-up was not standardized. Second, due to the specific circumstances of the

Korean national medical insurance system, CMV PCR was not routinely performed for surveillance. The CMV antigenemia assay does not require expensive equipment and the associated costs are low. But it is time-consuming, labor-intensive, and requires a high level of technical expertise. In addition, there is no assay standardization and poor inter-institutional correlation exists. False negative results for CMV antigenemia can occur in patients with leukopenia [28, 30–32]. Furthermore, CMV antigenemia has a lower sensitivity than CMV PCR. However, in the light of previous results, it can be assumed that the use of PCR would not have yielded very different results [11]. Third, because patients who did not have CMV antigenemia assay results were excluded from the study population, there may have been some selection bias. Lastly,

Table 3. Literature review of the results of the CMV antigenemia test in HIV-uninfected patients with CMV retinitis

UPN [ref]	Sex / Age	Value of CMV antigenemia ^a	Underlying disease	Treatment
1 [12]	F/20	Negative	ALL s/p unrelated BMT	Foscarnet / intravitreal GCV
2 [13] ^b	F/27	600 / 2×10^5	Lung transplantation	Foscarnet
3 [14]	M/58	66 / 5×10^4	NHL s/p ASCT	GCV
4 [15]	M/26	Negative	azathioprine, prednisolone with CVI	GCV
5 [16]	M/42	Negative	FK, MME, prednisolone s/p KT	GCV / intravitreal GCV
6 [16]	M/31	Positive	CsA, MZ, prednisolone s/p KT	GCV
7 [16]	M/50	Negative	FK, MZ, prednisolone s/p KT	GCV
8 [16]	M/42	Negative	FK, MME, prednisolone s/p KT	GCV
9 [17]	F/51	$>50 / 4 \times 10^5$	Immunocompetent	GCV / intravitreal GCV
10 [18]	F/51	Negative	Prednisolone, azathioprine with DM	GCV
11 [19]	F/36	$12 / 2 \times 10^5$	AML s/p BMT	GCV
12 [20]	M/38	$10 / 1.5 \times 10^5$	ALL s/p BMT	GCV
13 [20]	F/43	$6 / 1.5 \times 10^5$	NHL s/p BMT	GCV
14 [20]	F/57	$28 / 1.5 \times 10^5$	AML s/p BMT	GCV / intravitreal GCV
15 [20]	F/41	$4 / 1.5 \times 10^5$	ALL s/p BMT	GCV
16 [21]	F/57	$2400 / 5 \times 10^5$	Cyclophosphamide, azathioprine, anti-TNF Ab with RA	GCV
17 [22]	F/61	$9 / 2 \times 10^4$	Intravitreal bevacizumab injection with diabetes retinopathy	GCV
18 [23]	F/52	Negative	Dexamethasone, cyclosporine with T-LGLL	GCV / intravitreal GCV
19-27 [24]	M (88%)/NA	NA	KT (1), SLE (1), lymphoma (3), AA (4)	NA
28-42 [25]	M (93%)/36	NA	AIDS	Various
43-58 [26]	M (81%)/33	NA ^c	s/p BMT	Various
59-77 [27]	M (63%)/14	NA	Various	Various

^aData are number of positive cells per number of leukocytes.

^bOnly UPN 2 had another concurrent CMV disease: CMV pneumonia.

^cSix among 16 CMV retinitis patients (38%) showed positive results in either CMV antigenemia assay or CMV PCR.

UPN, unique patient number; CMV, cytomegalovirus; ALL, acute lymphoblastic leukemia; BMT, bone marrow transplantation; GCV, ganciclovir; NHL, non-Hodgkin's lymphoma; ASCT, autologous stem cell transplantation; CVI, common variable immunodeficiency; FK, tacrolimus; MMF, mycophenolate mofetil; KT, kidney transplant; CsA, cyclosporine A; MZ, mizoribine; DM, dermatomyositis; AML, acute myeloid leukemia; TNF, tumor necrosis factors; RA, rheumatoid arthritis; T-LGLL, T cell large granular lymphocytic leukemia; s/p, status post; SLE, systemic lupus erythematosus; AA, aplastic anemia; AIDS, acquired immunodeficiency syndrome; NA, not applicable.

CMV retinitis is a rare disease. Therefore, the study patients were collected over a 9-year period. The medical management of patients after transplantation or on immunosuppressive therapy clearly changed over this period.

In conclusion, the CMV antigenemia assay has limited value as a noninvasive diagnostic adjunct test for CMV retinitis. Because of the high cost of a false-negative diagnosis of CMV retinitis the results of the assay need to be interpreted in the context of the underlying disease, clinical presentation, and ophthalmoscopic findings.

Acknowledgements

This work was supported by a grant from the Korea Health Technology R&D Project through the Korea Health Industry Development Institute (KHIDI), funded by the Ministry of Health & Welfare, Republic of Korea (grant no. HI15C1763).

Conflicts of Interest

No conflicts of interest.

ORCID

Sun In Hong <http://orcid.org/0000-0003-2575-2084>
 Taeun Kim <http://orcid.org/0000-0002-2075-4497>
 Se Yoon Park <http://orcid.org/0000-0002-4538-7371>
 Jiwon Jung <http://orcid.org/0000-0003-4333-3270>
 Sung-Han Kim <http://orcid.org/0000-0002-6596-8253>

References

- Rafailidis PI, Mourtzoukou EG, Varbobitis IC, Falagas ME. Severe cytomegalovirus infection in apparently immunocompetent patients: a systematic review. *Virol J* 2008;5:47.
- Gallant JE, Moore RD, Richman DD, Keruly J, Chaisson RE. Incidence and natural history of cytomegalovirus disease in patients with advanced human immunodeficiency virus disease treated with zidovudine. The Zidovudine Epidemiology Study Group. *J Infect Dis* 1992;166:1223-7.
- Xhaard A, Robin M, Scieux C, de Latour RP, Deplus S, Mazon MC, Devergie A, Esp  rou H, Rocha V, Gluckman E, Ribaud P, Soci   G. Increased incidence of cytomegalovirus retinitis after allogeneic hematopoietic stem cell transplantation. *Transplantation* 2007;83:80-3.
- Kuo IC, Kempen JH, Dunn JP, Vogelsang G, Jabs DA. Clinical characteristics and outcomes of cytomegalovirus retinitis in persons without human immunodeficiency virus infection. *Am J Ophthalmol* 2004;138:338-46.
- van den Berg AP, van der Bij W, van Son WJ, Anema J, van der Giessen M, Schirm J, Tegzess AM, The TH. Cytomegalovirus antigenemia as a useful marker of symptomatic cytomegalovirus infection after renal transplantation--a report of 130 consecutive patients. *Transplantation* 1989;48:991-5.
- P  rez JL, De O  a M, Niub   J, Villar H, Mel  n S, Garc  a A, Mart  n R. Comparison of several fixation methods for cytomegalovirus antigenemia assay. *J Clin Microbiol* 1995;33:1646-9.
- Podzamcz  r D, Ferrer E, Garc  a A, Ram  n JM, Niub   J, Sant  n M, Ruf   G, P  rez JL, Mart  n R, Gudiol F. pp65 antigenemia as a marker of future CMV disease and mortality in HIV-infected patients. *Scand J Infect Dis* 1997;29:223-7.
- Jang EY, Park SY, Lee EJ, Song EH, Chong YP, Lee SO, Choi SH, Woo JH, Kim YS, Kim SH. Diagnostic performance of the cytomegalovirus (CMV) antigenemia assay in patients with CMV gastrointestinal disease. *Clin Infect Dis* 2009;48:e121-4.
- Moon SM, Sung H, Kim MN, Lee SO, Choi SH, Kim YS, Woo JH, Kim SH. Diagnostic yield of the cytomegalovirus (CMV) antigenemia assay and clinical features in solid organ transplant recipients and hematopoietic stem cell transplant recipients with CMV pneumonia. *Transpl Infect Dis* 2012;14:192-7.
- Ko GB, Kim T, Kim SH, Choi SH, Kim YS, Woo JH, Kim YH, Park JB, Lee SK, Park SK, Park JS, Han DJ, Lee SO. Increased incidence of herpes zoster in the setting of cytomegalovirus preemptive therapy after kidney transplantation. *Transpl Infect Dis* 2013;15:416-23.
- Kim T, Lee YM, Lee SO, Choi SH, Kim YS, Woo JH, Sung H, Jung JH, Shin S, Kim YH, Kang YA, Lee YS, Lee JH, Lee KH, Park SK, Han DJ, Kim SH. Differences of cytomegalovirus diseases between kidney and hematopoietic stem cell transplant recipients during preemptive therapy. *Korean J Intern Med* 2016;31:961-70.
- Okamoto T, Okada M, Mori A, Saheki K, Takatsuka H, Wada H, Tamura A, Fujimori Y, Takemoto Y, Kanamaru A, Kakishita E. Successful treatment of severe cytomegalovirus retinitis with foscarnet and intraocular injection of ganciclovir in a myelosuppressed unrelated bone marrow transplant patient. *Bone Marrow Transplant* 1997;20:801-3.
- Alain S, Honderlick P, Grenet D, Stern M, Vadam C, Sanson-Le Pors MJ, Mazon MC. Failure of ganciclovir treatment associated with selection of a ganciclovir-resistant cytomegalovirus strain in a lung transplant recipient.

- Transplantation 1997;63:1533-6.
14. Miyamoto T, Gondo H, Miyoshi Y, Shigematsu H, Mine-matsu T, Takenaka K, Tanimoto K, Horiuchi T, Asano Y, Inaba S, Minamishima Y, Niho Y. Early viral complications following CD34-selected autologous peripheral blood stem cell transplantation for non-Hodgkin's lymphoma. *Br J Haematol* 1998;100:348-50.
 15. Ishikawa K, Ando Y, Narita M, Shinjoh M, Iwasaki T. Cytomegalovirus retinitis during immunotherapy for common variable immunodeficiency. *J Infect* 2002;44:55-6.
 16. Shimakawa M, Kono C, Nagai T, Hori S, Tanabe K, Toma H. CMV retinitis after renal transplantation. *Transplant Proc* 2002;34:1790-2.
 17. Stewart MW, Bolling JP, Mendez JC. Cytomegalovirus retinitis in an immunocompetent patient. *Arch Ophthalmol* 2005;123:572-4.
 18. Kim HR, Kim SD, Kim SH, Yoon CH, Lee SH, Park SH, Kim HY. Cytomegalovirus retinitis in a patient with dermatomyositis. *Clin Rheumatol* 2007;26:801-3.
 19. Chung H, Kim JG, Choi SH, Lee SY, Yoon YH. Bilateral toxoplasma retinochoroiditis simulating cytomegalovirus retinitis in an allogeneic bone marrow transplant patient. *Korean J Ophthalmol* 2008;22:197-200.
 20. Asano-Mori Y, Kanda Y, Oshima K, Kako S, Shinohara A, Nakasone H, Sato H, Watanabe T, Hosoya N, Izutsu K, Asai T, Hangaishi A, Motokura T, Chiba S, Kurokawa M. Clinical features of late cytomegalovirus infection after hematopoietic stem cell transplantation. *Int J Hematol* 2008;87:310-8.
 21. Haerter G, Manfras BJ, de Jong-Hesse Y, Wilts H, Mertens T, Kern P, Schmitt M. Cytomegalovirus retinitis in a patient treated with anti-tumor necrosis factor alpha antibody therapy for rheumatoid arthritis. *Clin Infect Dis* 2004;39:e88-94.
 22. Bae SH, Kim TW, Chung H, Heo JW. Cytomegalovirus retinitis after intravitreal bevacizumab injection in an immunocompetent patient. *Korean J Ophthalmol* 2013;27:61-3.
 23. Cheung CY, Wong IY, Yan KW, Kwong YL. Cytomegalovirus oral lesions: harbinger of retinitis in the absence of viraemia. *Ann Hematol* 2014;93:1613-5.
 24. Park YS, Kim YK, Choi JY, Kim MS, Shin SY, Kim YA, Ku NS, Kim JH, Song YG, Kwon OW, Kim JM. Clinical features and treatment of cytomegalovirus retinitis in Korea. *Infect Chemother* 2006;38:116-22.
 25. Yoon CK, Woo SJ, Yu HG. Visual outcome of cytomegalovirus retinitis in Korean patients with acquired immune deficiency syndrome. *J Korean Ophthalmol Soc* 2009;50:92-8.
 26. Choi SM, Lee DG, Park SH, Kim SH, Kim YJ, Min CK, Kim HJ, Lee S, Choi JH, Yoo JH, Kim DW, Lee JW, Min WS, Shin WS, Kim CC. Characteristics of cytomegalovirus diseases among hematopoietic stem cell transplant recipients: a 10-year experience at an university hospital in Korea. *Infect Chemother* 2009;41:9-19.
 27. Kwun YK, Chae JB, Ham DI. Clinical manifestations and prognosis of cytomegalovirus retinitis. *J Korean Ophthalmol Soc* 2010;51:203-9.
 28. Mori T, Okamoto S, Matsuo S, Yajima T, Wakui M, Watanabe R, Ishida A, Iwao Y, Mukai M, Hibi T, Ikeda Y. Risk-adapted pre-emptive therapy for cytomegalovirus disease in patients undergoing allogeneic bone marrow transplantation. *Bone Marrow Transplant* 2000;25:765-9.
 29. Eid AJ, Bakri SJ, Kijpittayarat S, Razonable RR. Clinical features and outcomes of cytomegalovirus retinitis after transplantation. *Transpl Infect Dis* 2008;10:13-8.
 30. Allice T, Cerutti F, Pittaluga F, Varetto S, Franchello A, Salizzoni M, Ghisetti V. Evaluation of a novel real-time PCR system for cytomegalovirus DNA quantitation on whole blood and correlation with pp65-antigen test in guiding pre-emptive antiviral treatment. *J Virol Methods* 2008;148:9-16.
 31. Cariani E, Pollara CP, Valloncini B, Perandin F, Bonfanti C, Manca N. Relationship between pp65 antigenemia levels and real-time quantitative DNA PCR for Human Cytomegalovirus (HCMV) management in immunocompromised patients. *BMC Infect Dis* 2007;7:138.
 32. Kim DJ, Kim SJ, Park J, Choi GS, Lee S, Kwon CD, Ki C, Joh J. Real-time PCR assay compared with antigenemia assay for detecting cytomegalovirus infection in kidney transplant recipients. *Transplant Proc* 2007;39:1458-60.