

# *Dermabacter hominis*에 의한 치명적인 패혈증 1예

이혜진 · 조치현 · 권민정 · 남명현 · 이갑노 · 이창규  
고려대학교 의과대학 진단검사의학교실

## A Patient with Fatal Septicemia Caused by a Rare Pathogen *Dermabacter Hominis*

*Dermabacter hominis* (*D. hominis*) is a recently discovered gram-positive bacterial species, and it is usually recognized as an opportunistic human pathogen. Very few documented cases of severe infections caused by *Dermabacter hominis* have been published. In this report, we describe a case of fatal septicemia caused by *Dermabacter hominis*.

**Key Words:** Septicemia, *Dermabacter hominis*

Hye-Jin Lee, Chi-Hyun Cho, Min-Jung Kwon, Myung-Hyun Nam, Kap-No Lee, and Chang-Kyu Lee

Department of Laboratory Medicine, Korea University  
College of Medicine, Seoul, Korea

## Introduction

*Dermabacter hominis* (*D. hominis*) has been identified as an asporogenous, non-motile, rod-shaped microorganism [1]. This agent is usually recognized as an opportunistic human pathogen. Cases of serious infections caused by this agent are extremely rare in Korea [2, 3]. We encountered a case of infection caused by *D. hominis* in a 56-year-old man who developed bacteremia and he finally expired from septic shock.

## Case Report

A 56-year-old man was admitted to our emergency department with cardiac arrest. At the time, he was in an asystolic state. Spontaneous circulation was returned after ten minutes of cardiopulmonary resuscitation (CPR) and the patient showed significant neurologic sequelae. A cerebral computed tomography (CT) scan and a magnetic resonance imaging (MRI) diffusion image showed hydrocephalus. Electroencephalography demonstrated severe hypoxic brain damage. Laboratory tests were performed and the results were hemoglobin: 14.6 g/dL, WBC: 12,900/mm<sup>3</sup>, platelets: 131,000/mm<sup>3</sup>, sodium: 140 mmol/L, potassium: 3.9 mmol/L, chloride: 100 mmol/L, prothrombin time (PT): 13 seconds and the activated partial thromboplastin time (aPTT): 33.5 seconds. He had no specific personal history of chronic disease or immune suppression. After two days, his vital signs were stable, but spontaneous breathing without

Copyright © 2011 by The Korean Society of Infectious Diseases | Korean Society for Chemotherapy

Submitted: September 9, 2010

Revised: October 13, 2010

Accepted: October 14, 2010

Correspondence to Chang-Kyu Lee, M.D.

Department of Laboratory Medicine, Korea University  
College of Medicine, Anam-dong 126-1, Seongbuk-gu, Seoul  
136-705, Korea

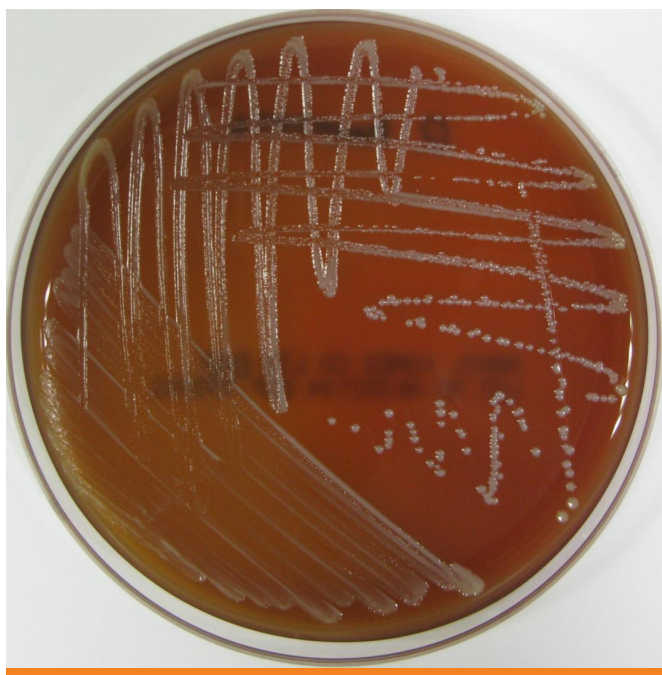
Tel: +82-2-920-5381, Fax: +82-2-920-5538

E-mail: cklee@korea.ac.kr

[www.icjournal.org](http://www.icjournal.org)

a mechanical ventilator was impossible. His mental status was comatose and he experienced intermittent seizures. In the following days, he suffered several febrile episodes. Two sets of blood cultures (each set consisted of one aerobic culture bottle and one anaerobic culture bottle) and sputum culture were taken. *D. hominis* was isolated from two aerobic culture bottles and one anaerobic culture bottle. *Haemophilus influenzae* was isolated from the tracheal aspirates. The urine culture and central venous catheter culture were negative. A chest X-ray revealed pulmonary congestion of both lung fields. Because pneumonia was suspected, the first empirical antibiotic treatment was started using ciprofloxacin for two days. And then, the antimicrobial therapy was then changed to intravenous vancomycin after *D. hominis* was isolated. While in the hospital, the patient suffered hypoxic brain damage, decreased blood pressure and continued febrile peaks of higher than 38°C. Unfortunately, the patient's condition progressively worsened and he expired from septic shock.

Blood was cultured from this patient, and it yielded bacteria that grew on 5% sheep blood agar plates (HanilKomed, Gyeonggi-do, Korea) as 0.5- to 1 mm diameter colonies after 24 hours in a room air. The colonies were grayish-white, convex and slightly viscid with a sweet, pungent odor (Fig. 1). The isolate was non-spore forming, small gram-positive bacilli with a coryneform appearance. Biochemical analysis showed that the colonies



**Figure 1.** Macroscopic morphology of *Dermabacter hominis* grown on a blood agar plate at room temperature for 24 hours. Note the small, convex, grayish-white colonies.

were positive for catalase and esculin hydrolyses and negative for urease, oxidase and nitrate reductions. Glucose, sucrose, maltose, lactose and xylose were fermented by this isolate, but mannitol was not fermented. The bacterium was identified using the API Coryne system (AB bioMérieux, Hazelwood, MO, USA) as *D. hominis* (code 4770765). Antibiotic susceptibility testing was initially performed using Sensi-discs (BD, Franklin Lakes, NJ, USA) on Mueller-Hinton blood agar plates. The isolated *D. hominis* was resistant to clindamycin, erythromycin, levofloxacin, penicillin, oxacillin and trimethoprim/sulfamethoxazole. The isolate was susceptible to vancomycin and teicoplanin. The MICs (Minimal Inhibitory Concentrations) for several antibiotics were determined with E-test strips (AB Biodisc, Solna, Sweden) on Mueller-Hinton blood agar plates and the results were penicillin G: 12 µg/mL, cefotaxime: 8 µg/mL and vancomycin: 0.25 µg/mL.

DNA was purified from the bacterial colonies using the DNeasy Tissue Kit (Qiagen, Hilden, Germany). The 16S rRNA gene was amplified by PCR (ABI 9700, Applied Biosystems, CA, USA); the reactions were heated to 95°C for five min, followed by 30 cycles of 95°C for 20 s, 52°C for 20 s and 72°C for 30 s. A final extension was carried out at 72°C for two minutes. The amplicon (approximately 1,500 bp) was run on agarose gel, and the bands were confirmed by ultraviolet (UV) transillumination. Analysis of the nucleotide sequence was performed using an ABI PRISM 3130 Sequencer (Applied Biosystems). The resulting 1,468-bp sequence was compared to the available sequences in the GenBank databases using the BLAST program [4]. More than 99% similarity was found with the *D. hominis* published sequences.

## Discussion

*D. hominis* is a gram-positive, asporogenous, non-motile, rod-shaped bacterium that produces small grayish-white colonies with an intense, pungent odor [1, 5, 6]. *D. hominis* bacteria have previously been defined as coryneform groups 3 and 5 in the Special Bacteriology Reference Laboratory collection of the Centers for Disease Control and Prevention (CDC). Groups 3 and 5 are identical except for their ability (group 3) or inability (group 5) to ferment xylose [1].

The bacteria were assigned to the genus and species *D. hominis* based on the chemotaxonomic, 16S rDNA sequence analyses and DNA-DNA hybridization studies [1, 7]. Chemotaxonomically, *D. hominis* has a cell wall based on meso-diaminopimelic acid and branched cellular fatty acids. These structures are also found in species of the genus *Brevibacterium*. However, *Brevibacterium*

*spp.* are nonfermentative and are phylogenetically quite distant from *D. hominis* [8].

*D. hominis* belongs to a new genus and it has recently been recognized as an opportunistic human pathogen. It has primarily been isolated from blood and less commonly from abscesses, wounds, skin lesions, eyes and other body sites. Very few case reports of documented infections caused by *D. hominis* have been described [2, 3, 9-11]. *D. hominis* has been shown to cause various conditions including cerebral abscess [2], bacteremia [3], peritoneal dialysis-associated peritonitis [10], chronic osteomyelitis [11], and chronic cutaneous abscesses [9]. In most cases, the patients had severe underlying conditions that caused the patients to be immunocompromised. Only one case of recurrent abscesses caused by *D. hominis* in an immunocompetent patient has been published [9]. It is known that brain injury and ischemia are related to the various immune mediators. Brain mediated immunosuppression increases the risk of infectious complications [12]. In this context, the severe hypoxic brain damage in this patient might have caused immunosuppression. The virulence of *D. hominis* is augmented in individuals with compromised defensive capacities or those individuals who are undergoing administration of broad spectrum antimicrobial treatment [3]. In the current study, fever episodes occurred prior to the antibiotic treatment. These findings illustrated that the pathogenesis of the severe infection in this patient was the compromised immune function rather than the broad spectrum antimicrobial treatment.

*D. hominis* is a rare, opportunistic pathogen and its clinical role has not yet been fully elucidated. The septicemia of *D. hominis* and the clinical course of the patient described in this report illustrate that *D. hominis* may well have the potential to cause severe systemic infection, and especially in patients with defective immune function and severe underlying diseases.

## References

1. Funke G, Stubbs S, Pfyffer GE, Marchiani M, Collins MD. Characteristics of CDC group 3 and group 5 coryneform bacteria isolated from clinical specimens and assignment to the genus *Dermabacter*. J Clin Microbiol 1994;32:1223-8.
2. Bavbek M, Caner H, Arslan H, Demirhan B, Tunçbilek S, Altinörs N Cerebral *Dermabacter hominis* abscess. Infection 1998;26:181-3.
3. Gómez-Garcés JL, Oteo J, García G, Aracil B, Alós JI, Funke G. Bacteremia by *Dermabacter hominis*, a rare pathogen. J Clin Microbiol 2001;39:2356-7.
4. Altschul SF, Madden TL, Schäffer AA, Zhang J, Zhang Z, Miller W, Lipman DJ. Gapped BLAST and PSI-BLAST: a new generation of protein database search programs. Nucleic Acids Res 1997;25:3389-402.
5. Bernard K, Bellefeuille M, Hollis DG, Daneshvar MI, Moss CW. Cellular fatty acid composition and phenotypic and cultural characterization of CDC fermentative coryneform groups 3 and 5. J Clin Microbiol 1994;32:1217-22.
6. Funke G, von Graevenitz A, Clarridge JE 3rd, Bernard KA. Clinical microbiology of coryneform bacteria. Clin Microbiol Rev 1997;10:125-59.
7. Gruner E, Steigerwalt AG, Hollis DG, Weyant RS, Weaver RE, Moss CW, Daneshvar M, Brenner DJ. Recognition of *Dermabacter hominis*, formerly CDC fermentative coryneform group 3 and group 5, as a potential human pathogen. J Clin Microbiol 1994;32:1918-22.
8. Cai J, Collins MD. Phylogenetic analysis of species of the meso-diaminopimelic acid-containing genera *Brevibacterium* and *Dermabacter*. Int J Syst Bacteriol 1994;44:583-5.
9. Martin J, Bemer P, Touchais S, Asseray N, Corvec S. Recurrent abscesses due to *Fingoldia magna*, *Dermabacter hominis* and *Staphylococcus aureus* in an immunocompetent patient. Anaerobe 2009;15:201-3.
10. Radtke A, Bergh K, Øien CM, Bevanger LS. Peritoneal dialysis-associated peritonitis caused by *Dermabacter hominis*. J Clin Microbiol 2001;39:3420-1.
11. Van Bosterhaut B, Boucquoy P, Janssens M, Wauters G, Delmée M. Chronic osteomyelitis due to *Actinomyces neuii* subspecies *neuii* and *Dermabacter hominis*. Eur J Clin Microbiol Infect Dis 2002;21:486-7.
12. Woiciechowsky C, Schöning B, Cobanov J, Lanksch WR, Volk HD, Döcke WD. Early IL-6 plasma concentrations correlate with severity of brain injury and pneumonia in brain-injured patients. J Trauma 2002;52:339-45.