

Epstein-Barr Virus Associated Hemophagocytic Syndrome after Scrub Typhus Infection

Jeong Woo Hong¹, Hyun Seon You¹, Tae Won Lee¹, Won Yong Jo¹, Bo Ra Kim¹, Young Sun Suh¹, In-Gyu Bae², and Oh-Hyun Cho²

¹Department of Internal Medicine, and ²Division of Infectious Diseases, Gyeongsang National University Hospital, Gyeongsang National University School of Medicine, Jinju, Korea

There have been a small number of cases of scrub typhus-associated hemophagocytic syndrome (HPS), most of which were treated successfully using adequate antibiotics. Here, we report a case of Epstein-Barr virus (EBV)-associated HPS after scrub typhus infection that was not improved using antirickettsial treatment. A 73-year-old male who had been diagnosed with scrub typhus according to an eschar and a positive serology was transferred to our institution because of a persistent fever despite 7-day doxycycline therapy. Physical and laboratory data showed hepatosplenomegaly, bicytopenia, hyperferritinemia, and hypofibrinogenemia. A bone marrow examination (BM) revealed hypercellular marrow with hemophagocytosis and histiocyte infiltration. EBV was detected in BM aspirates using polymerase chain reaction. After a diagnosis of HPS was made, the patient was treated successfully using high-dose steroids.

Key Words: Epstein-Barr virus infections; Lymphohistiocytosis, Hemophagocytic; Scrub typhus

Introduction

Hemophagocytic syndrome (HPS), also called hemophagocytic lymphohistiocytosis (HLH), is an uncommon but severe disease associated with various infectious, genetic, neoplastic, and autoimmune diseases [1]. It is characterized clinically by fever, cytopenia, splenomegaly, and hemophagocytosis in the bone marrow (BM), liver, or lymph nodes [2].

Scrub typhus is a disease caused by *Orientia tsutsugamushi*, and is treated mostly with antibiotics. However, it can be fatal for some patients because of acute renal failure, acute respiratory distress, and septic shock [3, 4]. HPS is a rare complica-

tion of scrub typhus, although it can be treated using adequate antibiotics. Here, we report a case of Epstein-Barr virus (EBV)-associated HPS after scrub typhus infection that was not improved using adequate anti-rickettsial treatment.

Case Report

A 73-year-old male, who was diagnosed with scrub typhus according to an eschar on the axilla and a positive result of indirect immunofluorescence assay for *O. tsutsugamushi* (antibody titer of 1:1,280), was transferred to our institution from a

Received: February 13, 2016 **Accepted:** May 5, 2016 **Published online:** November 8, 2016

Corresponding Author : Oh-Hyun Cho, MD

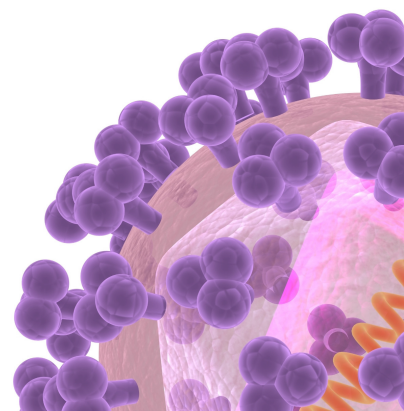
Department of Internal Medicine, Gyeongsang National University School of Medicine, 79 Gangnam-ro, Jinju 52727, Korea

Tel: +82-55-750-8745, Fax: +82-55-755-9078, E-mail: zenmd@naver.com

This is an Open Access article distributed under the terms of the Creative Commons Attribution Non-Commercial License (<http://creativecommons.org/licenses/by-nc/3.0>) which permits unrestricted non-commercial use, distribution, and reproduction in any medium, provided the original work is properly cited.

Copyrights © 2016 by The Korean Society of Infectious Diseases | Korean Society for Chemotherapy

www.icjournal.org



local hospital because of a persistent fever despite 7-day doxycycline therapy. The patient had no previous history of illness, blood transfusion, and did not take any medications before he visited the hospital. His occupation was a farmer, and he resided in a rural area of Goseong-gun, Gyeongsangnam-do, Korea. On admission, he had a body temperature of 36.9°C, a pulse of 72 beats/min, a respiration rate of 21 breaths/min, and a blood pressure of 97/54 mmHg. Hepatosplenomegaly, a maculopapular rash on the abdomen, and a 1-cm sized eschar on the left axillary area were observed. Laboratory results were as follows: Complete blood counts revealed a white blood cell (WBC) count of 2,610/mm³ (41.7% segmented neutrophils and 55.8% lymphocytes), a hemoglobin (Hb) level of 11.9 g/dL, and a platelet count of 237,000/mm³. The blood biochemical profile included 1,500 U/L lactate dehydrogenase, 675 U/L alkaline phosphatase, 245 U/L aspartate aminotransferase (AST), 106 U/L alanine aminotransferase (ALT), 6.6 g/L total protein, 2.3 g/L albumin, 444 U/L γ -glutamyl transpeptidase, 0.65 mg/dL total bilirubin, 61 mg/dL total cholesterol, 2,000 ng/mL ferritin, 70 mg/dL fibrinogen, 138 mg/dL triglyceride, 85.2 mg/L C-reactive protein, 18.4 mg/dL blood urea nitrogen, 0.67 mg/dL creatinine, and 3.4 mg/dL uric acid. Serological tests for human immunodeficiency virus, cytomegalovirus, parvovirus, Hantaan virus, leptospira, hepatitis A virus, hepatitis B virus, and hepatitis C virus were all negative. Anti-nuclear and rheumatoid factor antibodies were also negative. Blood and urine cultures were negative. However, indirect immunofluorescence antibody IgG for *O. tsutsugamushi* titer was positive at 1:5,120. An abdomen computerized tomography revealed hepatosplenomegaly. Azithromycin (500 mg daily) was provided for 5 days in consideration of an adverse drug reaction or doxycycline-resistant scrub typhus.

Four days after admission, his fever remained and his general condition had deteriorated. Laboratory data revealed a WBC of 1,800/mm³, 9.8 g/dL hemoglobin, a platelet count of 105,000/mm³, 591 U/L AST, and 365 U/L ALT. BM aspiration and biopsy were performed, which revealed hypercellular marrow with hemophagocytosis and histiocyte infiltration (Fig. 1). EBV was detected in BM aspirates using polymerase chain reaction (PCR), with a titer of 2,094 copies/ μ g DNA in peripheral blood mononuclear cells. A subsequent DNA test for *O. tsutsugamushi* in the blood was reported as negative by the Korea Center for Disease Control and Prevention.

After a diagnosis of HPS was made, 60 mg methylprednisolone was prescribed for 1-week, and the dose was then tapered by 10 mg every 3 days. His fever subsided on hospital day 8, and

subsequent tests revealed that his complete blood count profile recovered and his elevated liver enzymes declined to near normal levels within 3-weeks of starting steroid treatment.

Discussion

HPS is a fatal hyperinflammatory syndrome that is characterized by the activation and proliferation of histiocytes or lymphocytes with uncontrolled hemophagocytosis and cytokine overproduction [5]. The diagnosis of HPS is established by fulfilling five of the following eight criteria: 1) fever, 2) hepatosplenomegaly, 3) cytopenia (affecting two cell lineages), 4) hypertriglyceridemia and/or hypofibrinogenemia, 5) hemophagocytosis in the BM, spleen, or lymph nodes, 6) low or absent natural killer (NK) cell cytotoxicity, 7) hyperferritinemia, and 8) elevated soluble CD25 (sCD25) levels [6]. Because scrub typhus and HPS have similar clinical characteristics, such as cytopenia, hepatosplenomegaly, and abnormal liver function tests, scrub typhus infection can make diagnosing HPS challenging.

EBV is a causative organism of HPS, and is particularly notorious for its severe morbidity and mortality [7]. Therefore, the early diagnosis and treatment of EBV-associated HPS (EBV-HPS) is essential for a good outcome [8]. The pathogenesis of EBV-HPS is that EBV-infected B cells stimulate cytotoxic T lymphocytes, which leads to hypercytokinemia and the stimulation of histolytic cells [9]. EBV causes the stimulation, generation, and uncontrolled secretion of T and NK cells, as well as the generation of IL-2, INF- α , and IL-6, which are responsible for HPS [10]. Of these immunological profiles, an in-

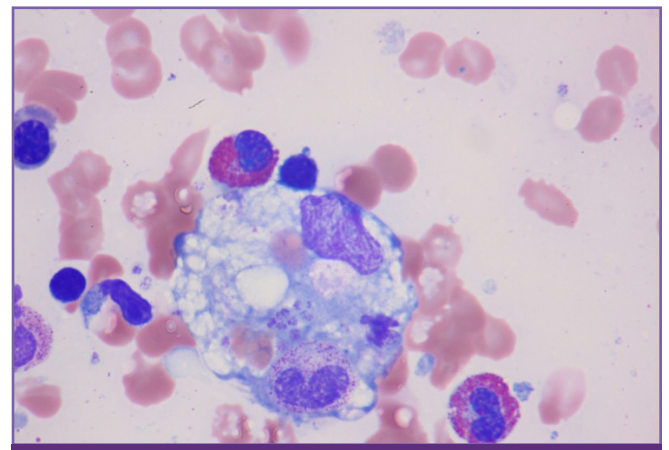


Figure 1. Microscopic finding of bone marrow aspiration shows hemophagocytosis of neutrophils, normoblasts, and platelets (Wright-Giemsa stain, $\times 1,000$).

Table 1. Cases of scrub typhus associated hemophagocytic syndrome

Case [Ref]	Age/ Sex	WBC (/mm ³)	Hb (g/dL)	Platelet (/mm ³)	Ferritin (ng/mL)	Associated Infection	Treatment drug	Outcome
1 [14]	75/F	5,600	12.8	14	183	-	Doxycycline Prednisolone 1 mg/kg	Improved within 10 days
2 [14]	69/F	1,300	11.3	75	282	-	Minocycline	Improved within 10 days
3 [15]	74/F	6,700	12.3	165	-	Parvovirus B19	Minocycline	Improved within 1 days
4 [16]	58/F	2,300	6.5	56	-	-	Doxycycline	Improved within 3 days
5 [16]	37/F	3,300	9.6	106	-	-	Doxycycline	Improved within 2 days
6 [17]	81/F	9,780	6.9	72	1,530	-	Doxycycline Prednisolone 1 mg/kg	Expired at 39 hospital day
7 [18]	7/M	2,520	7.9	17	>1,650	EBV	Etoposide, Dexamethasone	Improved within 4 weeks
8 [19]	34/F	3,500	8.4	16	3,212	EBV, CMV	Ceftriaxone, Minocycline	Expired at 13 hospital day
Case	73/M	2,610	11.9	237	2,000	EBV	Azithromycin Methylprednisolone 1 mg/kg	Improved within 3 weeks

WBC, white blood cell; Hb, hemoglobin, EBV, Epstein-Barr virus; CMV, cytomegalovirus.

creased plasma concentration of the soluble IL-2 receptor (sCD25) and impaired NK cell activity are two important diagnostic parameters in HPS [7]. The elevation of sCD25 suggests the activation of T lymphocytes, and is closely related with prognosis of HPS [11]. However, NK cell activity and CD25 level were not performed in this case, because those tests were not supported at our laboratory facility.

According to the HLH-2004 guidelines, the treatment for EBV-HPS is usually composed of etoposide-based chemotherapy and high-dose steroids to relieve the hyperinflammatory state, which is based on the clinical data of familial HPS [6]. Therefore, the effectiveness of the HLH-2004 guidelines for secondary HPS is not established definitely. A previous case of EBV-HPS after scrub typhus infection was reported in a pediatric patient, which was improved after chemotherapy including dexamethasone, etoposide, and clarithromycin [7]. The current case was improved without intensive chemotherapy, which might be harmful due to its adverse effects. The relatively low copy numbers of EBV-DNA suggest that the HPS might have been less severe in the current case. The EBV viral loads in EBV-HPS cases reported previously range from >1,000-1,000,000 copies/μg; therefore, measuring the level of viral DNA using quantitative PCR might be useful to demonstrate the treatment response and predict mortality [12].

Because EBV can be reactivated in critically ill patients [13], some might argue that EBV served as a bystander in the current case, and that HPS arises from scrub typhus itself. While most cases of HPS associated with scrub typhus infection are improved by adequate antibiotic treatment, as shown in Table

1, the current patient did not improve with azithromycin until steroids were initiated.

In addition, previous case reports showed that viruses such as EBV, CMV and parvovirus can trigger HPS after scrub typhus infection (Table 1) [14-19]. Considering the *O. tsutsugamushi* PCR results in blood was negative in the current case and there have been no reports of doxycycline-resistant *O. tsutsugamushi* in South Korea, it is unlikely that scrub typhus is the only reason for HPS. Therefore, we regarded that EBV triggered HPS after a scrub typhus infection in the current case. We could not determine whether it was primary infection or a reactivation because an EBV serological test was not performed. However, it is possible that the current case was caused by the reactivation of EBV because more than 87.2% of adults in South Korea have EBV-viral-capsid antigen (VCA) IgG antibodies [20].

The current case suggests that secondary HPS should be considered as a differential diagnosis when there is no improvement after treating scrub typhus using adequate antirickettsial therapy.

Conflicts of Interest

No conflicts of interest.

ORCID

Jeong Woo Hong

<http://orcid.org/0000-0001-8744-9772>

Oh-Hyun Cho

<http://orcid.org/0000-0002-4630-1242>

References

1. Fisman DN. Hemophagocytic syndromes and infection. *Emerg Infect Dis* 2000;6:601-8.
2. Scott R, Robb-Smith A. Histiocytic medullary reticulosis. *Lancet* 1939;2:194-8.
3. Lee HG, Min SK, Kong SJ, Lee SJ, Song HH, Yoon JW, Lee MG, Shin DH, Kang SH, Lee JY, Park YI, Choi MG. Clinical features of tsutsugamushi disease in Chuncheon. *Korean J Med* 2005;69:190-6.
4. Varghese GM, Abraham OC, Mathai D, Thomas K, Aaron R, Kavitha ML, Mathai E. Scrub typhus among hospitalised patients with febrile illness in South India: magnitude and clinical predictors. *J Infect* 2006;52:56-60.
5. Fujiwara F, Hibi S, Imashuku S. Hypercytokinemia in hemophagocytic syndrome. *Am J Pediatr Hematol Oncol* 1993;15:92-8.
6. Henter JL, Horne A, Aricó M, Egeler RM, Filipovich AH, Imashuku S, Ladisch S, McClain K, Webb D, Winiarski J, Janka G. HLH-2004: Diagnostic and therapeutic guidelines for hemophagocytic lymphohistiocytosis. *Pediatr Blood Cancer* 2007;48:124-31.
7. Rouphael NG, Talati NJ, Vaughan C, Cunningham K, Moreira R, Gould C. Infections associated with haemophagocytic syndrome. *Lancet Infect Dis* 2007;7:814-22.
8. Weitzman S. Approach to hemophagocytic syndromes. *Hematology Am Soc Hematol Educ Program* 2011;2011:178-83.
9. Lay JD, Chuang SE, Rowe M, Su IJ. Epstein-barr virus latent membrane protein-1 mediates upregulation of tumor necrosis factor-alpha in EBV-infected T cells: implications for the pathogenesis of hemophagocytic syndrome. *J Biomed Sci* 2003;10:146-55.
10. Lay JD, Tsao CJ, Chen JY, Kadin ME, Su IJ. Upregulation of tumor necrosis factor-alpha gene by Epstein-Barr virus and activation of macrophages in Epstein-Barr virus-infected T cells in the pathogenesis of hemophagocytic syndrome. *J Clin Invest* 1997;100:1969-79.
11. Filipovich AH. Hemophagocytic lymphohistiocytosis (HLH) and related disorders. *Hematology Am Soc Hematol Educ Program* 2009:127-31.
12. Yamashita N, Kimura H, Morishima T. Virological aspects of Epstein-Barr virus infections. *Acta Med Okayama* 2005;59:239-46.
13. Walton AH, Muenzer JT, Rasche D, Boomer JS, Sato B, Brownstein BH, Pachot A, Brooks TL, Deych E, Shannon WD, Green JM, Storch GA, Hotchkiss RS. Reactivation of multiple viruses in patients with sepsis. *PLoS One* 2014;9:e98819.
14. Takami A, Yamauchi H, Asakura H, Ishiyama K, Nakao S. Tsutsugamushi disease (scrub typhus)-associated hemophagocytic syndrome. *Int J Hematol* 2002;75:337-8.
15. Miyakawa K, Ohsugi K, Sugahara S, Kuriyama C, Kikuchi A, Ohta M. Tsutsugamushi disease with hemophagocytosis complicated by Parvovirus B19 infection. *Nihon Naika Gakkai Zasshi* 2006;95:2544-6.
16. Premaratna R, Williams HS, Chandrasena TG, Rajapakse RP, Kularatna SA, de Silva HJ. Unusual pancytopenia secondary to haemophagocytosis syndrome in rickettsioses. *Trans R Soc Trop Med Hyg* 2009;103:961-3.
17. Kim HW, Choi BS, Kim JH, Shin YM, Lee SJ, Kim SR, Jun JB. A case of death due to hemophagocytic lymphohistiocytosis accompanied by scrub typhus. *Infect Chemother* 2010;42:266-70.
18. Hong JH, Cho HJ, Kim HM, Namgoong MK, Kwon O, Chun JK. A case of Epstein-Barr virus associated hemophagocytic lymphohistiocytosis after scrub typhus infection. *Clin Pediatr Hematol Oncol* 2012;19:49-52.
19. Lin YH, Lin YH, Shi ZY. A case report of scrub typhus-associated hemophagocytic syndrome and a review of literature. *Jpn J Infect Dis* 2014;67:115-7.
20. Kang CI, Choi CM, Park JT, Park TS. Seroprevalence of Epstein-Barr virus infection in young men of South Korea. *Infect Chemother* 2007;39:93-4.