

Acinetobacter Prosthetic Joint Infection Treated with Debridement and High-Dose Tigecycline

Andrea Vila¹, Hugo Pagella², Claudio Amadio¹, and Alejandro Leiva³

¹Department of Infectious Diseases; ²Department of Microbiology Laboratories; ³Department of Orthopedic Surgery, Hospital Italiano, Mendoza, Argentina

Prosthesis retention is not recommended for multidrug-resistant *Acinetobacter* prosthetic joint infection due to its high failure rate. Nevertheless, replacing the prosthesis implies high morbidity and prolonged hospitalization. Although tigecycline is not approved for the treatment of prosthetic joint infection due to multidrug resistant *Acinetobacter baumannii*, its appropriate use may preclude prosthesis exchange. Since the area under the curve divided by the minimum inhibitory concentration is the best pharmacodynamic predictor of its efficacy, we used tigecycline at high dose, in order to optimize its efficacy and achieve implant retention in 3 patients who refused prosthesis exchange. All patients with prosthetic joint infections treated at our Institution are prospectively registered in a database. Three patients with early prosthetic joint infection of total hip arthroplasty due to multidrug resistant *A. baumannii* were treated with debridement, antibiotics and implant retention, using a high maintenance dose of tigecycline (100 mg every 12 hours). The cases were retrospectively reviewed. All patients signed informed consent for receiving off-label use of tigecycline.

Tigecycline was well tolerated, allowing its administration at high maintenance dose for a median of 40 days (range 30–60). Two patients were then switched to minocycline at standard doses for a median of 3.3 months in order to complete treatment. Currently, none of the patients showed relapse. Increasing the dose of tigecycline could be considered as a means to better attain pharmacodynamic targets in patients with severe or difficult-to-treat infections. Tigecycline at high maintenance dose might be useful when retention of the implant is attempted for treatment for prosthetic joint infections due to multidrug resistant *Acinetobacter*. Although this approach might be promising, off-label use of tigecycline should be interpreted cautiously until prospective data are available. Tigecycline is probably under-dosed for the treatment of implant and biofilm associated infections.

Key Words: Prosthetic joint infection; Tigecycline; *Acinetobacter*; High dose

Received: May 11, 2015 **Accepted:** July 9, 2015 **Published online:** November 8, 2016

Corresponding Author : Andrea Vila, MD

Hospital Italiano de Mendoza, Avenida Acceso Este, Lateral Norte 1070, CP 5519, Guaymallén, Mendoza, Argentina

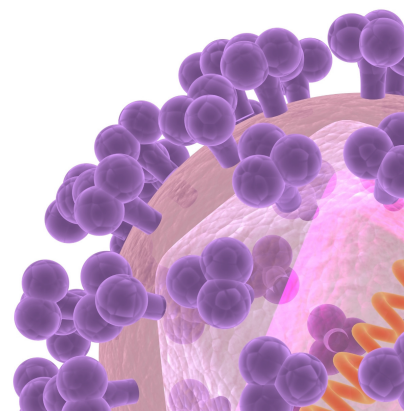
Tel: +54-261-4444470, Fax: +54-261-4058600

E-mail: santander@arlink.net.ar

This is an Open Access article distributed under the terms of the Creative Commons Attribution Non-Commercial License (<http://creativecommons.org/licenses/by-nc/3.0>) which permits unrestricted non-commercial use, distribution, and reproduction in any medium, provided the original work is properly cited.

Copyrights © 2016 by The Korean Society of Infectious Diseases | Korean Society for Chemotherapy

www.icjournal.org



Introduction

The treatment of prosthetic joint infection (PJI) requires both antimicrobials and surgery. The latter falls into two main groups: exchange arthroplasty (in either a single procedure or in two stages), or surgical drainage with retention of the prosthesis, followed by a finite course of antibiotics [1]. Exchange arthroplasty entails loss of bone stock and protracted immobilization; making this approach technically difficult and sometimes not accepted to the patient. Patients with well-fixed prosthesis, early PJI (within 30 days of implantation) and fewer than 3 weeks from onset of infectious symptoms could be considered for debridement, antibiotics and implant retention (DAIR) [1].

DAIR failure is related to the presence of biofilm. It is unknown how quickly a clinically meaningful biofilm forms; however, DAIR is not recommended if the interval between infection onset and debridement is > 28 days [2]. Failure rates are high (70.6%) when DAIR is attempted in infections due to fluoroquinolone (FQ) resistant Gram-negative bacilli (GNB) [3]. Therefore revision surgery is usually advised for PJI caused by multidrug resistant (MDR) GNB. If DAIR is the chosen strategy for MDR-GNB, then antimicrobial agent and dosage as well as surgical technique must be optimized to achieve clinical success. *Acinetobacter* is capable of forming biofilm on diverse surfaces, including implants.

Tigecycline (TGC) is a broad-spectrum antibiotic that binds to the 30S subunit of the ribosome, blocking protein synthesis, inhibiting the growth of multiple Gram-positive, Gram-negative, and anaerobic bacteria, including methicillin-resistant *Staphylococcus aureus* and vancomycin-resistant *Enterococcus* spp. TGC has reduced activity against *Proteus* spp., *Morganella* spp., *Providencia* spp. and *Pseudomonas* spp. The drug has very large volume of distribution with tissue-to-serum concentrations ≥ 2 -fold [4]. Intracellular concentrations are 20 to 30 times higher than extracellular concentrations [5]. Bone tissue TGC concentrations up to 4.77 times higher than serum have been reported in healthy subjects [6, 7].

Although TGC displays *in vitro* inhibitory activity against MDR *Acinetobacter* strains, neither the Clinical and Laboratory Standards Institute (CLSI) nor the European Committee on Antimicrobial Susceptibility Testing (EUCAST) have issued breakpoint recommendations for *Acinetobacter* spp. Breakpoints referring to Enterobacteriaceae are being used as provisional breakpoints for *Acinetobacter* in most studies. Breakpoints issued by CLSI and EUCAST for Enterobacteriaceae are different. CLSI minimum inhibitory concentration (MIC)

breakpoints for susceptibility (S) and resistance (R) are 2 and 8 mg/L, respectively; whereas the corresponding EUCAST breakpoints are 1 and 2 mg/L, respectively [8]. Breakpoints pertinent to disc diffusion method (DDM) with 15 μ g disc suggested by the FDA are as follows (zone diameter in mm): S > 19, I 15-18, R: <14. EUCAST breakpoints are S >18, R <15. These breakpoints have been determined for parenteral use of TGC at the approved dosage of 50 mg twice daily after a 100 mg loading dose.

TGC exhibits time-dependent antimicrobial activity and a prolonged post-antibiotic effect; thus, the area under the curve (AUC)/MIC ratio is the most predictive index related to efficacy. The reported adverse are nausea, vomiting, diarrhea, thrombocythemia, anemia, and pancreatitis. A review of the adverse event profile of TGC suggested that off-label use rarely causes unexpected adverse events, presumably due to usage with extreme caution. Nevertheless, more recently, the use of TGC has been associated with decreased fibrinogen levels, especially at high doses [9].

There is limited clinical experience in the treatment of PJI with TGC [10]. Increased dosing might be a useful strategy to achieve clinical success in the presence of PJI in which DAIR is the anticipated surgical strategy. The theoretical rationale for this indication is based on the pharmacodynamic (PD) properties of TGC (AUC/MIC ratio is the most predictive index related to clinical and microbiological efficacy), the presence of biofilm-associated infection with diminished antimicrobial penetration, and the MDR profile of the organism. Additionally, isolated reports [11-13] and a recent review [14] suggest that high-dose regimens may be more effective. The scarce previous reports on the use of high-dose regimens of TGC have been reported in patients with bacteremia [11] and urinary tract infections due to MDR *Klebsiella pneumoniae* and *A. baumannii* [12]. Up to a 400 mg initial dose followed by a 200 mg maintenance dose has been reported without relevant side effects [12]. A phase II trial and a cohort of critical patients with ventilator-associated pneumonia showed that TGC at higher than recommended doses had a safety profile similar to that of the approved doses [7, 13].

We report 3 cases of *A. baumannii* PJIs successfully retained with debridement and TGC using high maintenance dose (HMD).

Case Report

The study was performed at Hospital Italiano de Mendoza, a

120-bed university-affiliated teaching hospital. All patients with PJI were prospectively registered in a database. Cases of MDR *A. baumannii* PJIs treated with DAIR and TGC HMD were retrospectively reviewed. Institutional-approved informed consent was obtained from all patients. Relevant information about patient's demographics, comorbidity, type of implant, clinical manifestations, laboratory findings, antimicrobial therapy, and outcome were reviewed. Adverse events were determined through clinical symptoms and biochemical abnormalities documented in the medical records. PJI was classified as early when symptoms presented less than 4 weeks after arthroplasty [15]. PJI due to MDR *A. baumannii* was defined by isolation of *A. baumannii* from ≥ 2 deep surgical samples. Recurrent infection was defined as having *A. baumannii* isolated at the original site of infection after completing the antimicrobial treatment course for the initial infection. Subsequent debridement was not regarded as a failure. Successful outcome was defined as lack of signs and symptoms of infection, C-reactive protein level of <10 mg/L, normal erythrocyte sedimentation rate, and absence of radiological signs of loosening at the end of treatment, without further recurrences.

HMD-TGC treatment was defined as the use of 100 mg every 12 hours after an initial loading dose of 100 mg. TGC susceptibility was performed in Oxoid Mueller-Hinton agar by the disk diffusion method with a 15- μ g TGC-disk as described [16]. For interpretative criteria, the breakpoints defined by the EUCAST for *Enterobacteriaceae* were taken into account [17]. *A. baumannii* was defined as MDR if it was resistant to ≥ 3 classes of antimicrobial agents.

Between 2010 and 2012, two women and one man with revision total hip arthroplasty (THA) PJI received TGC-HMD for MDR *A. baumannii* PJI (Table 1). All the patients refused prosthesis exchange at the time of diagnosis of PJI. The median age was 58 years. All PJI were early, with an average time from implant to PJI diagnosis of 10.3 days. Average baseline C-reactive protein and erythrocyte sedimentation rate were 70 and 62, respectively (Table 1). Open and extensive debridement was promptly performed in all cases (average time from infection onset to debridement of 15 days). At least 4 intra-operative samples were obtained with separate instruments and placed into separate containers for processing. None of the patients received antibiotics prior to culture. Prophylactic antibiotics were withheld until the biopsies were obtained. In all cases, the culture showed mono-microbial growth of MDR *A. baumannii* in at least 3 surgical samples (Table 1). All strains were susceptible to colistin, TGC, and minocycline; and resis-

tant to FQ, b-lactams (including carbapenems) and aminoglycosides.

All patients required at least one additional debridement. One patient required 4 additional debridements (Table 1). In all cases, debrided tissue was sent for cultures with negative results.

All patients received TGC at a loading dose of 100 mg followed by 100 mg every 12 hours. To reduce nausea or vomiting, the drug was diluted in 400 ml of dextrose and administered at a slow infusion rate, and patients were instructed to eat during the infusion if nausea developed. Colistin was added as a concomitant drug in the immediate postoperative period when *A. baumannii* was recovered on cultures until definitive susceptibility results were obtained (median: 8.7 days) (Table 1). None of the patients received chronic oral suppressive therapy. Criteria for stopping antimicrobial therapy were clinical resolution of infection, healed wound, normalization of serum inflammatory markers [2], and a minimum of 1 month of antimicrobial treatment completed. The patients were followed weekly after discharge while on treatment. Signs of infection, laboratory tests, and secondary effects attributable to TGC were recorded. Once the treatment was finished, patients were followed monthly for 6 months, then every 3 months for 2 years, and annually for a median of 2.47 years (Table 1).

TGC was well tolerated allowing its administration at the mentioned doses for a median of 40 days. Two patients were then switched to oral minocycline at 100 mg every 12 hours for a median of 5 months for completion of therapy (Table 1).

None of the patients required dose modification or experienced unexpected adverse events. All patients are asymptomatic with functional THA at present.

Discussion

The treatment of PJIs is difficult, because the presence of a biofilm impairs antimicrobial activity. Therefore, treatment requires surgery with removal of necrotic tissue, and antimicrobial treatment with drugs that achieve good penetration and activity in bone and biofilm. The current recommended treatment for PJI due to MDR GNB is removal of the implant [18], but this is not always feasible.

The emergence of MDR *Acinetobacter* infections has led to the off-label use of TGC, appealing to its *in vitro* spectrum. *In vitro* susceptibility tests are static measures with a standardized concentration of drug and standardized microorganism

Table 1. Characteristics of 3 patients with THA PJI

	Case 1	Case 2	Case 3
Age (years)	45	54	75
Sex	Female	Male	Female
Body weight (kg)	95	82	90
THA material	Metal-on-polyethylene	Metal-on-polyethylene	Metal-on-polyethylene
THA fixation	Hybrid	Cemented	Hybrid
Underlying systemic diseases	No	No	No
Symptoms and signs of infection			
Pain	Yes	Yes	Yes
Erythema	Yes	No	Yes
Swelling	Yes	Yes	Yes
Fever ($\geq 38^{\circ}\text{C}$)	Yes	Yes	No
Sinus tract	No	No	No
Bacteremia	No	No	No
Baseline laboratory data			
C-reactive protein mg/L	121	34	56
ESR mm/1 hour	70	83	34
Time from implant to infection diagnosis (days)	13	11	7
Time from implant to debridement (days)	14	17	42
Time from infection onset to debridement (days)	4	6	35
Number of surgical samples obtained at first debridement	4	4	7
Number of positive culture / number of surgical samples obtained	4/4	4/4	6/7
Additional debridement required (number)	4	1	1
Intravenous tigecycline therapy			
Total Treatment Duration (days)	60	30	30
Inpatient Treatment (days)	28	10	6
Catheter used for drug infusion	CVC	PICC	PICC
Concomitant Drug			
Colistin (duration in days)	12	8	6
Oral minocycline (200 mg/day) after tigecycline discontinuation (months)	3	7	No
Follow up after therapy discontinuation (months)	28	31	30

THA, total hip arthroplasty; PJI, prosthetic joint infection; ESR, erythrocyte sedimentation rate; CVC, central venous catheter; PICC, peripherally inserted central catheter.

inoculum. However, *in vivo* efficacy will ultimately depend on the amount of drug that faces an unpredictable bacterial inoculum at the site of infection. Thus, the use of fixed TGC doses against a wide range of bacteria with variable MICs at different tissues should be questioned [19].

TGC seems useful for the treatment of PJI due to its extensive bone penetration and its activity against intracellular, slowly growing, and biofilm-forming bacteria. Nevertheless, it is probably under-dosed for the treatment of infections due to MDR *Acinetobacter*. As the AUC/MIC ratio is the major determinant of TGC antimicrobial activity, increasing the daily dosage would increase clinical efficacy. Although there is in-

sufficient data regarding the application of therapeutic drug monitoring to TGC administration, this would be a valuable tool for optimizing and individualizing TGC treatment [20].

We used a higher than standard dose in order to increase the probability of attaining targeted pharmacodynamics exposure against MDR *A. baumannii* at the site of infection in 3 patients with acute PJI. All the patients achieved clinical cure and successful prosthetic retention.

An additional key for success of conservative strategies is prompt and (eventual) repeated debridements in order to decrease bacterial inoculum and detach biofilm.

The present report suggests that TGC at HMD (100 mg every

12 hours) may represent a useful tool for the success of DAIR in early PJI due to MDR *A. baumannii* after THA.

HMD TGC appears to be safe and well tolerated. Further studies are necessary in order to confirm this observation.

Acknowledgments

Dr. Andrea Vila wishes to express her gratitude to Clara Achilli for reading and correcting the manuscript, and Dr. Roberto Francisco Furnari for his invaluable clinical assistance of the patients.

Conflicts of Interest

No conflicts of interest.

ORCID

Andrea Vila <http://orcid.org/0000-0002-1146-0120>

Claudio Amadio <http://orcid.org/0000-0002-9653-0887>

References

- Osmon DR, Berbari EF, Berendt AR, Lew D, Zimmerli W, Steckelberg JM, Rao N, Hanssen A, Wilson WR; Infectious Diseases Society of America. Executive summary: diagnosis and management of prosthetic joint infection: clinical practice guidelines by the infectious diseases society of America. *Clin Infect Dis* 2013;56:1-10.
- Estes CS, Beauchamp CP, Clarke HD, Spangehl MJ. A two-stage retention debridement protocol for acute periprosthetic joint infections. *Clin Orthop Relat Res* 2010;468:2029-38.
- Jaén N, Martínez-Pastor JC, Muñoz-Mahamud E, García-Ramiro S, Bosch J, Mensa J, Soriano A. Long-term outcome of acute prosthetic joint infections due to gram-negative bacilli treated with retention of prosthesis. *Rev Esp Quimioter* 2012;25:194-8.
- Prasad P, Sun J, Danner RL, Natanson C. Excess deaths associated with tigecycline after approval based on noninferiority trials. *Clin Infect Dis* 2012;54:1699-709.
- MacGowan AP. Tigecycline pharmacokinetic/pharmacodynamic update. *J Antimicrob Chemother* 2008;62 (Suppl 1):i11-6.
- Rodvold KA, Gotfried MH, Cwik M, Korth-Bradley JM, Dukart G, Ellis-Grosse EJ. Serum, tissue and body fluid concentrations of tigecycline after a single 100 mg dose. *J Antimicrob Chemother* 2006;58:1221-9.
- De Pascale G, Montini L, Pennisi M, Bernini V, Maviglia R, Bello G, Spanu T, Tumbarello M, Antonelli M. High dose tigecycline in critically ill patients with severe infections due to multidrug-resistant bacteria. *Crit Care* 2014;18:R90.
- Bengtsson S, Bjelkenbrant C, Kahlmeter G. Validation of EUCAST zone diameter breakpoints against reference broth microdilution. *Clin Microbiol Infect* 2014;20:O353-60.
- Zhang Q, Zhou S, Zhou J. Tigecycline treatment causes a decrease in fibrinogen levels. *Antimicrob Agents Chemother* 2015;59:1650-5.
- Schafer JJ, Mangino JE. Multidrug-resistant *Acinetobacter baumannii* osteomyelitis from Iraq. *Emerg Infect Dis* 2008;14:512-4.
- Humphries RM, Kelesidis T, Dien Bard J, Ward KW, Bhat-tacharya D, Lewinski MA. Successful treatment of pan-resistant *Klebsiella pneumoniae* pneumonia and bacteraemia with a combination of high-dose tigecycline and colistin. *J Med Microbiol* 2010;59:1383-6.
- Cunha BA. Pharmacokinetic considerations regarding tigecycline for multidrug-resistant (MDR) *Klebsiella pneumoniae* or MDR *Acinetobacter baumannii* urosepsis. *J Clin Microbiol* 2009;47:1613.
- Ramirez J, Dartois N, Gandjini H, Yan JL, Korth-Bradley J, McGovern PC. Randomized phase 2 trial to evaluate the clinical efficacy of two high-dosage tigecycline regimens versus imipenem-cilastatin for treatment of hospital-acquired pneumonia. *Antimicrob Agents Chemother* 2013;57:1756-62.
- Falagas ME, Vardakas KZ, Tsiveriotis KP, Triarides NA, Tansarli GS. Effectiveness and safety of high-dose tigecycline-containing regimens for the treatment of severe bacterial infections. *Int J Antimicrob Agents* 2014;44:1-7.
- Trampuz A, Zimmerli W. Prosthetic joint infections: update in diagnosis and treatment. *Swiss Med Wkly* 2005;135:243-51.
- Jones RN. Disk diffusion susceptibility test development for the new glycylcycline, GAR-936. *Diagn Microbiol Infect Dis* 1999;35:249-52.
- Jones RN, Ferraro MJ, Reller LB, Schreckenberger PC, Swenson JM, Sader HS. Multicenter studies of tigecycline disk diffusion susceptibility results for *Acinetobacter* spp. *J Clin Microbiol* 2007;45:227-30.
- Beiler AM, Belknap RW, Dayton MR, Price CS, Morgan SJ. Eradication of multidrug-resistant *Acinetobacter bau-*

- mannii in a female patient with total hip arthroplasty, with debridement and retention: a case report. *J Med Case Rep* 2009;3:45.
19. Xie J, Wang T, Sun J, Chen S, Cai J, Zhang W, Dong H, Hu S, Zhang D, Wang X, Dong Y. Optimal tigecycline dosage regimen is urgently needed: results from a pharmacokinetic/pharmacodynamic analysis of tigecycline by Monte Carlo simulation *Int J Infect Dis* 2014;18:62-7.
20. Karani O, Charkoftaki G, Vryonis E, Skoutelis A, Markantonis S, Archontaki H, Dokoumetzidis A, Valsami G. Assessment of dosage regimens of tigecycline in hospitalised patients. Abstracts of the Annual Meeting of the Population Approach Group in Europe. 2011; 20:Abstr 2165.