

Disseminated Gonococcal Infection Presenting as Bacteremia and Liver Abscesses in a Healthy Adult

Min Hye Lee¹, Jongkyu Byun¹, Myounghwa Jung¹, John Jeongseok Yang², Ki-Ho Park¹, Soo-youn Moon¹, Hee Joo Lee², and Mi Suk Lee¹

Departments of ¹Internal Medicine, and ²Laboratory Medicine, Kyung Hee University School of Medicine, Seoul, Korea

Herein, we describe a bacteremia caused by *Neisseria gonorrhoeae* that presented as liver abscesses. The patient had no risk factors for disseminated gonococcal infection. Periodic fever, skin rashes, and papules were present and the results of an abdominal computed tomography scan indicated the presence of small liver abscesses. The results of blood culture and 16S rRNA sequencing of the bacterial isolates confirmed the presence of *N. gonorrhoeae*. The patient improved with antibiotic therapy.

Key Words: *Neisseria gonorrhoeae*; Liver abscesses; Disseminated gonococcal infection

Introduction

Gonorrhea is the second most commonly reported communicable disease in the United States, with an estimated incidence of more than 600,000 cases annually [1]. In Korea too, gonorrhea is the second most commonly reported sexually transmitted infection; 3,172 cases were registered by the Korean Centers for Disease Control & Prevention in 2007 [2]. Gonorrhea is usually characterized by cervicitis, urethritis, and pelvic inflammatory disease. Disseminated gonococcal infection (DGI) is an important mucosal infection caused by *Neisseria gonorrhoeae* but is rare. Classic DGI typically manifests as a combination of dermatitis, tenosynovitis, and migratory polyarthralgia, or as purulent arthritis without skin lesions. Endocarditis, meningitis, and osteomyelitis may also occur

but are rare [3]. Here, we report an atypical manifestation of DGI presenting as bacteremia and liver abscesses along with a literature review.

Case Report

A 31-year-old man was admitted to the hospital with periodic fever, skin rashes, and papules on hands, feet, and lower legs as well as pain on the left ankle for the past 20 days. His past medical history was unremarkable. He had been on a business trip to Baengnyeong-do 3 months before admission and had traveled to Tongyeong 1 month before admission. He presented with fever and sore throat 1.5 months before admission and received medication. He did not show any urogenital

Received: December 12, 2013 **Revised:** February 3, 2014 **Accepted:** February 18, 2014

Corresponding Author : Mi Suk Lee, MD

Division of Infectious Diseases, Department of Internal Medicine, Kyung Hee University School of Medicine, 23 Kyungheedaero, Dongdaemun-gu, Seoul 130-872, Korea

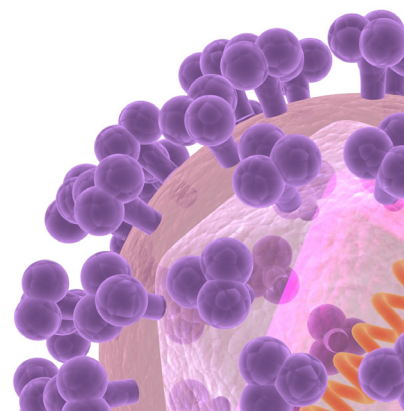
Tel: +82-2-958-1634, Fax: +82-2-968-1848

E-mail: mslee@khmc.or.kr

This is an Open Access article distributed under the terms of the Creative Commons Attribution Non-Commercial License (<http://creativecommons.org/licenses/by-nc/3.0>) which permits unrestricted non-commercial use, distribution, and reproduction in any medium, provided the original work is properly cited.

Copyrights © 2015 by The Korean Society of Infectious Diseases | Korean Society for Chemotherapy

www.icjournal.org



symptoms such as dysuria or urinary frequency. He was single and heterosexual, and his last sexual contact was 3.5 months before admission. The day before admission, he had visited a dermatologist, at which time a punch biopsy specimen was obtained from a skin lesion on the left sole.

On admission to the hospital, his body temperature was 38.3°C, blood pressure was 130/80 mmHg, pulse rate was 110 beats per minute, and respiratory rate was 20 breaths per minute. Upon physical examination, he seemed to be acutely ill with many hemorrhagic rashes and partly necrotic erythematous papules on both hands and feet (Fig. 1). His white blood cell count was 15,650/mm³ (neutrophil 84.0%), hemoglobin level was 11.5 g/dL, and platelet count was 81,000/mm³. The erythrocyte sedimentation rate was 94 mm/hour, and C-reactive protein level increased to 8.23 mg/dL. The liver function test results were as follows: aspartate aminotransferase, 24 IU/L (normal range, <40 IU/L); alanine aminotransferase, 34 IU/L (normal range, <40 IU/L); gamma-glutamyl transpeptidase, 82 IU/L (normal range, <50 IU/L); total bilirubin, 0.68 mg/dL (normal range, 0.2-1.1 mg/dL); and direct bilirubin, 0.20 mg/dL (normal range, <0.5 mg/dL). The results of a human immunodeficiency virus antibody test and rapid plasma reagin test were negative. Similarly, hepatitis A, hepatitis B, and hepatitis C serology test results were negative. Chest radiography showed no active lung lesion. Blood, urine, and stool samples were collected for culture. The patient was treated with empirically intravenous ceftriaxone at a dose of 2 g once a day.

On hospital day 2, for evaluation of the fever source, an abdominal computed tomography (CT) scan was performed and fever had subsided. The CT scan results indicated small-sized, low-attenuated lesions with enhancing wall in the liver, and these lesions were considered to be liver abscesses (Fig. 2). On hospital day 3, blood cultures revealed the presence of gram-negative diplococci. On hospital day 7, blood culture or-

ganisms were identified as *N. gonorrhoeae* using a conventional method. Sequencing of 16S rRNA of this isolate indicated the highest homology (99.9%) to the published sequence of *N. gonorrhoeae* strain NCTC 83785 (GenBank Accession No. NR-026079.1). This isolate was found to be intermediate-resistant to penicillin, resistant to ciprofloxacin and tetracycline, and susceptible to ceftriaxone, cefepime, and cefotaxime using the disk diffusion method.

Histopathology examination of the skin biopsy indicated chronic dermatitis. C3 and C4 complement levels were 125 mg/dL (normal range, 88-201 mg/dL) and 20.6 mg/dL (normal range, 16-47 mg/dL), respectively. Follow-up blood cul-

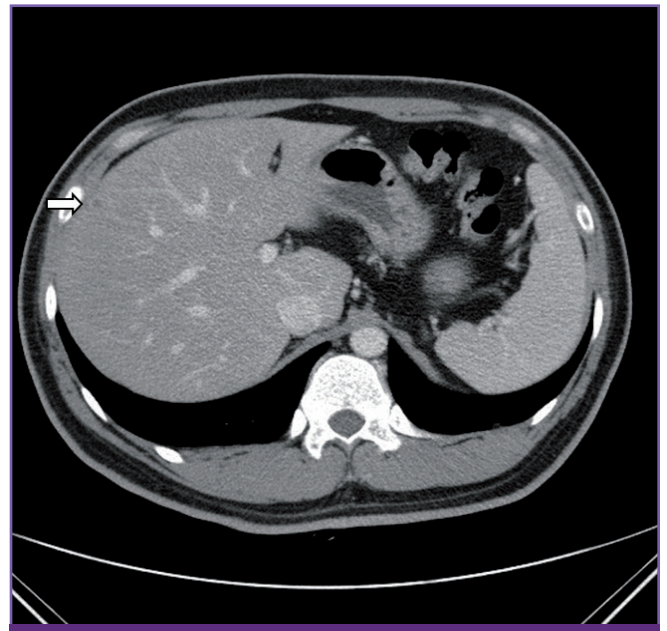


Figure 2. Results of the abdominal computed tomography scan performed on admission indicated a small low-attenuated lesion with enhancing wall (white arrow) in the liver, suggesting a liver abscess. The size of the liver abscess was approximately 8 mm.

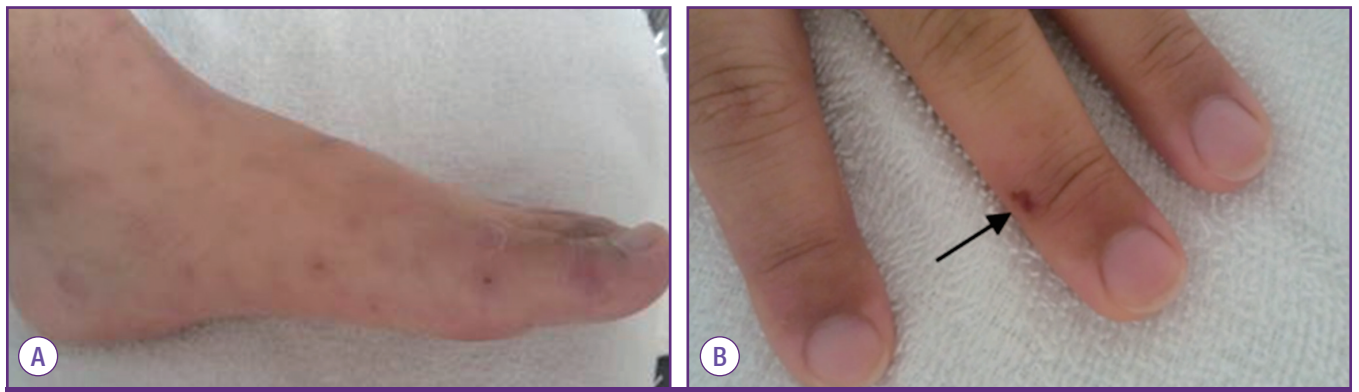


Figure 1. Skin examination results. (A) Many hemorrhagic rashes were noted on the foot. (B) Partly necrotic erythematous papule on the finger (black arrow).

ture was performed before discharge. After 8 days in the hospital, the patient's clinical status was better and he was discharged and prescribed oral cefixime 200 mg twice a day for 2 weeks.

After 2 weeks, the patient visited the outpatient clinic of the infectious disease department. Follow-up blood cultures confirmed the absence of bacterial growth. However, he complained of sweating, pelvic pain, and mild fever (37.5°C); therefore, he was prescribed oral cefixime 200 mg twice a day for 1 week. Three weeks after hospital discharge, his symptoms were resolved and he no longer received antibiotic therapy. The follow-up abdominal CT scan examination after 4 weeks of therapy showed the absence of liver abscesses.

Discussion

DGI results from the bacteremic dissemination of *N. gonorrhoeae* and affects 1–3% of patients with gonorrhea [4–10]. In the Korean population, DGI is quite rare, and only 3 cases have been reported to date. In 2004, Kim *et al.* [11] reported a case of DGI concomitant with acute viral hepatitis C. Kim *et al.* [12] reported a case of DGI presenting as Sweet syndrome and Won *et al.* reported the first case of *N. gonorrhoeae* bacteremia in a 42-year-old man who had hepatitis B virus-associated liver cirrhosis with massive variceal hemorrhage [13]. DGI is usually characterized by dermatitis, tenosynovitis, and septic arthritis and rarely by endocarditis, meningitis, and osteomyelitis [11]. The pathogenesis of DGI is associated with both microbial and host factors [14]. The host risk factors for DGI include female gender, pregnancy, menses, asymptomatic

mucosal infection, multiple sexual partners, low socio-economic status, intravenous drug use, complement deficiency, HIV infection, and systemic lupus erythematosus [15, 16]. In addition, certain strains of *N. gonorrhoeae* (ex. Protein 1A serotype, those lacking protein II, and arginine-hypoxanthine-uracil strains) that are prone to cause disseminated infection differ biochemically from more common strains that cause urethral complications; in addition, they are less potent stimulators of inflammatory responses and are less likely to cause symptomatic urethral infections [15]. In this report, microbial factors may have had an important role in the development of DGI because the patient was immunocompetent and had no risk factors for DGI. However, we did not perform further phenotypic or serologic characterization of this isolate.

The antimicrobial susceptibility of *N. gonorrhoeae* isolated from Korea in 2013 is shown in Table 1 [17].

The incubation period of *N. gonorrhoeae* varies between 1 and 14 days (usually 2–5 days) [18], and hematogenous spread typically occurs within 2–3 weeks of the primary infection [19]. In the case reported herein, the patient's last sexual contact was 3.5 months before admission and symptoms included fever and sore throat approximately 2 months after the last sexual contact. Thus, the incubation period was long but the reason for the long incubation period was unknown. Patients with DGI usually have no urogenital symptoms but do have a history of past venereal infection. It was difficult to identify the causative agent of liver abscesses in this case because they were too small to drain. Therefore, the diagnosis was supported by the evaluation of sexual contact history, clinical symptoms, and bacteremia caused by *N. gonorrhoeae*.

To the best of our knowledge, this is the first DGI case that

Table 1. Antimicrobial susceptibility of *Neisseria gonorrhoeae* isolates evaluated by disk diffusion [17]

Antimicrobial agents (Dosage)	% of isolates with (N = 60)			
	Susceptible	Intermediate	Not susceptible	Resistant
Penicillin G (10 U)	0	42		58
Spectinomycin (100 g)	100	0		0
Ceftriaxone (0.5 µg)	50		50	
Ceftriaxone (30 µg)	75		25	
Cefixime (5 µg)	75		25	
Cefpodoxime (10 µg)	82		18	
Cefotaxime (30 µg)	70		30	
Tetracycline (30 µg)	0	5		95
Ciprofloxacin (5 µg)	5	2		93
Nalidixic acid (30 µg)	7		93	
Azithromycin (15 µg)	98		2	

presented as liver abscess complications. We performed a literature search to identify previously reported cases of liver abscess caused by *N. gonorrhoeae* but did not find any case. In general, DGI does not involve abdominal symptoms or signs, and therefore an abdominal CT scan was not necessary in the routine evaluation. Therefore, abdominal complications may occur in the rare cases of liver abscess caused by *N. gonorrhoeae*. In this regard, in Taiwan, Chung *et al.* [20] reported the case of a diabetic man with liver abscess due to *N. sicca* after repeated transcatheter arterial embolization for hepatocellular carcinoma.

In summary, this is the first case of bacteremia with liver abscess caused by *N. gonorrhoeae* in a young healthy man who had no risk factors for DGI. The patient was successfully treated with 2 g of intravenous ceftriaxone daily for 1 week, followed by 200 mg of oral cefixime twice a day for 3 weeks. Further data will be needed to confirm the involvement of *N. gonorrhoeae* in the development of liver abscesses.

ORCID

Min Hye Lee	http://orcid.org/0000-0002-8575-5490
Myounghwa Jung	http://orcid.org/0000-0003-4431-4063
Ki-Ho Park	http://orcid.org/0000-0003-0000-9016
Soo-youn Moon	http://orcid.org/0000-0002-4662-7859
Hee Joo Lee	http://orcid.org/0000-0002-5527-7125
Mi Suk Lee	http://orcid.org/0000-0001-8951-5032

References

1. Bolan GA, Sparling PF, Wasserheit JN. The emerging threat of untreatable gonococcal infection. *N Engl J Med* 2012;366:485-7.
2. Korean Centers for Disease Control & Prevention. Surveillance system and current status of sexually transmitted infections in Korea. *Public Health Wkly Rep* 2008;1:429-33.
3. Suzaki A, Hayashi K, Kosuge K, Soma M, Hayakawa S. Disseminated gonococcal infection in Japan: a case report and literature review. *Intern Med* 2011;50:2039-43.
4. Al-Suleiman SA, Grimes EM, Jonas HS. Disseminated gonococcal infections. *Obstet Gynecol* 1983;61:48-51.
5. Belding ME, Carbone J. Gonococcemia associated with adult respiratory distress syndrome. *Rev Infect Dis* 1991;13:1105-7.
6. Eisenstein BI, Masi AT. Disseminated gonococcal infection (DGI) and gonococcal arthritis (GCA): I. Bacteriology, epidemiology, host factors, pathogen factors, and pathology. *Semin Arthritis Rheum* 1981;10:155-72.
7. Kerle KK, Mascola JR, Miller TA. Disseminated gonococcal infection. *Am Fam Physician* 1992;45:209-14.
8. Owino NO, Goldmeier D, Wall RA. Gonococcal septicaemia presenting as a subcutaneous abscess. *Br J Vener Dis* 1981;57:143-4.
9. Jain S, Win HN, Chalam V, Yee L. Disseminated gonococcal infection presenting as vasculitis: a case report. *J Clin Pathol* 2007;60:90-1.
10. Morse SA, Holmes KK. Gonococcal infections. In: Hoeprich PD, Jordan MC, Ronald AR, eds. *Infectious diseases*. 5th ed. New York: Harper and Row; 1994:670-85.
11. Kim GC, Lee CH, Lee JS, Chung MH, Choi JH, Moon YS. A case of concomitant disseminated gonococcal infection with acute viral hepatitis C. *Infect Chemother* 2004;36:175-80.
12. Kim JW, Song R, Im CH, Kim JH, Lee EY, Lee EB, Song YW. Disseminated gonococcal infection presenting as sweet syndrome. *Korean J Med* 2011;80:486-9.
13. Won D, An D, Kim MN, Lee YS. A case of bacteremia by *Neisseria gonorrhoeae* coincident with massive hemorrhage of esophageal varices. *Korean J Lab Med* 2011;31:118-21.
14. Dal Conte I, Starnino S, Di Perri G, Stefanelli P. Disseminated gonococcal infection in an immunocompetent patient caused by an imported *Neisseria gonorrhoeae* multidrug-resistant strain. *J Clin Microbiol* 2006;44:3833-4.
15. Bardin T. Gonococcal arthritis. *Best Pract Res Clin Rheumatol* 2003;17:201-8.
16. Cannon JG, Buchanan TM, Sparling PF. Confirmation of association of protein I serotype of *Neisseria gonorrhoeae* with ability to cause disseminated infection. *Infect Immun* 1983;40:816-9.
17. Kim HJ, Seo Y, Kim WH, Lee Y, Lee H, Lee K, Chong Y. Antimicrobial resistance and molecular epidemiologic characteristics of *Neisseria gonorrhoeae* isolated from Korea in 2013. *Ann Clin Microbiol* 2013;16:182-7.
18. Ghosn SH, Kibbi AG. Cutaneous gonococcal infections. *Clin Dermatol* 2004;22:476-80.
19. Brown TJ, Yen-Moore A, Tyring SK. An overview of sexually transmitted diseases. Part I. *J Am Acad Dermatol* 1999;41:511-32.
20. Chung HC, Teng LJ, Hsueh PR. Liver abscess due to *Neisseria sicca* after repeated transcatheter arterial embolization. *J Med Microbiol* 2007;56:1561-2.