

심미보철 수복을 위한 3차원 안면스캔과 가상 보철물 시각화를 이용한 디지털 치료 증례

마이해엔¹ · 최용도¹ · 이두형^{1,2*}

¹경북대학교 치과대학 치과보철학교실, ²경북대학교 치의학중개연구소

Digital approach integrating 3D facial scan and a virtual mockup for esthetic restorative treatment: A case report

Hai Yen Mai¹, Yong-Do Choi¹, Du-Hyeong Lee^{1,2*}

¹Department of Prosthodontics, School of Dentistry, Kyungpook National University, Daegu, Republic of Korea

²Institute for Translational Research in Dentistry, Kyungpook National University, Daegu, Republic of Korea

This clinical case report describes the digital workflow that combines a face scan, cone beam computed tomography and an intraoral scan to visualize the outcome of prosthodontic treatment in the anterior region. This approach improves communication between clinic, laboratory and patients. A patient with healthy general condition came for a restorative treatment to treat post-traumatic central incisors of maxilla. A virtual patient replica was made by incorporating a face scan, cone beam computed tomography and an intraoral scan. Design mockup of definitive restorations was shown to the patient and modified according to the patient's desire. This digital workflow facilitates the fabrication of optimal esthetic restorations, and enhances the predictability of outcome of restorations. (*J Korean Acad Prosthodont* 2019;57:425-31)

Keywords: Digital workflow; Face scan; Cone-beam computed tomography; Intraoral scan; Image merging; Visualization

Introduction

Digital workflow has increased recently in dentistry and contributed to the improvement of all dental treatments. Digital techniques strengthen diagnostic visualization and predictability of the prosthetic treatments, and improve the information exchange between patients, doctors and technicians.^{1,2} The fundamental steps of a digital workflow are data acquisition, data processing, computer-aided design (CAD), and computer-aided manufacturing (CAM).³⁻⁶ Three-

dimensional (3D) digital image data in dentistry can be obtained from a range of different sources including computed tomography, magnetic resonance imaging, extra-oral optical scanning, and intra-oral optical scanning. The use of digitalized scanners minimized human manipulation, reducing inaccuracy and time for the fabrication of restorations.^{7,8} Furthermore, previous studies have reported high dimensional accuracy of digital casts compared with stone casts.⁹⁻¹¹ Dental restorations fabricated from digital scans exhibited similar or even better marginal and internal discrepancies to those fabricated

*Corresponding Author: Du-Hyeong Lee

Department of Prosthodontics, School of Dentistry, Institute for Translational Research in Dentistry, Kyungpook National University, 2175 Dalgubeol-daero, Jung-gu, Daegu 41940, Republic of Korea

+82 (0)53 600 7651: e-mail, deweylee@knu.ac.kr

Article history: Received June 12, 2019 / Last Revision July 1, 2019 / Accepted July 10, 2019

※This research was supported by the technology transfer and commercialization Program through INNOPOLIS Foundation funded by the Ministry of Science and ICT (2018-DG-RD-0002-01-201).

©2019 The Korean Academy of Prosthodontics

©This is an Open Access article distributed under the terms of the Creative Commons Attribution Non-Commercial License (<http://creativecommons.org/licenses/by-nc/4.0>) which permits unrestricted non-commercial use, distribution, and reproduction in any medium, provided the original work is properly cited.

from conventional impressions.^{12,13}

A fundamental issue with restorative treatments is the unpredictability of esthetic outcomes due to the incapacity to have direct preceding clinical method.¹⁴ Therefore, the definitive restorations are modified in clinic or remade additionally, which increases overall treatment time and charge. Advancements in stereo-photogrammetric facial scanning technology have led to the development of 3D visualization of the orofacial region.¹⁵ These systems have been successfully employed to create a virtual patient replica for comprehensive diagnosis and treatment planning in orthodontics and orthognathic surgery.^{16,17} More recently, the concept of applying facial scanning for esthetic analysis during the design phase of dental restorations has been introduced in prosthodontics.¹⁸ The main idea is to integrate a virtual teeth setup with a replica of the patient face and to digitally evaluate the impact of changing teeth positions, forms, and colors on facial appearance. The 3D design information obtained from this virtual clinical evaluation phase can then be used to fabricate mockups or provisional restorations. A virtual setup phase might be a good option to provide the patient and the treatment provider with a tool regarding the facial appearance of the prospective definitive restoration. The purpose of this clinical case is to propose a digital approach integrating 3D facial scanning, a virtual mockup and direct conversion of design to definitive restoration in the workflow of a restorative treatment.

Case report

A 39-years-old male patient came for esthetic treatment for maxillary central incisors. The extraoral examination showed no deviation in the facial and dental midlines. The patient had a medium lip line, concave smile line, and 1 mm of tooth visibility at rest. The intra-oral examination presented acceptable oral health with periodontal probing depths of no more than 3 mm but a generalized moderate

periodontitis at posterior regions at both maxilla and mandibular with probing depths varying from 3 to 4 mm and localized gingival recession. The two traumatized central maxillary incisors had been restored with composite, and showed restorative materials with defective margins and poor color match to the adjacent teeth. Some of the occlusion surfaces of posterior teeth had also been filled with amalgam material with adequate marginal integrity without color infiltration. The occlusal plane was not altered. The two central maxillary incisors were indicated to be restored with a laminate veneer on #11 tooth and a monolithic zirconia crown on #21 tooth and chosen using the stepwise procedure with a virtual mock-up on 3D face scan to increase the esthetic results.

First, 3D facial scanning was taken to create a virtual patient replica for the clinical evaluation phase (Fig. 1A). Using a come-beam computed tomography (CBCT)-scan device (R2 STUDIO, MegaGen, Daegu, Korea), maximum smile facial scans were obtained at 3 different angulations (frontal, 80-degree right side, 80-degree left side) with the Frankfort horizontal plane of head to be parallel to the floor. The obtained data was saved in the form of object (OBJ) format. The underlying bone morphology was obtained by using the CBCT-scan device with a field of view of 120 × 85 mm, voxel size of 0.2 mm, exposure conditions of 80 kVp, 8 mA, and a 24-s pulsed scan (Fig. 1B). Data were saved in the digital imaging and communications in medicine (DICOM) format. While taking the CBCT, a face scan was taken simultaneously (Scout image).

The teeth #11 was prepared to receive a laminate veneer on the labial surface and #21 was prepared for a crown, then the maxillary and mandibular dental impression were taken with an additional type silicone impression material (Virtual, Ivoclar Vivadent, Schaan, Liechtenstein). The cast was made with type IV dental stone. Then, the cast models were submitted to a 3D scanning procedure using a desktop scanner (IDC S1, Amann Girrbach, Koblach, Germany) (Fig. 1C). The scanned models were subsequently saved as standard tes-

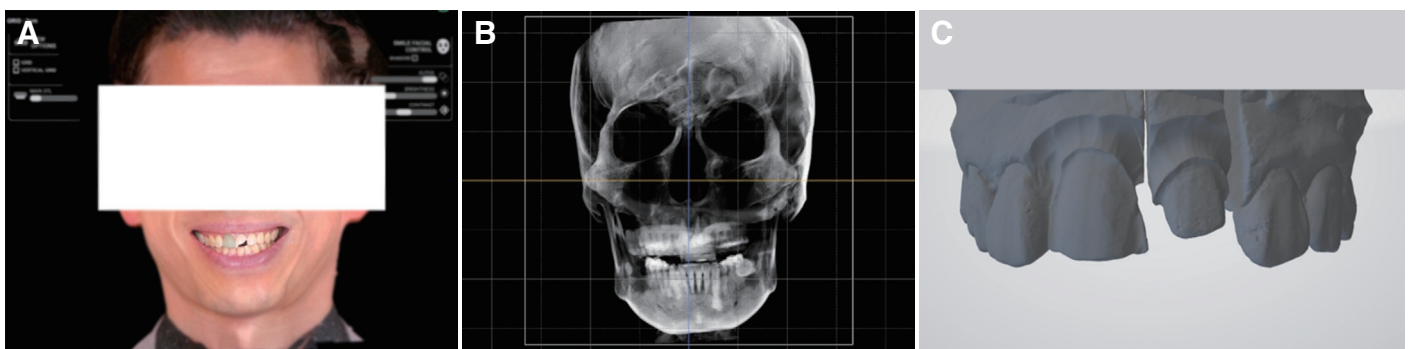


Fig. 1. (A) 3D facial scan image, (B) Cone-beam computed tomography image, (C) Optical scan image of master cast.

sellation language (STL) file.

Afterward, all digital files were imported into a dental design software program (R2GATE v2.0, MegaGen, Daegu, Korea) The DICOM data of CBCT was converted to 3D reconstructed mesh format (Fig. 2), and the facial scan and mesh data were aligned to each other

using the outlines of Scout image (Fig. 3). This was necessary in order to bring all facial scans in a single corresponding coordinate system. To combine the intraoral scan image to CBCT, remaining teeth were used as fixed anatomical reference (Fig. 4). Using this stepwise method, OBJ, DICOM and STL files were linked.

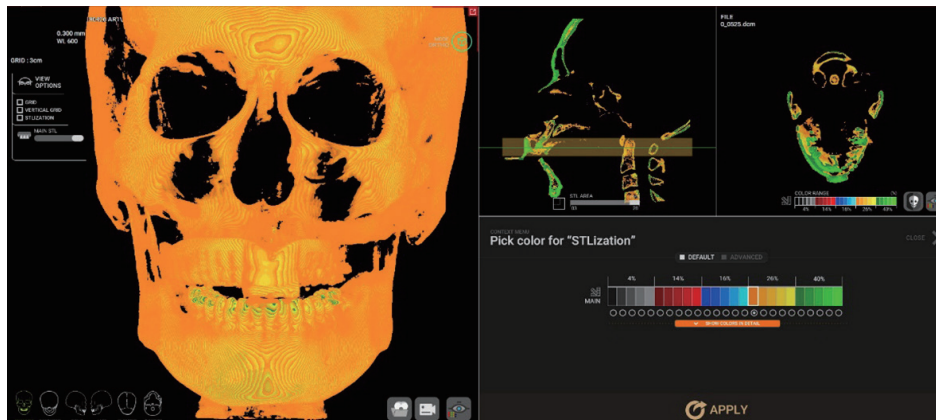


Fig. 2. Image conversion from DICOM format to 3D mesh format.

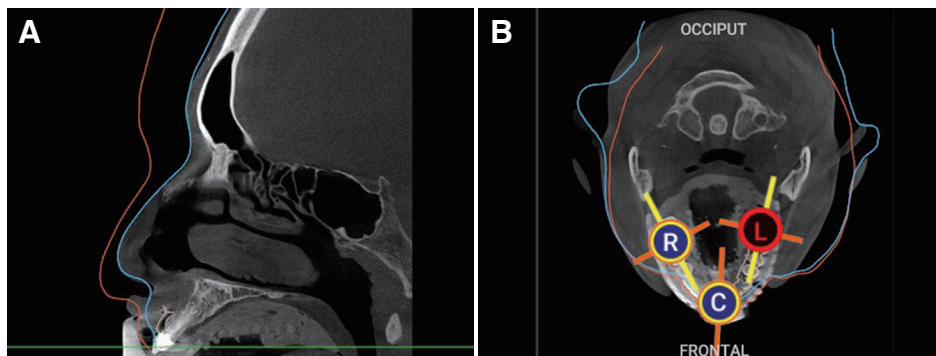


Fig. 3. Image merging of face scan and computed tomography images using Scout image. (A) Sagittal view, (B) Horizontal view.

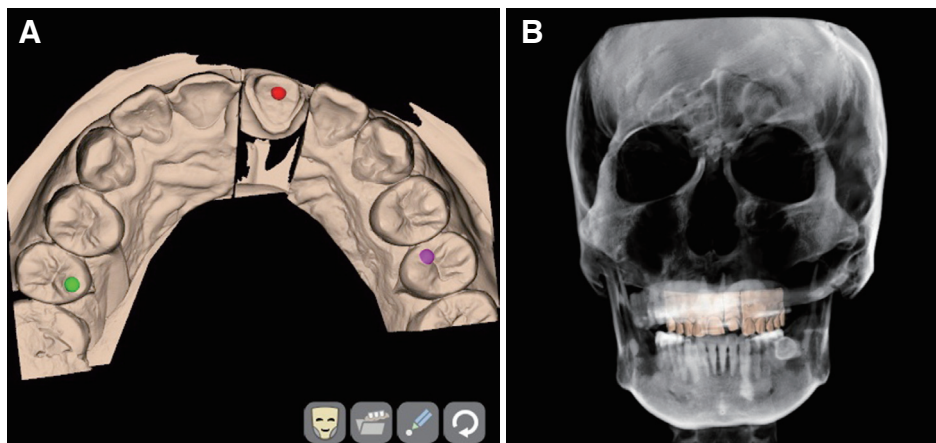


Fig. 4. Image merging of computed tomography and intraoral scan images using remaining teeth. (A) Intraoral scan image, (B) Matched scan image on computed tomography.

Based on the merged image, the restorations of laminate and complete crown were designed under consideration of the patient smile and esthetics lines using Digital Oral Design module in R2Gate (MegaGen, Daegue, Korea) (Fig. 5). The designed restoration was shown to the patient in clinic as a virtual mock-up on a 3D face scan of the patient to get the patient's feedback. The designed virtual restorations were transfer to CAD software (R2CAD, MegaGen, Daegu, Korea), and revised based on the patient's feedback in collaboration with the dentist professional considerations. The confirmed design was exported to a 5-axis milling machine (Ceramill Motion 2, Amann Girrbach, Koblach, Germany) to produce the definitive restorations using a hybrid ceramic block (VITA Enamic, Amann Girrbach, Koblach, Germany) for the laminate veneer and a zirconia block (Zolid fx white, Amann Girrbach, Koblach, Germany) for the complete crown. The definitive restorations were delivered to the patient, and the patient was satisfied with the predictability of treatment workflow and esthetics of the restorations (Fig. 6).



Fig. 5. Restoration mockup image in face scan image.

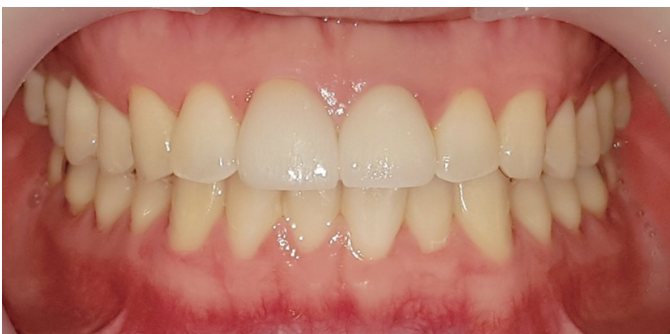

Fig. 6. Delivery of definitive restorations.

Discussion

Scientific revolution of the clinical procedures and technical methods used to rehabilitate oral defects of patients are currently ongoing.¹⁹ It could be challenging to meet individual esthetics and functions of patient, which led to digital advances in prosthodontic treatments. Currently, various CAD/CAM technologies are available during treatment plan, design, fabrication treatments phases of fixed and removable implant prostheses. The soft tissue analyses obtained by 3D facial scanning are certainly an optimal supplement to the existing scanning technologies.^{20,21} All pictorial information obtained by intra- and extra-oral scanners with the assistance of facial scanner facilitates the restoration design to reflect the esthetic demands of the patient.²² That would be beneficial to both the patient and clinician.

A virtual teeth setup allows several rapid adjustments of tooth size/position and generalized modifications of the occlusal scheme and compensation curves of the dental arch.²³ This procedure would require a lot of manual labor, time, and cost in a traditional wax-up method. Additionally, the virtual setup is digitally stored and thus can be consecutively used to fabricate a new prosthesis, thereby reducing treatment time. Integrating virtual teeth setup with the facial scan permits immediate inspection of the prosthesis considering facial esthetics.²⁴ Similarly, tooth position and morphology can be altered while visualizing the impact on the patient's facial appearance. This would definitely improve on the current clinical procedure of multiple esthetic teeth try-ins that typically required for comprehensive reconstructions and treatments at anterior region. Moreover, the use of this digital approach improves communication between clinicians and lab technicians. A technician, who is usually limited to the wax-up on the articulator and selected photographs of the patient, would benefit from this virtual setup, in which changes in the restoration design can immediately be visualized on the patient's face.

Nowadays, two-dimensional (2D) virtual smile design approach is still gaining a reputation as a conceptual tool to improve communication within related parts and to enhance treatment predictability.²⁰ However, perspective distortion may cause inaccuracies or errors in the conversion process from 2D design to 3D diagnostic waxing.^{20,25} In 3D methods, definitive restorations can be directly fabricated from an approved virtual diagnostic wax-up without the need for further conversion after the confirmation of simulated esthetic outcome in the 3D virtual patient. Accordingly, the use of a 3D virtual patient can overcome the limitation of 2D methods.

There are several considerations for the clinical use of the present workflow. First, the alignment of the dental cast models and the facial scans depends on the visibility of the labial surfaces of the teeth as a common fixed reference. Because the intraoral scan needs to be merged with the virtual patient using the remaining teeth, the vis-

ibility of the labial surface of the remaining dentition at a full smile is important.^{26,27}

Furthermore, some inaccuracies in image margining might be generated in case the remaining teeth are insufficient. Alternatively, an additional radiopaque tray can be applied during face scan and CBCT taking. The extraoral portion of the tray in deed can be used as a congruent area for the image superimposition. Additionally, alignment of the neutral smile and full smile scans rely on the stability of the forehead as a reference. In patients with deep facial corrugations, this region can deform when the patient is smiling thereby hampering an accurate registration procedure. The clinician should also verify that the patient's facial expression and head positioning are consistent when collecting facial scans to improve the accuracy of the registration procedure for the virtual patient.^{26,27}

The digital technologies of face scan and image merging for 3D diagnosis and esthetic treatment are promising, but are still at inceptive stages for the practical applications in prosthodontics. More scientific trials are needed for more scientific evidence to explore the possibilities.

Conclusion

This clinical report describes a digital treatment workflow based on the combination of face and oral cavity scans to create a 3D virtual patient for the clinical and laboratory phases of an esthetic treatment with a laminate veneer and a monolithic zirconia crown in the anterior region. Within the limit of this report, the digital workflow has the potential to enhance the predictability of esthetic outcomes.

ORCID

Hai Yen Mai <https://orcid.org/0000-0002-9604-5267>

Yong-Do Choi <https://orcid.org/0000-0001-9098-9104>

Du-Hyeong Lee <https://orcid.org/0000-0003-2803-7457>

References

1. Joda T, Zarone F, Ferrari M. The complete digital workflow in fixed prosthodontics: a systematic review. *BMC Oral Health* 2017;17:124.
2. Zhou Q, Wang Z, Chen J, Song J, Chen L, Lu Y. Development and evaluation of a digital dental modeling method based on grating projection and reverse engineering software. *J Prosthet Dent* 2016;115:42-6.
3. Bhargav A, Sanjairaj V, Rosa V, Feng LW, Fuh Yh J. Applications of additive manufacturing in dentistry: A review. *J Biomed Mater Res B Appl Biomater* 2018;106:2058-64.
4. Koch GK, Gallucci GO, Lee SJ. Accuracy in the digital workflow: From data acquisition to the digitally milled cast. *J*

- Prosthet Dent* 2016;115:749-54.
5. van Noort R. The future of dental devices is digital. *Dent Mater* 2012;28:3-12.
6. Young JM, Altschuler BR. Laser holography in dentistry. *J Prosthet Dent* 1977;38:216-25.
7. Christensen GJ. Impressions are changing: deciding on conventional, digital or digital plus in-office milling. *J Am Dent Assoc* 2009;140:1301-4.
8. Mangano F, Gandolfi A, Luongo G, Logozzo S. Intraoral scanners in dentistry: a review of the current literature. *BMC Oral Health* 2017;17:149.
9. Aragón ML, Pontes LF, Bichara LM, Flores-Mir C, Normando D. Validity and reliability of intraoral scanners compared to conventional gypsum models measurements: a systematic review. *Eur J Orthod* 2016;38:429-34.
10. Ender A, Mehl A. In-vitro evaluation of the accuracy of conventional and digital methods of obtaining full-arch dental impressions. *Quintessence Int* 2015;46:9-17.
11. Goracci C, Franchi L, Vichi A, Ferrari M. Accuracy, reliability, and efficiency of intraoral scanners for full-arch impressions: a systematic review of the clinical evidence. *Eur J Orthod* 2016;38:422-8.
12. Budak I, Vukelić D, Bračun D, Hodolić J, Soković M. Pre-processing of point-data from contact and optical 3D digitization sensors. *Sensors (Basel)* 2012;12:1100-26.
13. Chochlidakis KM, Papaspyridakos P, Geminiani A, Chen CJ, Feng JJ, Ercoli C. Digital versus conventional impressions for fixed prosthodontics: A systematic review and meta-analysis. *J Prosthet Dent* 2016;116:184-90.
14. Kattadiyil MT, Jekki R, Goodacre CJ, Baba NZ. Comparison of treatment outcomes in digital and conventional complete removable dental prosthesis fabrications in a predoctoral setting. *J Prosthet Dent* 2015;114:818-25.
15. Farahani N, Braun A, Jutt D, Huffman T, Reder N, Liu Z, Yagi Y, Pantanowitz L. Three-dimensional Imaging and Scanning: Current and Future Applications for Pathology. *J Pathol Inform* 2017;8:36.
16. Da Silveira AC, Daw JL Jr, Kusnoto B, Evans C, Cohen M. Craniofacial applications of three-dimensional laser surface scanning. *J Craniofac Surg* 2003;14:449-56.
17. Mankovich NJ, Samson D, Pratt W, Lew D, Beumer J 3rd. Surgical planning using three-dimensional imaging and computer modeling. *Otolaryngol Clin North Am* 1994;27:875-89.
18. Cattoni F, Mastrangelo F, Gherlone EF, Gastaldi G. A new total digital smile planning technique (3D-DSP) to fabricate CAD-CAM mockups for esthetic crowns and veneers. *Int J Dent* 2016;2016:6282587.
19. Sorensen JA. The evolution and revolution in prosthodontics continues. *Compend Contin Educ Dent* 2016;37:402-4.
20. Lin WS, Zandinejad A, Metz MJ, Harris BT, Morton D. Predictable restorative work flow for computer-aided design/computer-aided manufacture-fabricated ceramic veneers utilizing a virtual smile design principle. *Oper Dent*

- 2015;40:357-63.
21. Liu X, Liu J, Mao H, Tan J. A digital technique for replicating peri-implant soft tissue contours and the emergence profile. *J Prosthet Dent* 2017;118:264-7.
22. Abduo J, Bennamoun M, Tennant M, McGeachie J. Impact of digital prosthodontic planning on dental esthetics: Biometric analysis of esthetic parameters. *J Prosthet Dent* 2016;115:57-64.
23. Im J, Cha JY, Lee KJ, Yu HS, Hwang CJ. Comparison of virtual and manual tooth setups with digital and plaster models in extraction cases. *Am J Orthod Dentofacial Orthop* 2014;145:434-42.
24. Hassan B, Gimenez Gonzalez B, Tahmaseb A, Greven M, Wismeijer D. A digital approach integrating facial scanning in a CAD-CAM workflow for complete-mouth implant-supported rehabilitation of patients with edentulism: A pilot clinical study. *J Prosthet Dent* 2017;117:486-92.
25. Pimentel W, Teixeira ML, Costa PP, Jorge MZ, Tioosi R. Predictable outcomes with porcelain laminate veneers: A clinical report. *J Prosthodont* 2016;25:335-40.
26. Edelhoff D, Liebermann A, Beuer F, Stimmelmayer M, Güth JF. Minimally invasive treatment options in fixed prosthodontics. *Quintessence Int* 2016;47:207-16.
27. Zimmermann M, Mehl A. Virtual smile design systems: a current review. *Int J Comput Dent* 2015;18:303-17.

심미보철 수복을 위한 3차원 안면스캔과 가상 보철물 시각화를 이용한 디지털 치료 종례

마이해엔¹ · 최용도¹ · 이두형^{1,2*}

¹경북대학교 치과대학 치과보철학교실, ²경북대학교 치의학중개연구소

본 임상종례는 전치부 영역에서 안면영상, 콘빔 컴퓨터 단층촬영 그리고 구내 스캔영상을 이용하여 보철물을 시각화하는 과정을 보여준다. 이러한 접근 방식은 임상과 기공 그리고 환자 측과의 소통을 향상시킨다. 환자가 상악 중절치의 외상 후 보철치료를 위해 내원하였고, 전신 건강 상태는 양호하였다. 안면영상, 콘빔 컴퓨터 단층촬영 그리고 구내 스캔영상을 이용하여 가상 환자 모형을 제작하였다. 최종 보철물의 제작 전 보철물 디자인 영상이 환자에게 제시되었고, 환자의 의견을 반영하여 형태를 수정하였다. 이러한 디지털 작업 과정은 최적의 심미 보철물의 제작을 용이하게 하고, 보철물의 예측성을 향상시킨다. (대한치과보철학회지 2019;57:425-31)

주요단어: 디지털 작업과정; 안면스캔; 콘빔 전산화 단층촬영; 구내스캔; 영상병합; 시각화

*교신저자: 이두형

41940 대구 중구 달구벌대로 2175 경북대학교 치과대학 치과보철학교실

053 600 7651; e-mail, deweylee@knu.ac.kr

원고접수일: 2019년 6월 12일 / 원고최종수정일: 2019년 7월 1일 / 원고채택일: 2019년 7월

10일

© 2019 대한치과보철학회

© 이 글은 크리에이티브 커먼즈 코리아 저작자표시-비영리 4.0 대한민국 라이선스에 따라
이용하실 수 있습니다.

※ 이 논문은 과학기술정보통신부의 재원으로 연구개발특구진흥재단-기술이전사업화 사업의 지원을 받아 수행된 연구임(2018-DG-RD-0002-01-201).