

Radiation Therapy for Heterotopic Ossification in a Patient with Traumatic Brain Injury

Sung Ho Jang¹, Sei Won Shin², Sang Ho Ahn¹, In Ho Cho³, and Sung Ho Kim⁴

Abstract

Radiation therapy has been known to have a prophylactic effect for heterotopic ossification (HO), but until now it has not been known to have a therapeutic effect for established HO. We report a case of established HO compounded with a sudden increase in activity, that was improved with radiation therapy. A patient with traumatic brain injury had HO in both hips and thighs two months after the initial trauma. The existing level of HO activity suddenly increased seven months after the initial trauma, and was accompanied by severe pain that was refractory to indomethacin. We assumed that the pain was caused by the increased activity of HO on the basis of clinical symptoms and laboratory results. Initially, the patient received radiation therapy to the left lower extremity, with a total dose of 20 Gy in ten fractions. Next, the patient received radiation therapy at the same dosage to the right lower extremity, after which the pain and level of serum alkaline phosphatase significantly decreased. The patient experienced a mild pancytopenia as a side effect of the radiation therapy, but it was not severe enough to stop the radiation therapy, given the patient's suffering from the increased HO activity.

Key Words: Heterotopic ossification, radiation therapy, traumatic brain injury

INTRODUCTION

When heterotopic ossification (HO) is accompanied by severe pain or ankylosis in the main joints, it can represent a significant limitation for the success of rehabilitative management. Therefore, the proper treatment of HO is very important for a successful rehabilitation. The current treatment methods for HO include medication, operation and radiation therapy.¹⁻³ When the pain caused by the sudden increase in HO activity is refractory to medication, there are no special methods to alleviate the pain other than radiation therapy. Radiation therapy has been accepted as having a prophylactic effect for the prevention of HO,^{2,4,5} but there have been few reports about the therapeutic effect on established HO.⁶ In a patient with a traumatic brain injury, severe pain that was refractory to indomethacin resulted from the sudden

increase in activity of the established HO. The patient in this case experienced a reduction in both pain and the level of increased HO activity.

CASE REPORT

The patient was a 26-year-old man with an epidural hematoma in the right fronto-parietal area caused by a motorcycle accident. His operation had consisted of a craniectomy and the removal of the hematoma at the department of neurosurgery at a university hospital in Taegu, Korea. Severe HO occurred began at both the hip joints and the thighs two months after the initial trauma, during which time he had been taking 1200 mg of oral etidronate disodium daily. The patient was transferred to our inpatient rehabilitation unit approximately seven months after the initial trauma. At that time, he had near total ankylosis, and the passive range of motion was limited, with right hip flexion 30°, abduction 20°, external rotation 30°, left hip flexion 30°, abduction 40°, external rotation 30°, right knee flexion 20°, and left knee flexion 30°. The spasticity in his knee and ankle joints was determined to be grade 3–4 on the modified Ashworth's scale. His functional level was a bed ridden state.

Received March 7, 2000

Accepted May 4, 2000

Departments of ¹Rehabilitation Medicine, ²Therapeutic Radiology and Oncology, ³Nuclear Medicine, ⁴Neurosurgery, Yeungnam University College of Medicine, Taegu, Korea.

Address reprint request to Dr. S. H. Jang, Department of Physical Medicine & Rehabilitation School of Medicine, Yeungnam University, 317-1, Daemyungdong, Namku, Taegu 705-717, Korea. Tel: 82-53-620-3269, Fax: 82-53-625-3508, E-mail: belado@medical.yeungnam.ac.kr

Starting the day after being transferred, the patient complained of severe pain in both lower extremities, especially both hip joint areas. Erythema, heating sensation and swelling were found at the left inguinal area and proximal thigh. His serum alkaline phosphatase level was 368 U/L (normal range: 80–270), compared with a value of 343 U/L drawn two weeks before the onset of pain. The Erythrocyte Sedimentation rate, level of C-Reactive protein and calcium were 65 mm/H (normal range: <20), 7.7 mg/dL (normal range: <0.5), and 8.1 mg/dL (normal range: 8.6–10.6), respectively.

A Plane X-ray revealed HO at both hip joint areas, the entire right thigh and left upper thigh (Fig. 1). There was no interval change compared to the previous plane X-ray. Although the patient was given 100 mg of oral indomethacin daily, the pain in both lower extremities continued to become further aggravated over time. His indomethacin dose was increased to 150 mg daily, but he was unable to sleep through the night because of the pain. In addition, he could not undergo physical nor occupational therapy. Given a visual analogue scale with which to rate the pain, he indicated a score of ten, but it could not be considered very accurate due to mild cognitive dysfunction.

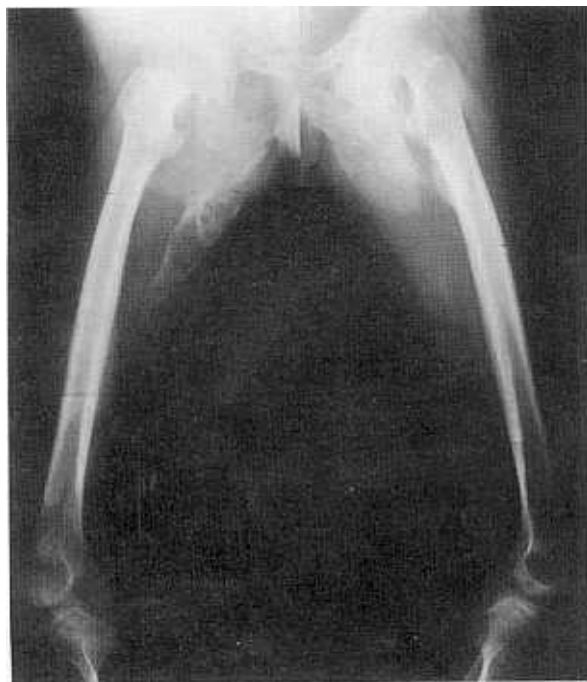

Fig. 1. Plain X-ray revealed HO at both hip joint areas, the entire right thigh and the left upper thigh.

A serum alkaline phosphatase level drawn ten days after the onset of the pain showed an increase to 824 U/L. A whole body bone scan obtained two weeks after the onset of the pain revealed increased isotope uptake in multiple areas including both hip joint areas, the entire right thigh, the left upper thigh, both knee joints and both ankle joints (Fig. 2). We assumed that the pain was caused by the increased activity of the established HO on the basis of clinical symptoms and laboratory tests.⁷⁻⁹

We decided to treat the patient with radiation therapy to relieve the refractory pain in both lower extremities, and indomethacin was stopped because the patient had experienced gastrointestinal side effects. The left lower extremity received radiation therapy at first because the patient had complained of more severe pain on the left side. The patient was treated with 10 MV X-rays from a linear accelerator

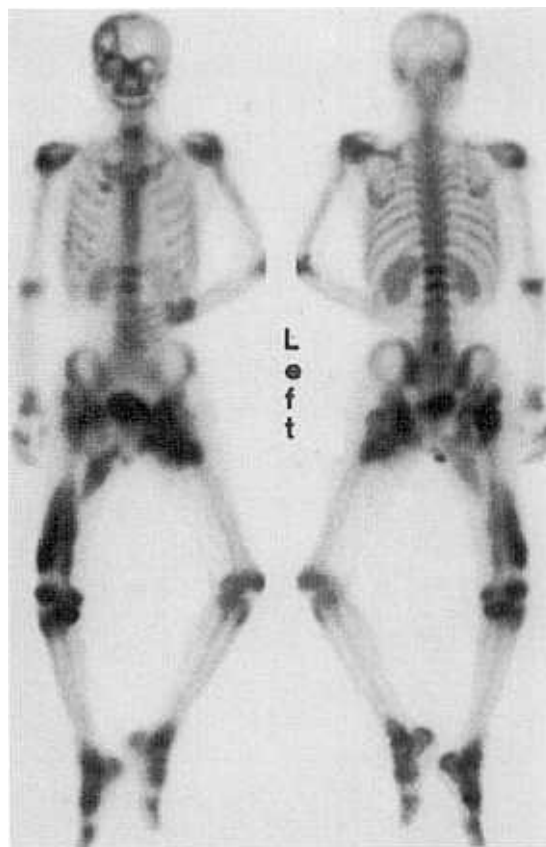


Fig. 2. Whole body bone scan obtained two weeks after the onset of pain revealed increased isotope uptake in both hip joint areas, the entire right thigh, the left upper thigh, both knee joints and both ankle joints.

(NELAC-1018, NEC) using source-skin distance (SSD) of 184 cm. The initial treatment portal included the left hip joint area and lower extremity. The prescribed dose was a total dose of 20 Gy in 10 fractions over 2 weeks. After three days' rest, another treatment was given to the right hip joint area and lower extremity using a similar technique to that mentioned above. By the fifth day of radiation therapy, the patient's condition began to improve, and after the completion of radiation therapy he was able to sleep comfortably and participate in physical and occupational therapy. The intensity of the pain in both lower extremities had obviously decreased to five marks on the visual analogue scale. The level of serum alkaline phosphatase decreased to 463 U/L two weeks after the first radiation therapy, to 314 U/L immediately following the final radiation therapy, and was in the normal range within one month of the commencement of the radiation therapy. The range of motion of both hip joints increased by about ten degrees.

By the fifteenth day of radiation therapy, we found mild pancytopenia, where the WBC was 3000 K/uL (normal range: 4000–10000), the RBC was 4.25 K/uL (normal range: 4.5–6.3), and the platelet count was 135 K/uL (normal range: 140–440). The radiation therapy was not discontinued, however, because the pancytopenia had progressively improved in follow-up laboratories. Immediately after all the radiation therapy, the serum RBC and platelet count were found to be in the normal range, although the WBC was not, and the leukopenia had also recovered to within the normal range one month after radiation therapy.

DISCUSSION

It has been reported that HO occurs in 11 to 76% of patients with traumatic brain injury, where 10 to 20% of cases are clinically significant.^{1,10} Therefore, it is very important to choose the proper treatment method for HO. The effect of radiation therapy and medication on established HO has been questioned. The most popular treatment method for established HO is surgical operation. However, because the patient should wait 12 to 18 months after the onset of HO,^{11,12} the need to wait for the operation can result in the significant problem of missing the critical

period for rehabilitation.

With the exception of one report,⁶ in a medline literature search we found no reference in recent worldwide literature to the use of radiation therapy for established HO. In the case reported here, the pain and level of serum alkaline phosphatase decreased significantly with radiation therapy. The patient experienced mild pancytopenia as a side effect of the radiation therapy, but it was not severe enough to stop the treatment or even change the schedule. We concluded that radiation therapy can be an effective treatment method when the established HO increased activity is refractory to medication.

The patient complained of severe pain in the entire field of both lower extremities. We failed to control the pain or the increased activity of HO with indomethacin. An operation was not a consideration due to the immaturity of the HO. There was no treatment method available other than radiation therapy. The patient exhibited many risk factors for the recurrence of new HO, such as severe previous HO, severe spasticity in both lower extremities and immobility due to being confined in a bedridden state.^{2,4} Therefore, we decided to perform radiation therapy on the entire field of the lower extremities in the hope of decreasing the pain and preventing the recurrence of HO. In fact, new HO occurred in his left shoulder area four months later, but not in the lower extremities that had been treated with radiation therapy.

We could not find much information in recent literature on the optimal regimen of radiation therapy for established HO. We were obliged to adopt the dosage and schedule of radiation treatment from the report by Schaeffer et al.,⁶ which was the only report about radiation therapy for established HO. We suggest that more research is necessary in the future to determine the optimal dose-fractionation of radiation therapy for HO and to establish a management strategy for HO throughout HO care, comparing the outcomes of medications and operations with regard to their efficacy of treatment, economical efficiency and side-effects.

REFERENCES

1. Garland DE. A clinical perspective on common forms of acquired heterotopic ossification. *Clin Orthop* 1991;263:

- 13-29.
2. Varghese G. Heterotopic ossification. *Phys Med Rehabil Clin North Am* 1992;3:407-15.
3. Djergaian RS. Management of musculoskeletal complications. In: Horn LJ, Zasler ND, et al. *Medical rehabilitation of traumatic brain injury*. 1st ed. Philadelphia: Mosby Company; 1996. p.459-77.
4. Ayers DC, Pellegrini VD, Evarts CM. Prevention of heterotopic ossification in high-risk patients by radiation therapy. *Clin Orthop* 1991;263:87-93.
5. Han CD, Choi CH, Suh CO. Prevention of heterotopic bone formation after total hip arthroplasty using 600 rad in single dose in high risk patient. *Yonsei Med J* 1997; 38:96-100.
6. Schaeffer MA, Sosner J. Heterotopic ossification: treatment of established bone with radiation therapy. *Arch Phys Med Rehabil* 1995;76:284-6.
7. Kewalramani L, Orth M. Ectopic Ossification. *Am Phys Med* 1977;56:99-121.
8. Orzel JA, Rudd TG. Heterotopic bone formation: Clinical, laboratory and imaging correlation. *J Nucl Med* 1985; 26:125-32.
9. Pittinger DE. Heterotopic ossification. *Orthop Rev* 1991; 20:33-9.
10. Garland DE, Blum CE, Waters RL. Periarticular heterotopic ossification in head-injured adults. *J Bone Joint Surg* 1980;62A:1143-6.
11. Garland DE, Hanscom DA, Keenan MA, Smith C, Moore T. Resection of heterotopic ossification in the adult with head trauma. *J Bone Joint Surg* 1985;67A:1261-9.
12. Hammond FM, McDevitt JT. Medical and orthopedic complications. In: Rosenthal M, Griffith ER, Kreutzer JS, Pentland B, editors. *Rehabilitation of the adult and child with traumatic brain injury*. 3rd ed. Philadelphia: F.A. Davis; 1999. p.53-73.