

Solitary Rectal Ulcer Syndrome

Hyo Jin Park, Won Ho Kim, Jae Soon Woo, Kwang Hyub Han,
Sang In Lee, In Suh Park, Ji Young Han¹ and Chan Il Park¹

We report three cases of solitary rectal ulcer syndrome (SRUS). The diagnosis was established according to histopathologic criteria. But, the initial clinical diagnosis was carcinoma, non-specific ulcer and localized proctitis respectively. SRUS is considered as one of functional disorder in pelvic floor which might go underdiagnosed due to unfamiliar concept in Korea. So we should consider SRUS to be one of the differential diagnosis in cases of complaining anorectal symptoms.

Key Words: Solitary rectal ulcer syndrome, rectal prolapse, fibromuscular obliteration

Solitary rectal ulcer, initially described 150 years ago (Cruveilhier 1830), and extensively reviewed by Madigan and Morson (1969), is a chronic benign condition characterized by rectal bleeding, the passage of mucus and rectal pain. Although the term solitary rectal ulcer syndrome (SRUS) has been widely accepted in general, it remains potentially a misnomer, because the lesions are not always ulcerated and solitary on macroscopic examination (Madigan and Morson 1969). For this reason, Boulay *et al.* (1983) proposed mucosal prolapse syndrome as a common clinicopathological term. Although the histopathologic features of the lesion are characteristic, the clinical and endoscopic appearances are not, and can be confusing. We report 3 cases of SRUS patients with different clinical and endoscopic features but similar histopathologic findings.

CASE REPORT

Case 1.

A 55-year-old female had rectal pain and excessive straining for 10 days prior to being seen in this hospital in September 1989. Sigmoidoscopy revealed 4×3 cm sized, well defined, deep ulcerative lesion demarcated by a band-like marginal elevation with irregular and nodular base, 7cm from anal verge on the anterior rectal wall (Fig. 1). The initial endoscopic diagnosis was a rectal carcinoma. The microscopic examination of the biopsy specimen revealed distorted, slightly dilated crypt, irregular thickening of muscularis mucosa and fibromuscular obliteration of lamina propria (Fig. 2a, b). Barium enema showed a coarse granular pattern in the lower rectum (Fig. 3). The physical examination and the laboratory findings were normal except mild anemia (Hb 10.3g/dl). She was diagnosed as SRUS and was treated with oral sulphasalazine for 4 weeks with no significant improvement by the sigmoidoscopy. Thereafter, we have followed her with reassurance and high fiber diet. The sigmoidoscopy revealed a completely healed ulcer with mucosal bridge 18 months after the initial examination (Fig. 4).

Received December 6, 1993

Department of Internal Medicine, Institute of Gastroenterology and Pathology, Yonsei University College of Medicine, Seoul, Korea

Address reprint requests to Dr. H.J. Park, Department of Internal Medicine, Yonsei University College of Medicine, C.P.O. Box 8044, Seoul 120-752, Korea

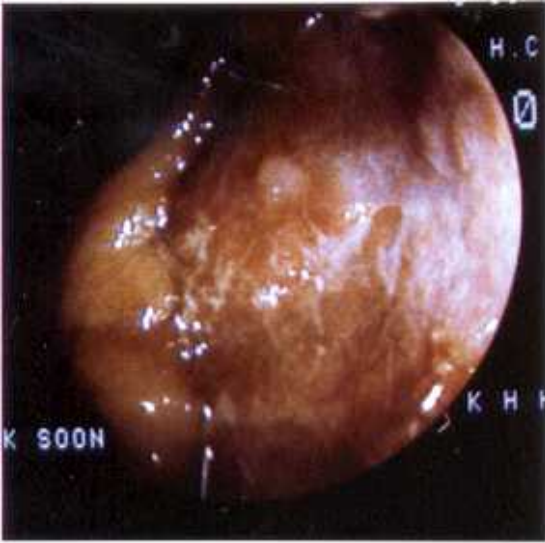


Fig. 1. Solitary, large ulcer demarcated by a band-like marginal elevation with irregular and nodular base (Case 1).

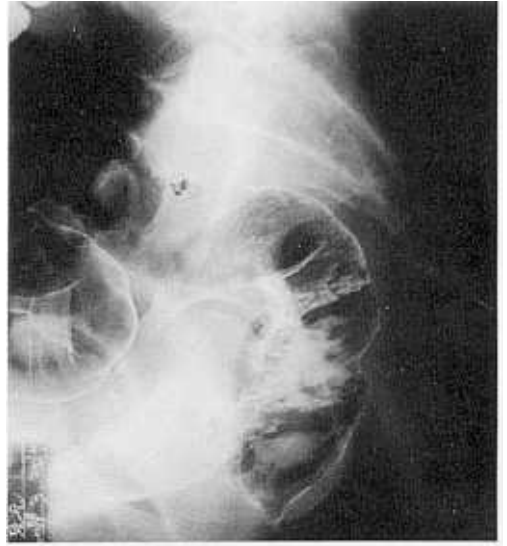

Fig. 3. Barium enema shows a coarse granular pattern in the anterior wall of rectum (Case 1).

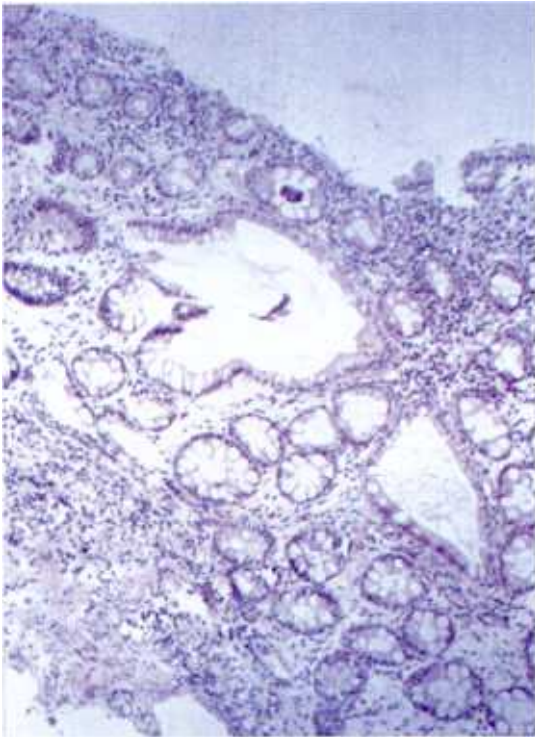


Fig. 2a. The biopsy specimen shows distorted and slightly dilated crypt (H&E, $\times 100$) (Case 1).

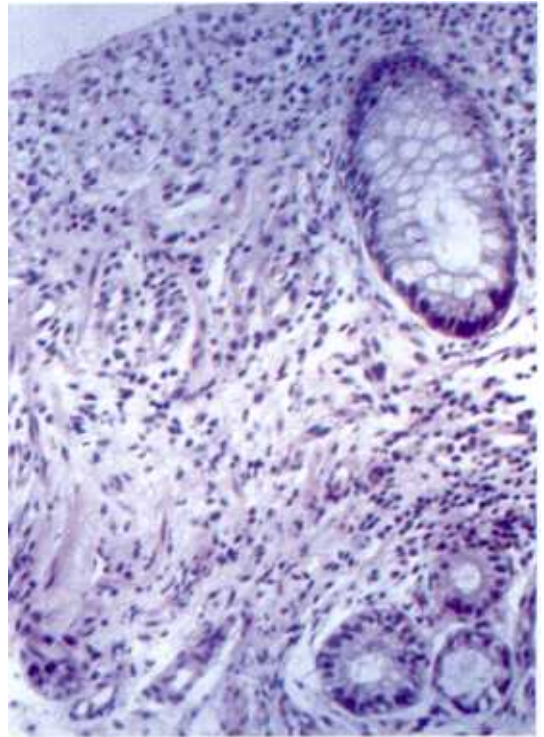


Fig. 2b. Fibromuscular obliteration of lamina propria with irregular thickening of muscularis mucosa (H&E, $\times 200$) (Case 1).

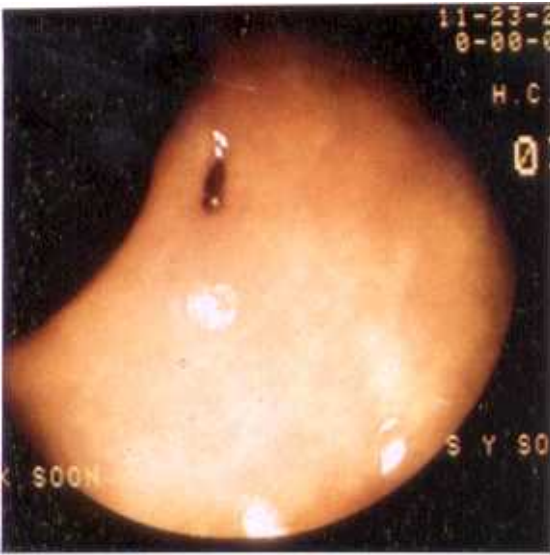

Fig. 4. Sigmoidoscopy 18 months after initial examination shows completely healed ulcerative lesion with mucosal bridge (Case 1).

Case 2.

A 54-year-old female was seen in September of 1992 with a complaint of rectal bleeding and fecal soiling for 1 year. The sigmoidoscopy revealed two 0.5×0.4 cm sized, punched-out ulcers with well demarcated margin, 8 cm and 10 cm from anal verge on the anterior and the antero-lateral rectal wall respectively. The histologic examination of the biopsy specimen showed an ulcer with irregularly thickened muscularis mucosa, and longitudinal smooth muscle fibers were seen extending into the lamina propria (Fig. 5). The defecogram revealed rectocele with rectal intussusception and accentuation of impression of puborectalis sling. The anorectal angle was 90° at rest and 83° during evacuation (Fig. 6). In the anorectal electrophysiologic test, the maximum resting and the squeeze anal sphincter pressure was 30 and 120 mmHg respectively, the rectoanal inhibitory reflex was intact, and the sacral reflex latency was Rt. 189.28 msec and Lt. 166.40 msec (normal value; 32.3~39.5 msec) (Fig. 7). The motor evoked potential of pudendal nerve by magnetic stimulation was Rt. 22.04 msec and Lt. 13.52 msec (normal value; 5.7~10.1

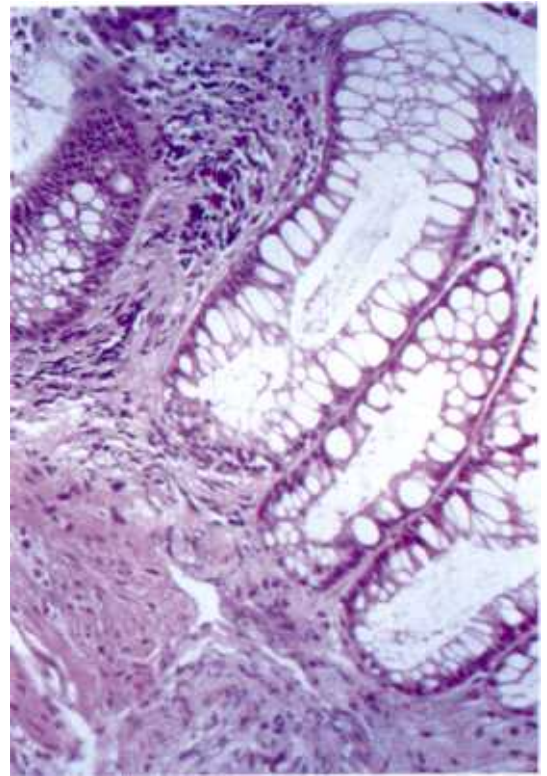


Fig. 5. Irregularly thickened muscularis mucosa and fibromuscular obliteration of the lamina propria (H&E, $\times 200$) (Case 2).

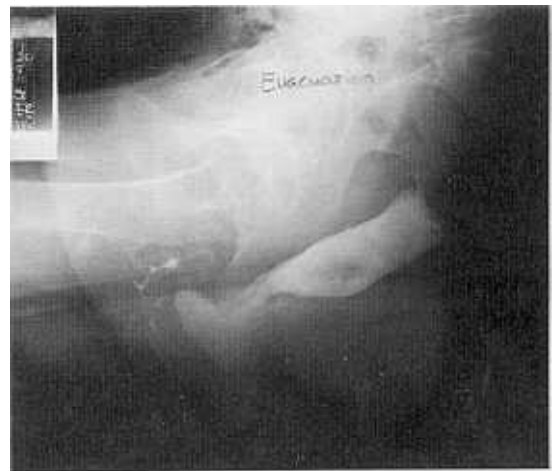

Fig. 6. Defecogram on evacuation state shows rectocele with rectal intussusception and accentuation of impression of puborectalis sling (Case 2).

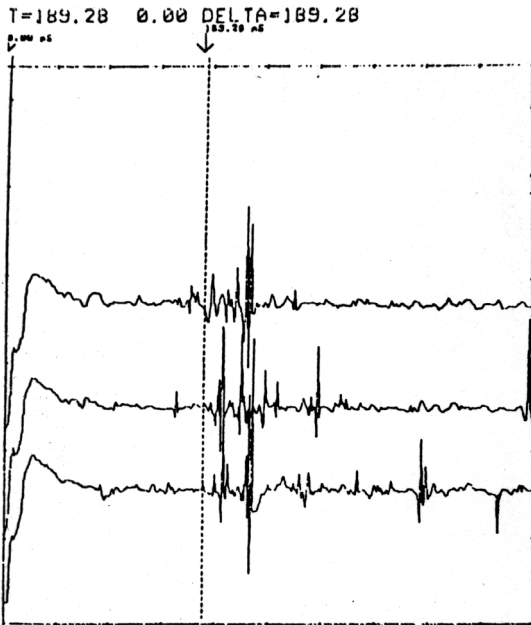

Fig. 7. Sacral reflex latency of right side reveals 189.28 msec, which is much delayed (Case 2).

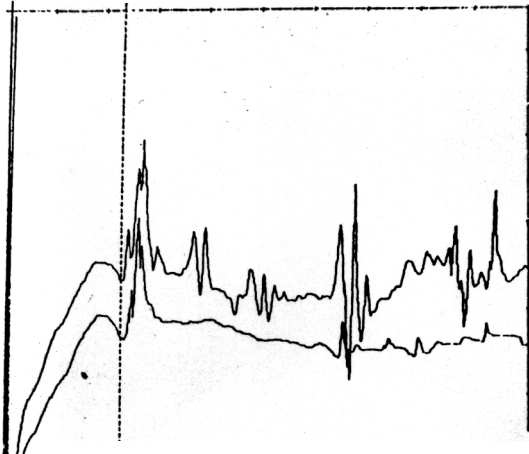


Fig. 8. Motor evoked potential by magnetic stimulation shows 22.04 msec (Case 2).

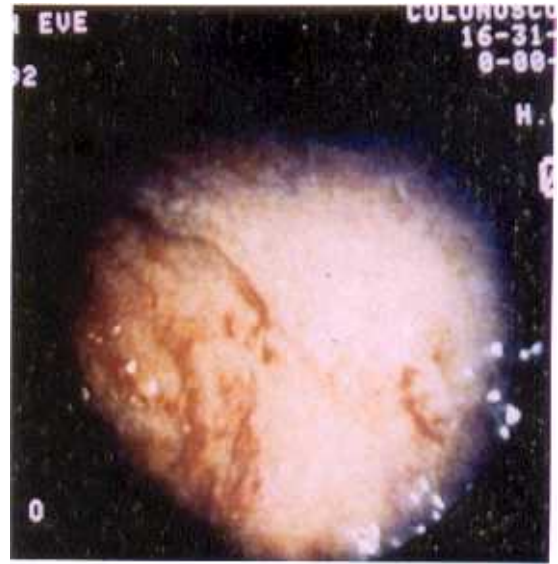

Fig. 9. Sigmoidoscopy shows edematous, hyperemic mucosa of anterior aspect of rectum (Case 3).

msec) (Fig. 8), suggestive of bilateral pudendal neuropathy. She was treated by EMG-assisted biofeedback for dyskinetic puborectalis according to protocol (Freshman *et al.* 1992) and she was advised to administer sucralfate 2g suspended in 30 ml of tap water, once a day for 2 weeks as a retention enema.

Case 3.

A 56-year-old female was seen in November of 1992 with complaints of rectal bleeding and tenesmus for 1 year. The sigmoidoscopy revealed an edematous, hyperemic anterior rectal mucosa, 5 to 10 cm from the anal verge (Fig. 9).

The microscopic examination of the biopsy specimen showed an ulcer with irregularly thickened muscularis mucosa and fibromuscular obliteration of the lamina propria (Fig. 10). The defecogram revealed rectocele with rectal intussusception and excessive pelvic floor descent. The anorectal angle was 107° at rest and 124° during evacuation (Figure 11). The physical and laboratory examinations were normal. Initially, she was diagnosed as inflammatory bowel disease and was treated with oral metronidazole. The sigmoidoscopy re-

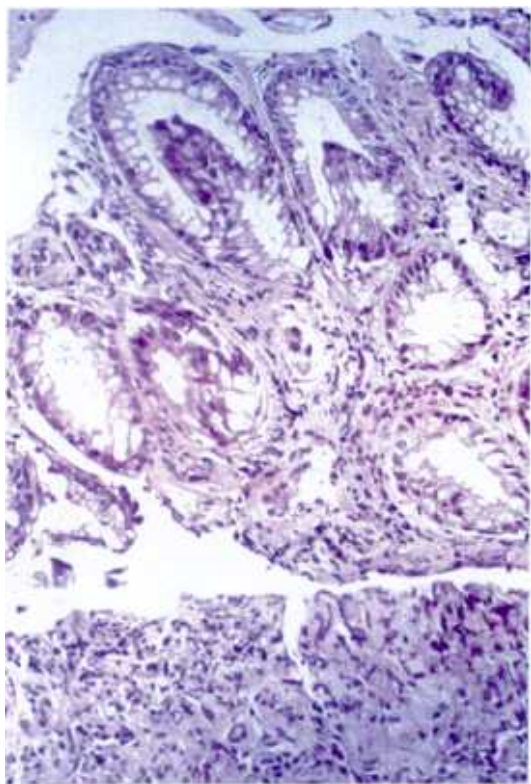


Fig. 10. Microscopic examination of the biopsy specimen shows ulceration with fibromuscular obliteration of the lamina propria (H&E, $\times 200$) (Case 3).

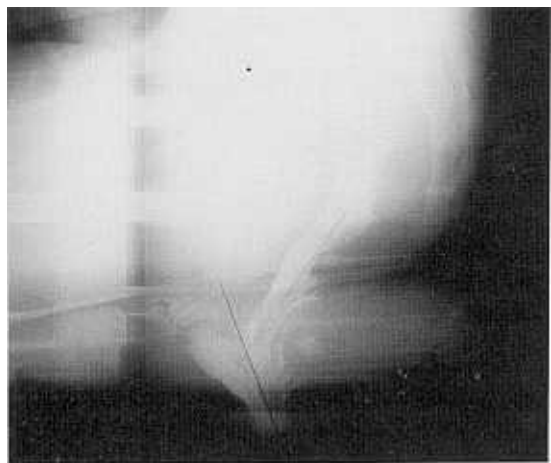


Fig. 11. Defecogram shows rectocele with rectal intussusception and excessive pelvic floor descent (Case 3).

vealed a resolving process 4 weeks after the initial examination.

DISCUSSION

Solitary rectal ulcer syndrome (SRUS) is a chronic benign, unusual disorder which forms one of the spectrum of functional disorders of the pelvic floor, characterized by rectal bleeding, mucus discharge, anorectal pain, straining, or incomplete evacuation (Madigan and Morson 1969; Rutter and Riddell 1975).

Earlier reports suggested that the patients with SRUS presented in the third and fourth decades (Ford *et al.* 1983), but more recent studies, including our report have shown that older patients, by a decade or more, are affected with a modest female preponderance (Rutter and Riddell 1975; Niv and Bat 1986).

The etiopathogenesis of SRUS is still unknown. However, several theories with combinations of inflammation, mucosal trauma, and prolapse have been suggested (Rutter and Riddell 1975; Kennedy DK *et al.* 1977). One of the mechanisms may be the result of paradoxical contraction of puborectalis on defecation, which lets fecal streams on to the anterior rectal wall instead of anal canal. This can cause mucosal prolapse (Rutter and Riddell 1975; Levine 1987). Based on this theory, direct trauma due to the fecal stream as well as the mucosal ischemia secondary to the rectal mucosal prolapse may lead ulceration (Levine 1987). The defecogram has brought a better understanding on the pathogenesis of SRUS. The anorectal angle is 92° ($80\sim 100^\circ$) at rest and 130° ($120\sim 150^\circ$) on straining in control group (Womack 1985).

However, a widening of the anorectal angle on straining might be smaller in the SRUS than normal group (Azuma *et al.* 1990). Womack *et al.* (1987) have demonstrated that 94% of cases were associated with some degree of rectal prolapse. The rectal prolapse may result from paradoxical contraction of puborectalis muscle, and chronic straining may lead to perineal descent (Parks *et al.* 1977).

Therefore, the accentuation of the pubo-

rectalis on straining or the excessive pelvic floor descent may be the one of the defecographic findings of SRUS in our report. Macroscopically the lesion can be identified as an ulcer with 0.5~5.0 cm in diameter, mucosal hyperemia, or polypoid lesion, situated on the anterior wall 5~10 cm from the anus. In addition, the rectal ulcer can be single or multiple (Madigan and Morson 1969; Saul and Sollenberger 1985). Martin *et al.* (1981) described the incidence of macroscopic appearance as ulcerative in 57%, polypoid in 25%, and flat type in 18%. The most important is to differentiate the macroscopic finding of SRUS from rectal cancer or inflammatory bowel disease. Of significance, the gross appearance can simulate rectal cancer, if there is mucosal edema around the ulcerative lesion. Our patients were initially regarded as rectal cancer, non-specific rectal ulcer and localized proctitis respectively.

A follow-up study by Madigan and Morson (1969) revealed little change in their appearance during the observation of average 8 years. However, it has been reported that the size and the shape of the ulcer changed in some reports (Franzin *et al.* 1982; Ford *et al.* 1983), and changed from the ulcerative type to the polypoid type. Okada *et al.* (1990) reported that SRUS, initially occurred as a flat type, can change into a polypoid, or ulcerative lesion. We have followed up one of our patients (case 1) for 18 months until the ulcer has been completely healed.

Histologically, the disorder is characterized by a thickened and disorganized muscularis mucosa and the presence of longitudinal muscle fibers in the lamina propria which progresses to fibromuscular obliteration regardless of the presence or absence of ulceration (Britto E *et al.* 1987; Royes CA *et al.* 1992). In addition, there are regenerative changes in the crypt epithelium that may be associated with a villous configuration and displacement of mucosal glands into the submucosa (Madigan and Morson 1969; Rutter and Riddell 1975). Comparing with inflammatory bowel disease, the inflammation is typically mild in SRUS, and the presence of longitudinal muscle fibers in the lamina propria or fibromuscu-

lar obliteration is a sensitive marker that distinguishes SRUS from inflammatory bowel disease. However this feature can be seen in other conditions, such as at margin of an ileostomy or colostomy, or in overt rectal prolapse (Rutter and Riddell 1975; Rosen *et al.* 1976). Moreover, the displacement of mucosal glands into the submucosa can cause cystic dilatation due to the retention of mucus, which can develop into colitis cystica profunda to give rise to a confusing appearance of mucinous adenocarcinoma (Silver and Stoler 1969; Martin JK *et al.* 1980).

The anorectal function in SRUS was revealed as overactivity of the external anal sphincter and high intrarectal pressure on voiding compared with the controls (Womack *et al.* 1987). This is now recognized as a relatively non-specific finding and the maximum anal resting and the squeeze pressures in SRUS were reported as 59 ± 10 mmHg, 150 ± 17 mmHg, respectively, which are within the normal range (Tjandra *et al.* 1992). Based on these findings, the anorectal function tests seem to provide little additional information on understanding the pathogenesis or diagnosis of SRUS. But straining at stool is a general feature in solitary rectal ulcer syndrome and excessive straining may cause a stretch injury of pudendal nerve and may eventually result in incontinence as our case 2 (Henry MM and Swash M. 1992).

Several therapeutic approaches, whether surgical or medical, have been tried but there is no general agreement on the treatment of SRUS until now. Because the lesions are not always progressive and not associated with the development of carcinoma, reassurance and education on high fiber diet with avoidance of excessive straining seem to be important (Van den Brandt-Gradel *et al.* 1984). Drug treatment, such as sulfasalazine, local or systemic corticosteroid and antibiotics have not shown obvious improvement (Ford *et al.* 1983). More recently, sucralfate which is a locally acting nonsystemic cytoprotective agent, has been tried as a form of retention enema and showed good improvement (Zargar *et al.* 1991). Bulk laxatives and biofeedback therapy of retraining for the dyskinetic puborectalis

would be helpful (Tjandra *et al.* 1993). In the event of failure of the medical conservative treatment, the surgical approach for the correction of rectal prolapse should be considered. The optimal surgical procedure is still uncertain, but local excision, rectopexy, diversion, electrocautery have been tried with variable results (Madigan and Morson 1969; Ford *et al.* 1983; Saul 1985; Tjandra *et al.* 1993). When rectal prolapse is present, the rectopexy would be the most favorable procedure on SRUS.

In conclusion, SRUS has been underdiagnosed probably due to unfamiliar concept in Korea, and only 4 cases have been reported in Korea (Chang *et al.* 1987; Kim *et al.* 1991). Therefore, high index of suspicion will be required in the case of anorectal symptoms. To evaluate the risk factor of the patients of rectal prolapse developing into SRUS, prospective anorectal physiologic tests including rectal mucosal electrosensitivity and immunohistochemical study for the matrix protein of the rectal muscular layer may be recommended. Most of patients with SRUS would show successful response to the medical treatments, but more experience in this disease is required.

ACKNOWLEDGEMENTS

The authors are grateful to Dr. C. Makunura, pathologist, St. Bartholomew Hospital, London for helpful advice.

REFERENCES

- Azuma M, Sumikoshi Y, Iwadare J, Ono R: Pathophysiology and treatment of mucosal prolapse syndrome. *Stomach and Intestine* 25: 1295-1300, 1990
- Boulay CED, Fairbrother J, Isaacson PG: Mucosal prolapse syndrome—a unifying concept for solitary ulcer syndrome and related disorders. *J Clin Pathol* 36: 1264-1268, 1983
- Britto E, Borges AM, Swaroop VS, Jagannath P, Desouza LJ: Solitary rectal ulcer syndrome. *Dis Colon Rectum* 30: 381-385, 1987
- Chang YW, Jeoung HC, Kim BH, Lee JI, Chang R, Min YI: Three cases of solitary rectal ulcer syndrome. *Korean J Gastroenterol* 19: 333-337, 1987
- Cruveilhier J: Ulcere chronique du rectum. Anatomie pathologique du corps humain. Paris, JB Bailliere 4, 1830
- Ford MJ, Anderson JR, Gilmour HM, Holt S, Sircus W, Heading RC: Clinical spectrum of "solitary ulcer" of the rectum. *Gastroenterology* 84: 1533-1540, 1983
- Franzin G, Dina R, Scarpa A, Fratton A: The evolution of the solitary ulcer of the rectum—an endoscopic and histopathological study. *Endoscopy* 4: 131-134, 1982
- Freshman JW, Dreznik Z, Meyer K, Fry RD, Carney R, Kodner IJ: Outpatient protocol for biofeedback therapy of pelvic floor outlet obstruction. *Dis Colon Rectum* 35: 1, 1992
- Henry MM, Swash M: Aetiology of pelvic floor disorders: Coloproctology and the pelvic floor. 2nd ed. Oxford, Butterworth-Heinemann Ltd. 1992, 252-256
- Kennedy DK, Hughes ESR, Masterton JP: The natural history of benign ulcer of the rectum. *Surgery, Gynecology & Obstetrics* 144: 718-720, 1977
- Kim MJ, Yoon KH, Rew JS, Kim SJ, Yon CM: A case of solitary rectal ulcer syndrome. *Korean J Gastrointest Endosc* 11: 113-116, 1991
- Levine DS: "Solitary" rectal ulcer syndrome. Are "solitary" rectal ulcer syndrome and "localized" colitis cystica profunda analogous syndrome caused by rectal prolapse? *Gastroenterology* 92: 243-253, 1987
- Madigan MR, Morson BC: Solitary ulcer of the rectum. *Gut* 10: 871-881, 1969
- Martin CJ, Parks TG, Biggart JD: Solitary rectal ulcer syndrome in Northern Ireland. *Br J Surg* 68: 744-747, 1981
- Martin JK, Culp CE, Weiland LH: Colitis cystica profunda. *Dis Colon Rectum* 23: 488-491, 1980
- Niv Y, Bat L: Solitary rectal ulcer syndrome—clinical, endoscopy, and histological spectrum. *Am J Gastroenterol* 81: 486-491, 1986
- Okada M, Imamura K, Yao T, Sakurai T, Iwashita A, Murayama H: The evolution of the lesion in the solitary rectal ulcer syndrome. *GI Endoscopy* 36: 621-623, 1990
- Parks AG, Swash M, Urlich H: Sphincter denervation in anorectal incontinence and rectal prolapse. *Gut* 18: 656-665, 1977
- Rosen Y, Vaillant JG, Yermakow V: Submucosal mucous cysts at a colostomy site. *Dis Colon Rectum* 19: 453-457, 1976
- Royes CA, Williams NP, Hanchard B, Lee MG:

- Solitary rectal ulcer syndrome. *W I Med J* 42: 152-155, 1992
- Rutter KRP, Riddell RH: The solitary ulcer syndrome of the rectum. *Clin Gastroenterol* 4: 505-529, 1975
- Saul SH, Sollenberger LC: Solitary rectal ulcer syndrome. Its clinical and pathological underdiagnosis. *Am J Surg Pathol* 9: 411-421, 1985
- Silver H, Stoler J: Distinguishing features of well differentiated mucinous adenocarcinoma of the rectum and colitis cystica profunda. *Am J Clin Pathol* 51: 493-500, 1969
- Tjandra JJ, Fazio VW, Church JM, Lavery IC, Oakley JR, Milsom JW: Clinical conundrum of solitary rectal ulcer. *Dis Colon Rectum* 35: 227-234, 1992
- Tjandra JJ, Fazio VW, Petras RE, Lavery IC, Oakley JR, Milsom JW, Church JM: Clinical and pathologic factors associated with delayed diagnosis in solitary rectal ulcer syndrome. *Dis Colon Rectum* 36: 146-153, 1993
- Van den Brandt-Gradel V, Huibregtse K, Tytgat GNJ: Treatment of solitary rectal ulcer syndrome with high fiber diet and abstention of straining at defecation. *Dig Dis Sci* 29: 1005-1008, 1984
- Womack NR, Williams NS, Holmfield JH: New method for the dynamic assessment of anorectal function in constipation. *Br J Surg* 72: 994-998, 1985
- Womack NR, Williams NS, Holmfield JH, Morrison JF: Anorectal function in the solitary rectal ulcer syndrome. *Dis Colon Rectum* 30: 319-323, 1987
- Zargar SA, Khuroo MS, Mahajan R: Sucralfate retention enemas in solitary rectal ulcer. *Dis Colon Rectum* 34: 455-457, 1991
-