

Management of Dermoid Tumor in the Medial Canthal Area

Nam Ju Kim, MD^{1,2}, Ho Kyung Choung, MD^{1,3}, Sang In Khwarg, MD¹

¹Department of Ophthalmology, Seoul National University College of Medicine, Seoul, Korea,

²Department of Ophthalmology, Seoul National University Bundang Hospital, Seongnam, Korea,

³Department of Ophthalmology, Seoul National University Boramae Hospital, Seoul, Korea

Dermoid tumors in the medial canthal area are rare, but when present they commonly adhere to the lacrimal canaliculi. Three patients presented with a mass in the medial canthal area. The authors performed excisional biopsies, and the masses were diagnosed as dermoid tumors. In two patients, canalicular lacerations were found after mass excision, which suggested that the masses had been firmly adherent to the lacrimal canaliculi. The lacerated canaliculi were repaired after bicanalicular silicone intubation. In the remaining patient, lacrimal silicone intubation was performed at the beginning of surgery, and the mass was successfully dissected from the canaliculi, leaving them intact. Excision of dermoid tumors in the medial canthal area requires careful dissection to avoid canalicular laceration. Bicanalicular silicone intubation at the beginning of surgery is helpful for the identification of the canaliculi and for the prevention of canalicular laceration during dermoid tumor excision.

Korean J Ophthalmol 2009;23:204-206 © 2009 by the Korean Ophthalmological Society.

Key Words: Canaliculus, Dermoid, Medial canthus, Silicone tube

Orbital dermoid tumors are developmental choristomas that contain skin and skin appendages, arising from ectodermal rests pinched off at suture lines. These tumors usually occur in children or young adults and present in infancy or a few years later and then enlarge slowly. Orbital dermoid tumors are categorized into superficial orbital dermoids and deep orbital dermoids. Superficial orbital dermoid tumors occur most commonly in the area of the lateral brow adjacent to the frontozygomatic suture. Infrequently a tumor may be encountered in the medial canthal area.¹ Because dermoid tumors of the medial canthal area are located very close to, or are even adherent to the lacrimal drainage system, surgical excision of these masses may injure this system.

To our knowledge, only two case reports have been issued on orbital dermoid tumors that occurred in the medial canthal area.^{2,3} The authors of this article experienced three cases of orbital dermoid tumors in the medial canthal area that involved the lacrimal canaliculi and report on the management and complications associated with this condition and discuss ways of preventing complications.

Case Report

Case 1

Received: May 24, 2008 Accepted: July 28, 2009

Reprint requests to Sang In Khwarg, MD, Department of Ophthalmology, Seoul National University College of Medicine, #28 Yeongeong-dong, Jongno-gu, Seoul 110-744, Korea. Tel: 82-2-2072-2879, Fax: 82-2-741-3187, E-mail: khwarg@snu.ac.kr

A 25-year-old female presented with a painless mass in the medial canthal area of the left eye. The mass had been present for 20 years (Fig 1A). An examination revealed a hard, non-tender, movable mass measuring about 1 cm located just inferior to the left medial canthal tendon (MCT). The size of the mass didn't change when the patient's position changed or when a Valsalva maneuver was performed. Best corrected visual acuity of the left eye was 1.0 and the anterior segment was normal. There was no epiphora, the height of the tear meniscus was normal, and irrigation of the lacrimal system revealed no abnormalities. A computed tomographic (CT) scan of the orbit showed that a cystic lesion was lying just anterior to the lacrimal drainage system (Fig. 1B).

The mass was suspected to be a dermoid and excision was performed. It proved to be a yellow, well-demarcated tumor that was adherent to the MCT and periosteum. The mass was dissected from the MCT and periosteum, but during subsequent dissection, it was impossible to dissect the posterior surface of the mass whilst maintaining visibility because of a deep, narrow surgical field. After completing the dissection of the posterior surface of the mass from surrounding tissues, lacerations of both the upper and lower canaliculus were found near the common canaliculus. Both cut ends of the canaliculi were sutured after a bicanalicular silicone tube had been placed. There was some epiphora immediately after surgery, but this resolved 1 month later. The silicone tube was removed at 6 months after surgery.

Case 2

A 13-year-old boy presented with a painless mass in the

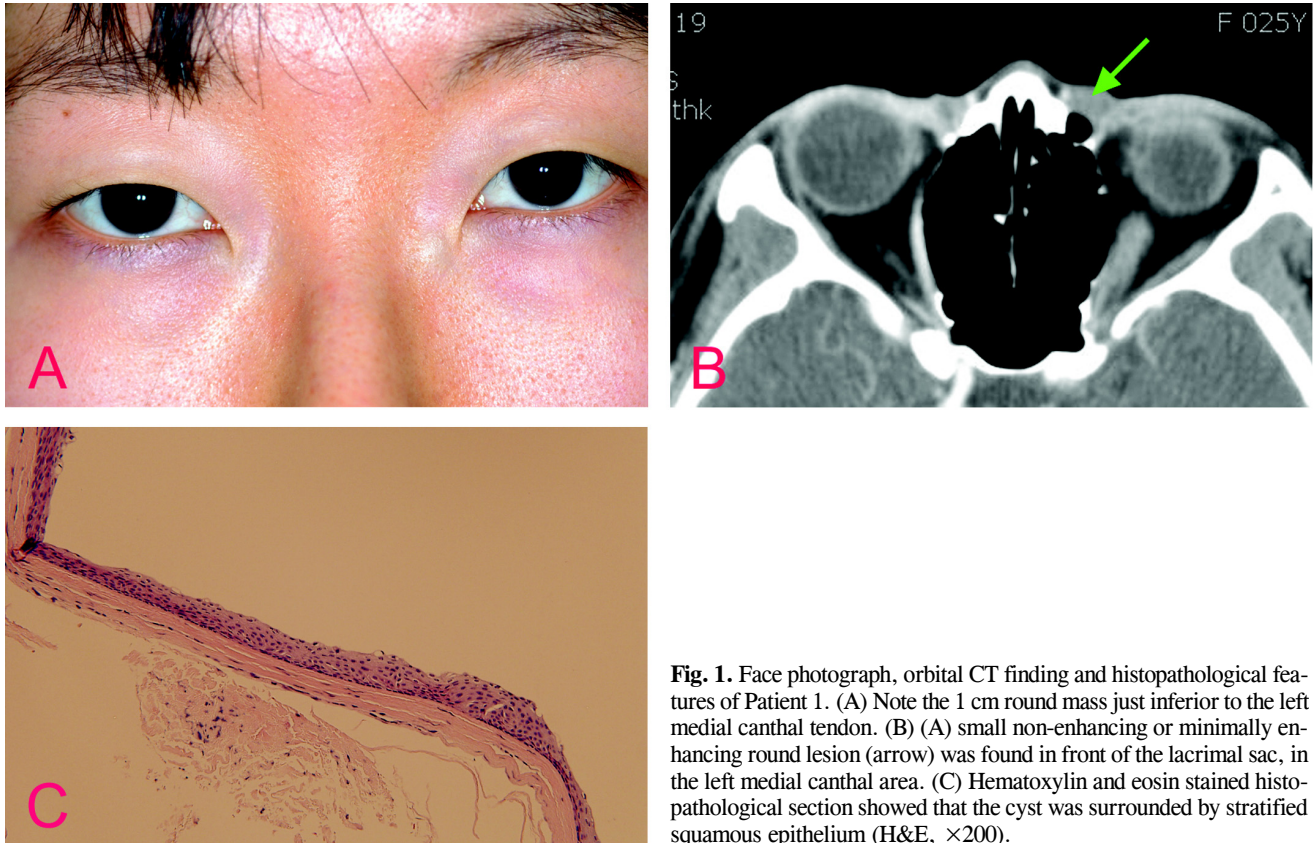


Fig. 1. Face photograph, orbital CT finding and histopathological features of Patient 1. (A) Note the 1 cm round mass just inferior to the left medial canthal tendon. (B) (A) small non-enhancing or minimally enhancing round lesion (arrow) was found in front of the lacrimal sac, in the left medial canthal area. (C) Hematoxylin and eosin stained histopathological section showed that the cyst was surrounded by stratified squamous epithelium (H&E, $\times 200$).

medial canthal area of the left eye which had been initially found 1 year previously (Fig 2). He had bilateral retinopathy and had used low vision aids. An examination revealed a moderately hard non-movable mass measuring about 1.5 cm located in the left medial canthal area just inferior to the MCT. Best corrected visual acuity was 0.02 in the right eye and 0.1 in the left, and anterior segments were normal. There was no epiphora, and the height of the tear meniscus was normal. A CT scan of the orbit showed a well-demarcated mass adjacent to the nasolacrimal system.

The mass was suspected to be a dermoid tumor and excision

was performed. After probes had been placed in the upper and lower canaliculi, the mass was carefully dissected. The tumor was grayish-white and densely adherent to the MCT, the periosteum, and lower canaliculus. After the tumor had been excised with its capsule intact, lacrimal irrigation revealed a 3 mm-sized slit laceration on the lower canaliculus. The lacerated canaliculus was repaired with sutures after lacrimal silicone intubation. After surgery, there was no epiphora and a good passage was secured for lacrimal irrigation. The silicone tube was removed at 6 months after surgery.

Case 3

A 47-year-old female presented with a painless mass in the medial canthal area of the left eye which had been initially found 10 months previously (Fig 3). An examination revealed a hard, movable mass measuring about 1.5 cm located just inferior to the left MCT. Best corrected visual acuity of the left eye was 1.0, and the anterior segment was normal. The height of the tear meniscus was normal, and nasolacrimal irrigation revealed no abnormalities. A CT scan of the orbit showed a 1.5 cm-sized cystic lesion lying in the medial canthal area just anterior to the nasolacrimal system. A dacryocystogram was performed and showed a patent lacrimal system.

The mass was suspected to be a dermoid tumor and excision was performed. The anterior surface of the mass was easily dissected from surrounding tissues but the posterior surface

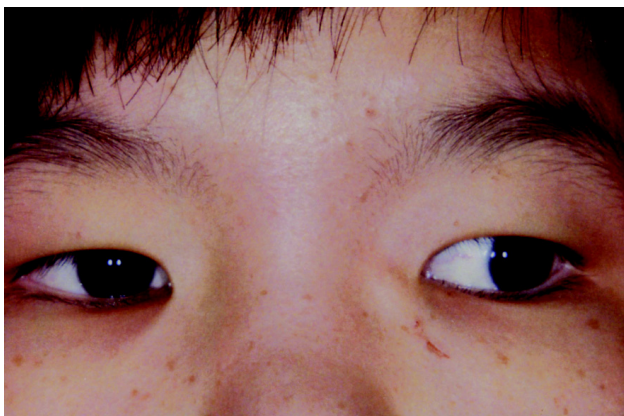


Fig. 2. Face photograph of Patient 2. Note the 1.5 cm round mass in the left medial canthal area.

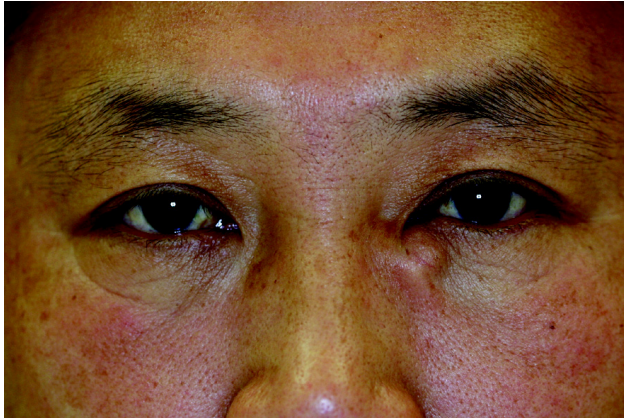


Fig. 3. Face photograph of Patient 3. Note the 1.5 cm round mass just inferior to left medial canthal tendon.

of the mass was firmly adherent to the underlying tissues like the MCT and canaliculus. After the silicone tube had been intubated in the nasolacrimal system through the upper and lower canaliculi, the tumor was carefully dissected with its capsule intact. After completing the mass excision, the canaliculus was intact without laceration or rupture. A histologic examination showed the wall of the cyst to be composed of squamous epithelium along with the occasional hair follicle, and it was diagnosed as a dermoid tumor.

Discussion

Hurwitz et al.¹ reported one case of a dermoid tumor that involved the lacrimal excretory system. Despite placing a probe in the canaliculus and trying to dissect carefully, they transected the lacrimal common canaliculus and failed to perform a primary repair, and undertook canaliculodacryocystorhinostomy (canaliculo-DCR) as the next best option. From preoperative CT and dacryocystograph images, they noted the possibility that the mass was adherent to the lacrimal system, but eventually they failed to avoid a canalicular laceration.

Because a mass in the medial canthal area can involve the

lacrimal system, it is important to perform preoperative assessments using CT or dacryocystography whilst planning the surgical approach. In these cases, the posterior surface of these masses are adherent to the lacrimal system and the surgical field is narrow, which makes careful dissection difficult. Therefore, it is necessary to protect the lacrimal system during surgery. One might consider inserting probes in the upper and lower canaliculi, but probes are not flexible enough to allow surgeon a sufficient surgical field and good visibility. Besides, without a constant force pushing them to the medial side, probes slide out to the punctal side under their own weight. Moreover, having an assistant support probes manually narrows the surgical field even more and complicates the procedure. Therefore, the most effective method of protection is bicanalicular silicone intubation.

Silicone tubes are highly flexible and can maintain the canalicular lumen without distorting the existing lacrimal structures. Using lacrimal silicone intubation, a surgeon can easily identify the canaliculus during dissection, and thus can avoid canalicular damage. Even when a canaliculus is lacerated, primary canalicular repair is straightforwardly performed by suturing the lacerated end on the previously intubated silicone tubing.

When excising a dermoid tumor in the medial canthal area, surgeons should anticipate the possible surgical complication of canalicular laceration. Moreover, silicone intubation at the beginning of the surgery is an easy and effective way of identifying canaliculi and of preventing canalicular laceration during dermoid tumor excision.

References

1. Rootman J. *Disease of the orbit*, 2nd ed. Philadelphia: Lippincott Williams & Wilkins, 2003;418-23.
2. Hurwitz JJ, Rodgers J, Doucet TW. Dermoid tumor involving the lacrimal drainage pathway: a case report. *Ophthalmic Surg* 1982; 13:377-9.
3. De La Luz Orozco-Covarrubias MA, Salazar-Leon JA, Tamayo-Sanchez L, et al. Dermoid cyst connected with the lacrimal canaliculus. *Pediatr Dermatol* 1993;10:69-70.