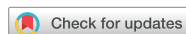

Original Article

Endocrinology,
Nutrition & Metabolism



OPEN ACCESS

Received: Sep 15, 2017

Accepted: Nov 29, 2017

Address for Correspondence:

Bo Hyun Kim, MD, PhD

Division of Endocrinology and Metabolism,
Department of Internal Medicine, Pusan
National University School of Medicine, 179
Gudeok-ro, Seo-gu, Busan 49241,
Republic of Korea.
E-mail: pons71@hanmail.net

© 2018 The Korean Academy of Medical
Sciences.

This is an Open Access article distributed
under the terms of the Creative Commons
Attribution Non-Commercial License (<https://creativecommons.org/licenses/by-nc/4.0/>)
which permits unrestricted non-commercial
use, distribution, and reproduction in any
medium, provided the original work is properly
cited.

ORCID iDs

Hyereen Kim
<https://orcid.org/0000-0001-8551-7516>
Bo Hyun Kim
<https://orcid.org/0000-0001-9632-9457>
Young Keum Kim
<https://orcid.org/0000-0002-0474-0976>
Jeong Mi Kim
<https://orcid.org/0000-0003-1250-9835>
Seo Young Oh
<https://orcid.org/0000-0001-5244-3661>
Eun Heui Kim
<https://orcid.org/0000-0001-9000-4870>
Min Jin Lee
<https://orcid.org/0000-0002-4351-789X>
Jong Ho Kim
<https://orcid.org/0000-0001-9781-1376>

Prevalence of *BRAF*^{V600E} Mutation in Follicular Variant of Papillary Thyroid Carcinoma and Non-Invasive Follicular Tumor with Papillary-Like Nuclear Features (NIFTP) in a *BRAF*^{V600E} Prevalent Area

Hyereen Kim ¹, Bo Hyun Kim ^{1,2,3}, Young Keum Kim ^{1,4}, Jeong Mi Kim ^{1,2},
Seo Young Oh ^{1,2}, Eun Heui Kim ^{1,2}, Min Jin Lee ^{1,2}, Jong Ho Kim ^{1,2},
Yun Kyung Jeon ^{1,2}, Sang Soo Kim ^{1,2}, Byung Joo Lee ^{1,5}, Yong Ki Kim ^{1,6},
and In Joo Kim ^{2,3}

¹Hyereen Kim's Internal Medicine Clinic, Yangsan, Korea

²Department of Internal Medicine, Pusan National University School of Medicine, Busan, Korea

³Biomedical Research Institute, Pusan National University Hospital, Busan, Korea

⁴Department of Pathology, Pusan National University Hospital and Pusan National University School of Medicine, Busan, Korea

⁵Department of Otolaryngology, Pusan National University School of Medicine, Busan, Korea

⁶Kim Yong Ki Internal Medicine Clinic, Busan, Korea

ABSTRACT



Background: *BRAF*^{V600E} mutation status and prevalence of non-invasive follicular thyroid neoplasm with papillary-like nuclear features (NIFTP) has not yet been reported in Korea. The aim of this study was to investigate the significance of the *BRAF*^{V600E} mutation in the follicular variant of papillary thyroid carcinoma (FVPTC) and to determine the prevalence of NIFTP in *BRAF*^{V600E} mutation-prevalent Korean patients.

Methods: This study retrospectively analyzed 1,417 consecutive patients who underwent total thyroidectomy with routine prophylactic central lymph node dissection for papillary thyroid carcinoma (PTC). *BRAF*^{V600E} mutation analysis was performed routinely using multiplex polymerase chain reaction by applying dual priming oligonucleotide. Clinicopathological characteristics and ultrasonographic findings were compared between *BRAF*^{V600E} mutation-positive and -negative groups for FVPTC. Pathologists reviewed the pathology slides according to consensus diagnostic criteria for the encapsulated FVPTC and NIFTP.

Results: The prevalence of the *BRAF*^{V600E} mutation in all subtypes of PTC was 61.0% (861/1,411). FVPTC presented a *BRAF*^{V600E} mutation rate of 27.3%. The FVPTC patients with *BRAF*^{V600E} mutation were older than those with no *BRAF*^{V600E} mutation ($P = 0.021$). The prevalence of NIFTP was 0.18% among all PTC patients (2/1,411) and the proportion of NIFTP among FVPTC was 9.1% (2/22).

Conclusion: The *BRAF*^{V600E} mutation is prevalent in Korean patients with FVPTC in a region with high frequency of the *BRAF*^{V600E} mutation and very low prevalence of NIFTP compared with that reported in western studies.

Keywords: Thyroid Carcinoma; B-type Raf (BRAF); Follicular Variant; Papillary Carcinoma; NIFTP

Yun Kyung Jeon <https://orcid.org/0000-0002-4319-5181>Sang Soo Kim <https://orcid.org/0000-0002-9687-8357>Byung Joo Lee <https://orcid.org/0000-0001-7091-6688>Yong Ki Kim <https://orcid.org/0000-0001-9321-1736>In Joo Kim <https://orcid.org/0000-0003-1307-6146>**Disclosure**

The authors have no potential conflicts of interest to disclose.

Author Contributions

Conceptualization: Kim BH, Kim IJ.

Investigation: Kim H, Kim JM, Kim YK, Kim EH, Lee MJ, Kim JH. Formal analysis: Kim H, Jeon YK, Kim SS. Writing - original draft: Kim H, Kim BH. Writing - review & editing: Kim BH, Lee BJ, Kim YK.

INTRODUCTION

The follicular variant of papillary thyroid carcinoma (FVPTC) is the second most common subtype of papillary thyroid carcinoma (PTC) after the classical type, constituting approximately 20% (11.8%–41%) of all PTCs and the incidence of FVPTC has increased.¹⁻⁴ FVPTC is a unique clinical entity and it has hybrid characteristics of classical PTC and follicular thyroid carcinoma (FTC) or adenoma.^{5,6} FVPTC can be classified into infiltrative and encapsulated FVPTC.⁶ The infiltrative FVPTC often have BRAF mutations, whereas the encapsulated FVPTC most commonly have RAS mutations.⁷ The encapsulated FVPTC can be reclassified into invasive and non-invasive encapsulated FVPTC according to presence of capsular or vascular invasion.⁶ Recently, Nikiforov et al.⁸ reported that non-invasive encapsulated FVPTC behave in an indolent fashion, and therefore should not be considered malignant. Thus, non-invasive encapsulated FVPTC was renamed as “Non-invasive follicular thyroid neoplasm with papillary-like nuclear features” (NIFTP).

To our knowledge, there has been no report about BRAF^{V600E} status and prevalence or incidence of NIFTP among all PTC in Korea. Nikiforov et al.⁸ suggested that estimated worldwide incidence of NIFTP was 18.6% among all PTC and the most common clonal molecular alterations were RAS mutations. Although one case of BRAF^{K601E} mutation was detected, there was no BRAF^{V600E} mutation.

However, in Korea, most thyroid cancer is classical PTC, and the BRAF^{V600E} mutation is highly prevalent.⁹⁻¹² Consequently, the prevalence of FVPTC is relatively low (2.7%–14.2%) compared with other countries.¹³⁻¹⁵ Recently, Hahn et al.¹⁶ firstly reported that the proportion of NIFTP among FVPTC in three tertiary medical centers of Korea for 7 years was 16.3% (34/208). However, they did not report the total number of patients with PTC.¹⁶ Therefore, they could not show the estimated incidence of NIFTP in Korea.

The aim of this study was to investigate the BRAF^{V600E} mutation status of FVPTC and to determine prevalence of NIFTP after reclassifying non-invasive encapsulated FVPTC as NIFTP by careful histopathological review based on diagnostic criteria of NIFTP in Korean patients.

METHODS**Patients and clinicopathological data**

From January 2011 to December 2012, 1,417 subjects (154 men, 1,263 women) who underwent total thyroidectomy due to PTC at Pusan National University Hospital were enrolled in the current study. In cases of multifocal PTC, only the largest tumor was included. Either synchronous PTC and FTC or PTC and medullary thyroid cancer were excluded in this study. Prophylactic central compartment neck node dissection was routinely performed in all patients, and lateral neck dissection was done in patients with pathologically confirmed lateral lymph node metastasis (LNM) or clinically suspected LNM on preoperative imaging or intraoperative examination. Electronic records that include tumor size, extrathyroidal extension (ETE), LNM, BRAF^{V600E} mutation and the pathological subtype of PTC were reviewed to collect the clinicopathological features. Two pathologists specializing in thyroid pathology reviewed and interpreted the pathology slides according to consensus diagnostic criteria for the encapsulated FVPTC and NIFTP.⁸ Cancer staging was conducted according to the criteria outlined by the American Joint Committee on Cancer 2010, 7th edition.

BRAF^{V600E} mutation evaluation

BRAF^{V600E} analysis was performed routinely in paraffin-embedded thyroidectomy specimen sections from the removed thyroid cancer tissue. Representative sections from tumors were dissected on the glass using a clean blade and placed in a 1.5 mL tube. Genomic DNA was isolated from five to ten µm thick tissue sections using the QIAamp DNA Mini kit (Qiagen, Chatsworth, CA, USA) according to the manufacturer's instructions. For BRAF^{V600E} mutation detection, we used Seeplex BRAF ACE detection system by applying dual priming oligonucleotide (DPO) technology (Seegene, Seoul, Korea). DPO-based multiplex polymerase chain reaction (PCR) analysis can reportedly detect the presence of BRAF^{V600E} in as few as 2% of cells in a fine needle aspiration (FNA) specimen of thyroid nodules.¹⁷ In the DPO-based multiplex PCR analysis, five successive deoxyinosine linkers were used for 3'-end sensitization of the primer to enhance the specificity for single-base substitution. The shorter 3'-portion is linked to the longer 5'-portion by five successive deoxyinosine linkers. The binding energy of the shorter 3'-portion alone is sufficiently low to distinguish a single-base difference, which enhances the specificity of allele-specific PCR.¹⁸

Ultrasonography image analysis

All patients were investigated by ultrasound (US) (LOGIQ E9; General Electric, Waukesha, WI, USA) within a month before surgery in Pusan National University Hospital, and two endocrinologists (B.H.K, J.H.K) with at least 5 years of experience with thyroid US and FNA reviewed the results blinded to the clinical information. Internal content, echogenicity, shape, calcification, and margin of each nodule were evaluated according to the consensus statement and recommendations by the American Thyroid Association.¹⁹ Halo sign or hypoechoic rim surrounding nodule was also reviewed because it was histologically comprised of the nodule capsule or pseudo-capsule.²⁰ The nodules were categorized as follows: low or indeterminate suspicion versus high suspicion.

Statistical analysis

Statistical analyses were performed using commercially available software (MedCalc 12.3; MedCalc Software, Mariakerke, Belgium). Continuous data are expressed as mean ± standard deviation for normally distributed values. Categorical data were presented as frequency and percentage. Independent t-test, χ^2 test, and Fisher's exact test were used to analyze the demographic features. For FVPTC, patients were classified into two groups, BRAF^{V600E} mutation-positive or -negative. In addition, FVPTC were separated into two major classes: infiltrative and encapsulated. Various clinicopathological characteristics were evaluated using the χ^2 test, Fisher's exact test, or Mann-Whitney test between the two groups as appropriate. Statistical significance was defined as $P < 0.05$.

Ethics statement

This study was approved by the Institutional Review Board of Pusan National University Hospital (approval number: 1110-004-001). Informed consent was waived by the board.

RESULTS

Clinicopathological characteristics according to histological subtype of PTC

Clinicopathological characteristics of patients and tumor are shown in Table 1. Rare variant PTCs (1 insular thyroid cancer, 4 mixed type) were excluded in this study due to their small numbers. Therefore, this analysis included 1,411 patients in total. The classic type, FVPTC,

Table 1. Clinicopathological characteristics according to histologic subtypes of PTC

Characteristics	Classical (n = 1,374)	Follicular variant (n = 22)	Diffuse sclerosing variant (n = 10)	Tall cell variant (n = 5)
Age, yr	50.0 ± 11.2	53.8 ± 9.6	43.7 ± 15.1 ^{a,b}	53.0 ± 21.7 ^c
Sex, female	1,234 (89.8)	16 (72.7)	7 (70.0) ^a	3 (60.0) ^a
Tumor size, cm	0.9 ± 0.6	1.4 ± 1.3 ^a	2.1 ± 1.2 ^{a,b}	2.0 ± 1.1 ^{a,b}
ETE	520 (37.8)	7 (31.8)	8 (80.0) ^{a,b}	3 (60.0) ^{a,b}
LNM	518 (37.7)	4 (18.2) ^a	9 (90.0) ^{a,b}	3 (60.0) ^{a,b}
Advanced stage	393 (28.6)	9 (40.9)	9 (90.0) ^{a,b}	4 (80.0) ^{a,b}
BRAF ^{V600E} mutation	850 (61.9)	6 (27.3) ^a	2 (20.0) ^a	3 (60.0) ^{b,c}

Statistical significance was tested by the χ^2 test. Data are expressed as mean ± standard deviation and frequency (%) for categorical variables.

PTC = papillary thyroid carcinoma, ETE = extrathyroidal extension, LNM = lymph node metastasis, Advanced stage = American Joint Committee on Cancer (AJCC) stage III + IV.

^aP < 0.05 vs. conventional PTC; ^bP < 0.05 vs. follicular variant PTC; ^cP < 0.05 vs. diffuse sclerosing variant PTC.

diffuse sclerosing variant (DSV), and tall cell variant (TCV) represented 1,374 (97.3%), 22 (1.6%), 10 (0.7%), and 5 (0.35%) patients, respectively. The mean age was 50.6 ± 11.2 years (range, 14–81 years). The mean tumor size was 0.89 ± 0.64 cm (range, 0.3–6.0 cm). The percentage of patients with papillary thyroid microcarcinoma (PTMC) was 72.9% (1,001/1,374) in classical PTC. DSV PTC was more highly associated with young age (mean 43.7 years) compared with classical PTC and the other variant of PTC. In addition, DSV PTC and TCV PTC were associated with male patients compared with classical PTC (all *P* value < 0.05). The aggressive variants of PTC (DSV and TCV) showed a larger tumor size, and higher occurrence of ETE, LNM, and advanced stage than did classical and FVPTC (all *P* value < 0.05) (Table 1).

BRAF^{V600E} mutation status according to histologic subtype of PTC

The prevalence of the BRAF^{V600E} mutation in all subtypes of PTC is 61.0% (861/1,411). The BRAF^{V600E} mutation was most commonly detected in conventional PTC (61.9%) and TCV PTC (60%). However, FVPTC and DSV PTC presented a BRAF^{V600E} mutation rate of 27.3% and 20%, respectively (Table 1).

Clinicopathological and ultrasonographic features according to BRAF^{V600E} mutation status in FVPTC

The clinicopathological and ultrasonographic characteristics of BRAF^{V600E} mutation-positive and -negative FVPTC are summarized in Table 2. FVPTC patients with BRAF^{V600E} mutation were older than those with no BRAF^{V600E} mutation (*P* = 0.021). The FVPTC patients with BRAF^{V600E} mutation had more LNM, advanced stage, and ultrasonographic high suspicion category than those with no BRAF^{V600E} mutation, but those associations were not statistically significant. FVPTC patients with no BRAF^{V600E} mutation showed more chance, although statistically not significant, of encapsulation and halo sign than those with BRAF^{V600E} mutation.

Table 2. Clinicopathological and sonographic characteristics of FVPTC according to BRAF^{V600E} mutation

Characteristics	BRAF ^{V600E} positive FVPTC (n = 6)	BRAF ^{V600E} negative FVPTC (n = 16)	<i>P</i> value
Sex, female	5 (83.3)	11 (68.8)	0.634
Age, yr	60.2 ± 3.1	51.4 ± 11.9	0.021
Tumor size, cm	1.0 ± 0.4	1.6 ± 1.5	0.711
ETE	2 (33.3)	5 (31.3)	1.000
LNM	2 (33.3)	2 (12.5)	0.292
Encapsulation	0 (0)	3 (18.8)	0.532
Advanced stage	3 (50.0)	6 (37.5)	0.655
Halo sign	2 (33.3)	7 (43.8)	1.000
ATA high suspicion	3 (50.0)	2 (12.5)	0.292

Data are expressed as mean ± standard deviation and frequency (%) for categorical variables.

FVPTC = follicular variant papillary thyroid carcinoma, ETE = extrathyroidal extension, LNM = lymph node metastasis, Advanced stage = American Joint Committee on Cancer (AJCC) stage III + IV, ATA = American Thyroid Association.

Table 3. Clinicopathological characteristics of FVPTC according to presence of encapsulation

Characteristics	Encapsulated FVPTC (n = 3)	Infiltrative FVPTC (n = 19)	P value
Sex			1.000
Male	1 (33.3)	5 (26.3)	
Female	2 (66.6)	14 (73.7)	
Age, yr	44.7 ± 16.6	55.2 ± 9.7	0.388
Old age (> 45 yr)	2 (66.6)	16 (84.2)	0.470
Tumor size, cm	2.7 ± 2.9	1.2 ± 0.9	0.065
ETE	0 (0)	7 (36.8)	0.523
LNM	0 (0)	4 (21.1)	1.000
Multifocality	0 (0)	7 (36.8)	0.709
Advanced stage	1 (33.1)	8 (42.1)	1.000
BRAF ^{V600E} mutation	0 (0)	6 (31.6)	0.532
Halo sign	3 (100)	6 (31.6)	0.055
ATA high suspicion	0 (0)	5 (26.3)	1.000

Data are expressed as mean ± standard deviation and frequency (%) for categorical variables.

FVPTC = follicular variant papillary thyroid carcinoma, ETE = extrathyroidal extension, LNM = lymph node metastasis, Advanced stage = American Joint Committee on Cancer (AJCC) stage III + IV, ATA = American Thyroid Association.

Correlation between encapsulation status and clinicopathological characteristics in FVPTC

The clinicopathological characteristics of encapsulated FVPTC and infiltrative FVPTC are summarized in **Table 3**. Encapsulated FVPTC was marginally associated with large tumor size ($P = 0.065$) and positive halo sign ($P = 0.055$) compared with infiltrative FVPTC due to small sample size. Infiltrative FVPTC had a higher frequency of ETE, LNM, BRAF^{V600E} mutation, high suspicious ultrasonographic features, and advanced stage compared with encapsulated FVPTC, however, there was no statistical significance (all P value > 0.05).

Prevalence and clinical outcome of NIFTP

The prevalence of NIFTP in this study was 0.18% among all PTC patients (2/1,411) and proportion of NIFTP among FVPTC was 9.1% (2/22). The proportion of NIFTP among encapsulated FVPTC was 66.6% (2/3). There was no BRAF^{V600E} mutation in NIFTP. Clinical outcomes and details of follow-up for 2 patients with NIFTP are summarized in **Table 4**. These two patients were treated with total thyroidectomy with prophylactic central lymph node dissection only, and neither of them received radioactive iodine therapy. Two patients had no adverse events and no evidence of disease during approximately 4 years follow-up period.

Table 4. Clinical outcome and details of follow-up for 2 patients in NIFTP

Parameters	Patient 1	Patient 2
Age, yr	50	58
Sex	Female	Female
Tumor size, cm	0.7	1.5
FNA cytology result	AUS	PTC
ATA US feature	Low suspicion	Low suspicion
Halo sign	Yes	Yes
Type of surgery	Total thyroidectomy	Total thyroidectomy
LNM	None	None
TNM stage	I	I
RAI therapy	None	None
FU duration, yr	4.5	4.1
No evidence of disease	Yes	Yes
BRAF ^{V600E} mutation	Negative	Negative

NIFTP = non-invasive follicular thyroid neoplasm with papillary-like nuclear features, FNA = fine needle aspiration, ATA = American Thyroid Association, US = ultrasonography, AUS = atypia of undetermined significance, PTC = papillary thyroid carcinoma, LNM = lymph node metastasis, TNM = tumor, node, metastasis, RAI = radioactive iodine, FU = follow up.

DISCUSSION

We have evaluated the status of the *BRAF*^{V600E} mutation of FVPTC to determine the prevalence of NIFTP in a *BRAF*^{V600E} mutation-prevalent area. The classical PTC and FVPTC represented 97.4% and 1.6% of all PTC patients, respectively. The prevalence of the *BRAF*^{V600E} mutation was 61.9% in classical PTC and 27.3% in FVPTC. *BRAF*^{V600E} mutation-positive FVPTC was more highly associated with old age than *BRAF*^{V600E} mutation-negative FVPTC. Encapsulated FVPTC was marginally associated with large tumor size and positive halo sign compared with infiltrative FVPTC. In the current study, the prevalence of NIFTP was 0.18% among all PTC patients. The proportion of NIFTP among FVPTC and encapsulated FVPTC was 9.1% and 66.6%, respectively. There was no *BRAF*^{V600E} mutation in NIFTP.

FVPTC is the most common variant of PTC and it has different clinicopathological characteristics and molecular alterations compared to classical PTC. Most PTCs such as classic or TCVs with the *BRAF*^{V600E} mutation showed a papillary growth pattern, whereas the *BRAF*^{V600E} mutation was uncommon in FVPTC, but detection rate of RAS mutation was high compared to classical PTC.^{14,21} In addition, the infiltrative FVPTC often have *BRAF* mutations, whereas the encapsulated FVPTC most commonly have RAS mutations.⁷

The prevalence of the *BRAF*^{V600E} mutation which is the most common genetic alteration in PTC, has wide variation (30%–90%) depending on detection method, ethnic and geographic backgrounds, and study populations.^{10,22–25} The increase in both the prevalence of the *BRAF*^{V600E} mutation, in accordance with iodine consumption, and in the number of cases of PTC has been reported in different countries.^{26–28} Particularly, in Korea, where iodine consumption is very high, the prevalence of the *BRAF*^{V600E} mutation in PTC is much higher than that in western countries.^{13–15} In the present study, the prevalence of the *BRAF*^{V600E} mutation was 61.9% in classical PTC, 27.3% in FVPTC. Although the reported prevalence of the *BRAF*^{V600E} mutation in FVPTC has varied (17%–40%) in different detection analyses and study populations, some Korean studies on the *BRAF*^{V600E} mutation of FVPTC showed higher detection rates (40%) than those of western countries (17%–31%).^{14,29,30} However, recent studies suggest that almost one third of FVPTC harbor *BRAF* mutations.^{13,31} These data are accordant with the result of the present study, in which 27.3% of FVPTC cases were *BRAF*^{V600E} mutation-positive. The reason for the high prevalence of the *BRAF*^{V600E} mutation in Korean patients with PTC is still unclear. A possible explanation is that iodine-rich diets or chronic thyroiditis in the Korean population may be associated with the *BRAF*^{V600E} mutation.²⁶ In view of the positive association with high iodine consumption, a recent Chinese report showed that the prevalence of the *BRAF*^{V600E} mutation in PTC was significantly higher in iodine-rich areas than in iodine-normal areas in China.³¹ In contrast, a very recent study showed no differences in genetic alterations of PTC from iodine-rich (Japan) and iodine-deficient (Vietnam) countries.³² Thus, there is still no consensus regarding the association of iodine intake and the high prevalence of the *BRAF*^{V600E} mutation in patients with PTC in iodine sufficient areas. Therefore, these associations should be further elucidated in future studies.

Recent studies reported that an association exists between the *BRAF*^{V600E} mutation and poor clinicopathological outcomes of FVPTC.^{13,29} However, in the current study, only old age was significantly associated with *BRAF*^{V600E} mutant FVPTC compared with *BRAF*^{V600E} mutation-negative FVPTC. Some findings in the present study conflict with a report that the *BRAF*^{V600E} mutation was associated with poor prognostic factors in FVPTC.^{13,29} However, there is still

debate about the correlation between *BRAF*^{V600E} mutation status and poor clinicopathological features in FVPTC due to limited studies.

The prognosis of FVPTC seems to be more dependent on whether it is completely encapsulated or infiltrative than on *BRAF*^{V600E} mutation status. The infiltrative FVPTC was more likely to have ETE and LNM and generally behaved like classical PTC. In contrast, the encapsulated, noninvasive FVPTC behaved in an indolent fashion, similar to benign follicular adenomas. The encapsulated FVPTC with capsular or vascular invasion behaved more like a FTC.^{5,6} In the current study, infiltrative FVPTC showed a higher frequency of LNM. Although the frequency of ETE and advanced stage was higher in infiltrative FVPTC than in encapsulated FVPTC, this did not reach statistical significance due to small sample size. There was no statistical difference between *BRAF*^{V600E} mutation and infiltrative FVPTC because only one (50%) among two patients had the *BRAF*^{V600E} mutation in this study.

After Nikiforov et al.⁸ reported a first new nomenclature and estimated worldwide incidence of NIFTP (18.6% among all PTC), a multicenter study from the 9 institutions from 6 Asian countries including Korea was very recently reported that the mean calculated as an average of NIFTP was 1.5% (range 0%–4.7%).³³ A single institution study from Japan also reported that incidence of noninvasive encapsulated FVPTC (EFVPTC) was 0.4% of all PTC cases.³⁴ In the current our study, the prevalence of NIFTP was 0.18% among all PTC patients in accordance with these Asian studies. Such a huge discrepancy of incidence of NIFTP between Western and Asian studies might be considered by several factors such as geographic and ethnic differences in type of thyroid cancers, incidences of FVPTC, differences in histologic interpretation, and variable diagnostic threshold.³⁴ Therefore, low rate of NIFTP in Asian countries should be further elucidated in future large studies.

This study has some limitations. First, the retrospective single-center nature of our study may limit the generalization of our results. Second, although the total sample size of the study was large, only a limited number of FVPTC cases were included in this study. The prevalence of FVPTC (4.9%–41.2%) was varied according to study populations and methods.³⁵ Although FVPTC has been increasingly diagnosed in recent years, a previous large population study in Korea demonstrated very low prevalence of FVPTC (2.6%), this result was concordant with our result (1.6%).¹⁴ In addition, FVPTC has more benign ultrasonographic features than classical PTC, making the diagnostic efficacy lower for FVPTC. Because ultrasonographic differences between FVPTC and benign adenoma or FTC are not always clear, occasionally a FVPTC will mistakenly be classified as a benign follicular adenoma.³⁶ Therefore, selection bias may have existed. The lower rate of suspicious findings in FVPTC lesions may have caused less evaluation by FNA biopsy (FNAB), resulting in no necessity of surgery. In addition, benign findings of ultrasonography of FVPTC lesions may have caused evaluation of larger FVPTC lesions by FNAB, resulting in the detection of these lesions at a later stage. In view of this, our study included many PTMC patients (n = 1,034, 73.3%). The percentage of FVPTC after excluding PTMC was 5.8%. Third, considerable inter-observer variability in the diagnosis of FVPTC based on histology was not considered in this study. The diagnosis of FVPTC can be quite difficult and controversial. Fourth, recurrence or survival outcomes could not be evaluated in relation to *BRAF*^{V600E} mutation status because of the relatively short follow-up period. Lastly, we could not evaluate a more detailed molecular profile by analyzing RAS mutation because it was not available in our hospital. In addition, although *BRAF*^{K601E} is known as having high association with encapsulated FVPTC, we did not perform *BRAF*^{K601E} analysis. Despite these limitations, the strength of this study is that *BRAF*^{V600E} mutation

analysis was performed routinely in all consecutive patients with PTC who underwent total thyroidectomy and routine prophylactic central compartment neck node dissection in the BRAF^{V600E} mutation-prevalent area.

In conclusion, this study has found that the BRAF^{V600E} mutation is prevalent in Korean patients with FVPTC in a region with high frequency of the BRAF^{V600E} mutation and very low prevalence of NIFTP compared with western studies. Further prospective research involving a large number of cases is required to conclusively establish the prevalence of NIFTP from Asian countries especially in Korea.

REFERENCES

1. Lang BH, Lo CY, Chan WF, Lam AK, Wan KY. Classical and follicular variant of papillary thyroid carcinoma: a comparative study on clinicopathologic features and long-term outcome. *World J Surg* 2006;30(5):752-8.
[PUBMED](#) | [CROSSREF](#)
2. Passler C, Prager G, Scheuba C, Niederle BE, Kaserer K, Zettinig G, et al. Follicular variant of papillary thyroid carcinoma: a long-term follow-up. *Arch Surg* 2003;138(12):1362-6.
[PUBMED](#) | [CROSSREF](#)
3. Zidan J, Karen D, Stein M, Rosenblatt E, Basher W, Kuten A. Pure versus follicular variant of papillary thyroid carcinoma: clinical features, prognostic factors, treatment, and survival. *Cancer* 2003;97(5):1181-5.
[PUBMED](#) | [CROSSREF](#)
4. Yu XM, Schneider DF, Levenson G, Chen H, Sippel RS. Follicular variant of papillary thyroid carcinoma is a unique clinical entity: a population-based study of 10,740 cases. *Thyroid* 2013;23(10):1263-8.
[PUBMED](#) | [CROSSREF](#)
5. Daniels GH. Follicular variant of papillary thyroid carcinoma: hybrid or mixture? *Thyroid* 2016;26(7):872-4.
[PUBMED](#) | [CROSSREF](#)
6. Liu J, Singh B, Tallini G, Carlson DL, Katabi N, Shaha A, et al. Follicular variant of papillary thyroid carcinoma: a clinicopathologic study of a problematic entity. *Cancer* 2006;107(6):1255-64.
[PUBMED](#) | [CROSSREF](#)
7. Rivera M, Ricarte-Filho J, Knauf J, Shaha A, Tuttle M, Fagin JA, et al. Molecular genotyping of papillary thyroid carcinoma follicular variant according to its histological subtypes (encapsulated vs infiltrative) reveals distinct BRAF and RAS mutation patterns. *Mod Pathol* 2010;23(9):1191-200.
[PUBMED](#) | [CROSSREF](#)
8. Nikiforov YE, Seethala RR, Tallini G, Baloch ZW, Basolo F, Thompson LD, et al. Nomenclature revision for encapsulated follicular variant of papillary thyroid carcinoma: a paradigm shift to reduce overtreatment of indolent tumors. *JAMA Oncol* 2016;2(8):1023-9.
[PUBMED](#) | [CROSSREF](#)
9. Kim TY, Kim WG, Kim WB, Shong YK. Current status and future perspectives in differentiated thyroid cancer. *Endocrinol Metab* 2014;29(3):217-25.
[PUBMED](#) | [CROSSREF](#)
10. Kim TY, Kim WB, Rhee YS, Song JY, Kim JM, Gong G, et al. The BRAF mutation is useful for prediction of clinical recurrence in low-risk patients with conventional papillary thyroid carcinoma. *Clin Endocrinol (Oxf)* 2006;65(3):364-8.
[PUBMED](#) | [CROSSREF](#)
11. Jeong D, Jeong Y, Park JH, Han SW, Kim SY, Kim YJ, et al. BRAF (V600E) mutation analysis in papillary thyroid carcinomas by peptide nucleic acid clamp real-time PCR. *Ann Surg Oncol* 2013;20(3):759-66.
[PUBMED](#) | [CROSSREF](#)
12. Kwon MJ, Lee SE, Kang SY, Choi YL. Frequency of KRAS, BRAF, and PIK3CA mutations in advanced colorectal cancers: Comparison of peptide nucleic acid-mediated PCR clamping and direct sequencing in formalin-fixed, paraffin-embedded tissue. *Pathol Res Pract* 2011;207(12):762-8.
[PUBMED](#) | [CROSSREF](#)
13. Chai YJ, Kim SJ, Kim SC, Koo DH, Min HS, Lee KE, et al. BRAF mutation in follicular variant of papillary thyroid carcinoma is associated with unfavourable clinicopathological characteristics and malignant features on ultrasonography. *Clin Endocrinol (Oxf)* 2014;81(3):432-9.
[PUBMED](#) | [CROSSREF](#)

14. Lim JY, Hong SW, Lee YS, Kim BW, Park CS, Chang HS, et al. Clinicopathologic implications of the *BRAF*(V600E) mutation in papillary thyroid cancer: a subgroup analysis of 3130 cases in a single center. *Thyroid* 2013;23(11):1423-30.
[PUBMED](#) | [CROSSREF](#)
15. Min HS, Lee C, Jung KC. Correlation of immunohistochemical markers and *BRAF* mutation status with histological variants of papillary thyroid carcinoma in the Korean population. *J Korean Med Sci* 2013;28(4):534-41.
[PUBMED](#) | [CROSSREF](#)
16. Hahn SY, Shin JH, Lim HK, Jung SL, Oh YL, Choi IH, et al. Preoperative differentiation between noninvasive follicular thyroid neoplasm with papillary-like nuclear features (NIFTP) and non-NIFTP. *Clin Endocrinol (Oxf)* 2017;86(3):444-50.
[PUBMED](#) | [CROSSREF](#)
17. Kwak JY, Kim EK, Kim JK, Han JH, Hong SW, Park TS, et al. Dual priming oligonucleotide-based multiplex PCR analysis for detection of *BRAF*V600E mutation in FNAB samples of thyroid nodules in *BRAF*V600E mutation-prevalent area. *Head Neck* 2010;32(4):490-8.
[PUBMED](#)
18. Kim SW, Lee JI, Kim JW, Ki CS, Oh YL, Choi YL, et al. *BRAF*V600E mutation analysis in fine-needle aspiration cytology specimens for evaluation of thyroid nodule: a large series in a *BRAF*V600E-prevalent population. *J Clin Endocrinol Metab* 2010;95(8):3693-700.
[PUBMED](#) | [CROSSREF](#)
19. Haugen BR, Alexander EK, Bible KC, Doherty GM, Mandel SJ, Nikiforov YE, et al. 2015 American Thyroid Association Management Guidelines for adult patients with thyroid nodules and differentiated thyroid cancer: the American Thyroid Association Guidelines Task Force on Thyroid Nodules and Differentiated Thyroid Cancer. *Thyroid* 2016;26(1):1-133.
[PUBMED](#) | [CROSSREF](#)
20. Shin JH, Baek JH, Chung J, Ha EJ, Kim JH, Lee YH, et al. Ultrasonography diagnosis and imaging-based management of thyroid nodules: revised Korean Society of Thyroid Radiology Consensus statement and recommendations. *Korean J Radiol* 2016;17(3):370-95.
[PUBMED](#) | [CROSSREF](#)
21. Smith RA, Salajegheh A, Weinstein S, Nassiri M, Lam AK. Correlation between *BRAF* mutation and the clinicopathological parameters in papillary thyroid carcinoma with particular reference to follicular variant. *Hum Pathol* 2011;42(4):500-6.
[PUBMED](#) | [CROSSREF](#)
22. Cohen Y, Xing M, Mambo E, Guo Z, Wu G, Trink B, et al. *BRAF* mutation in papillary thyroid carcinoma. *J Natl Cancer Inst* 2003;95(8):625-7.
[PUBMED](#) | [CROSSREF](#)
23. Fukushima T, Suzuki S, Mashiko M, Ohtake T, Endo Y, Takebayashi Y, et al. *BRAF* mutations in papillary carcinomas of the thyroid. *Oncogene* 2003;22(41):6455-7.
[PUBMED](#) | [CROSSREF](#)
24. Xing M, Alzahrani AS, Carson KA, Shong YK, Kim TY, Viola D, et al. Association between *BRAF*V600E mutation and recurrence of papillary thyroid cancer. *J Clin Oncol* 2015;33(1):42-50.
[PUBMED](#) | [CROSSREF](#)
25. Kim SK, Kim DL, Han HS, Kim WS, Kim SJ, Moon WJ, et al. Pyrosequencing analysis for detection of a *BRAF*V600E mutation in an FNAB specimen of thyroid nodules. *Diagn Mol Pathol* 2008;17(2):118-25.
[PUBMED](#) | [CROSSREF](#)
26. Hong AR, Lim JA, Kim TH, Choi HS, Yoo WS, Min HS, et al. The frequency and clinical implications of the *BRAF*(V600E) mutation in papillary thyroid cancer patients in Korea over the past two decades. *Endocrinol Metab* 2014;29(4):505-13.
[PUBMED](#) | [CROSSREF](#)
27. Romei C, Fugazzola L, Puxeddu E, Frasca F, Viola D, Muzza M, et al. Modifications in the papillary thyroid cancer gene profile over the last 15 years. *J Clin Endocrinol Metab* 2012;97(9):E1758-65.
[PUBMED](#) | [CROSSREF](#)
28. Mathur A, Moses W, Rahbari R, Khanafshar E, Duh QY, Clark O, et al. Higher rate of *BRAF* mutation in papillary thyroid cancer over time: a single-institution study. *Cancer* 2011;117(19):4390-5.
[PUBMED](#) | [CROSSREF](#)
29. Shin DY, Kim KJ, Chang S, Kim H, Hwang S, Kim W, et al. Follicular variant of papillary thyroid carcinoma with B-type Raf(V600E) showing higher frequency of suspicious sonographic features and multifocality. *Head Neck* 2015;37(11):1590-5.
[PUBMED](#) | [CROSSREF](#)

30. McFadden DG, Dias-Santagata D, Sadow PM, Lynch KD, Lubitz C, Donovan SE, et al. Identification of oncogenic mutations and gene fusions in the follicular variant of papillary thyroid carcinoma. *J Clin Endocrinol Metab* 2014;99(11):E2457-62.
[PUBMED](#) | [CROSSREF](#)
31. Guan H, Ji M, Bao R, Yu H, Wang Y, Hou P, et al. Association of high iodine intake with the T1799A BRAF mutation in papillary thyroid cancer. *J Clin Endocrinol Metab* 2009;94(5):1612-7.
[PUBMED](#) | [CROSSREF](#)
32. Vuong HG, Kondo T, Oishi N, Nakazawa T, Mochizuki K, Inoue T, et al. Genetic alterations of differentiated thyroid carcinoma in iodine-rich and iodine-deficient countries. *Cancer Med* 2016;5(8):1883-9.
[PUBMED](#) | [CROSSREF](#)
33. Bychkov A, Hirokawa M, Jung CK, Liu Z, Zhu Y, Hong SW, et al. Low rate of noninvasive follicular thyroid neoplasm with papillary-like nuclear features in Asian practice. *Thyroid* 2017;27(7):983-4.
[PUBMED](#) | [CROSSREF](#)
34. Liu Z, Zhou G, Nakamura M, Koike E, Li Y, Ozaki T, et al. Encapsulated follicular thyroid tumor with equivocal nuclear changes, so-called well-differentiated tumor of uncertain malignant potential: a morphological, immunohistochemical, and molecular appraisal. *Cancer Sci* 2011;102(1):288-94.
[PUBMED](#) | [CROSSREF](#)
35. Yang J, Gong Y, Yan S, Shi Q, Zhu J, Li Z, et al. Comparison of the clinicopathological behavior of the follicular variant of papillary thyroid carcinoma and classical papillary thyroid carcinoma: a systematic review and meta-analysis. *Mol Clin Oncol* 2015;3(4):753-64.
[PUBMED](#) | [CROSSREF](#)
36. Jeon EJ, Jeong YJ, Park SH, Cho CH, Shon HS, Jung ED. Ultrasonographic characteristics of the follicular variant papillary thyroid cancer according to the tumor size. *J Korean Med Sci* 2016;31(3):397-402.
[PUBMED](#) | [CROSSREF](#)