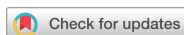

Original Article  
Oncology & Hematology



# Procarbazine and CCNU Chemotherapy for Recurrent Glioblastoma with MGMT Promoter Methylation

Se Hyuk Kim ,<sup>1</sup> Heon Yoo ,<sup>2</sup> Jong Hee Chang ,<sup>3</sup> Chae-Yong Kim ,<sup>4</sup>  
Dong Sup Chung ,<sup>5</sup> Se Hoon Kim ,<sup>6</sup> Sung-Hae Park ,<sup>7</sup> Youn Soo Lee ,<sup>8</sup>  
and Seung Ho Yang <sup>9</sup>

OPEN ACCESS

Received: Dec 27, 2017

Accepted: Apr 13, 2018

Address for Correspondence:

Seung Ho Yang, MD

Department of Neurosurgery, The Catholic University of Korea, St. Vincent's Hospital, Cell Death Disease Research Center, College of Medicine, The Catholic University of Korea, 93 Jungbu-daero, Paldal-gu, Suwon 16247, Republic of Korea.

E-mail: 72ysh@catholic.ac.kr

© 2018 The Korean Academy of Medical Sciences.

This is an Open Access article distributed under the terms of the Creative Commons Attribution Non-Commercial License (<https://creativecommons.org/licenses/by-nc/4.0/>) which permits unrestricted non-commercial use, distribution, and reproduction in any medium, provided the original work is properly cited.

ORCID iDs

Se Hyuk Kim

<https://orcid.org/0000-0002-7528-4007>

Heon Yoo

<https://orcid.org/0000-0002-9223-4300>

Jong Hee Chang

<https://orcid.org/0000-0003-1509-9800>

Chae-Yong Kim

<https://orcid.org/0000-0001-9773-5553>

Dong Sup Chung

<https://orcid.org/0000-0003-0690-4388>

Se Hoon Kim

<https://orcid.org/0000-0001-7516-7372>

Sung-Hae Park

<https://orcid.org/0000-0002-8681-1597>

Youn Soo Lee

<https://orcid.org/0000-0002-1653-6315>

<sup>1</sup>Department of Neurosurgery, Ajou University School of Medicine, Suwon, Korea

<sup>2</sup>Neuro-Oncology Clinic, National Cancer Center, Goyang, Korea

<sup>3</sup>Department of Neurosurgery, Severance Hospital, Yonsei University College of Medicine, Seoul, Korea

<sup>4</sup>Department of Neurosurgery, Seoul National University Bundang Hospital, Seongnam, Korea

<sup>5</sup>Department of Neurosurgery, The Catholic University of Korea, Incheon St. Mary's Hospital, College of Medicine, The Catholic University of Korea, Incheon, Korea

<sup>6</sup>Department of Pathology, Yonsei University College of Medicine, Seoul, Korea

<sup>7</sup>Department of Pathology, Seoul National University Hospital, Seoul, Korea

<sup>8</sup>Department of Hospital Pathology, The Catholic University of Korea, Seoul St. Mary's Hospital, College of Medicine, The Catholic University of Korea, Seoul, Korea

<sup>9</sup>Department of Neurosurgery, The Catholic University of Korea, St. Vincent's Hospital, Cell Death Disease Research Center, College of Medicine, The Catholic University of Korea, Suwon, Korea

## ABSTRACT

**Background:** While procarbazine, CCNU (lomustine), and vincristine (PCV) has been an alternative chemotherapy option for malignant gliomas, it is worth investigating whether the combination of only procarbazine and CCNU is comparable because vincristine adds toxicity with uncertain benefit. The purpose of this study was to evaluate the feasibility of procarbazine and CCNU chemotherapy for recurrent glioblastoma multiforme (GBM) with O<sup>6</sup>-methylguanine-DNA-methyltransferase (MGMT) promoter methylation.


**Methods:** Eight patients with recurrent GBM following concurrent chemoradiotherapy and temozolomide (TMZ) adjuvant therapy were enrolled in this trial; they received no other chemotherapeutic agents or target therapy. They received CCNU (75 mg/m<sup>2</sup>) on day 1 and procarbazine (60 mg/m<sup>2</sup>) through days 11 and 24 every 4 weeks. The median cycle of CCNU and procarbazine was 3.5 (range: 2–6).

**Results:** One patient achieved stable disease. The median progression-free survival (PFS) with procarbazine and CCNU chemotherapy was eight weeks (range: 5–73), and the PFS rates were 25% and 12.5% at 16 and 30 weeks, respectively. The median overall survival (OS) from the initial diagnosis to death was 40 months, and the median OS from the administration of procarbazine and CCNU chemotherapy to death was 9.7 months (95% confidence interval: 6.7–12.7). Serious adverse events were found at six visits, and two cases were considered to be grade 3 toxicities.

**Conclusion:** The efficacy of procarbazine and CCNU chemotherapy is not satisfactory. This study suggests the need to develop other treatment strategies for recurrent and TMZ-refractory GBM.

**Trial Registration:** ClinicalTrials.gov Identifier: NCT017337346

**Keywords:** Glioblastoma; Nitrosourea; Recurrent; Procarbazine; CCNU

Seung Ho Yang <https://orcid.org/0000-0002-3490-1064>**Trial Registration**ClinicalTrials.gov Identifier: [NCT017337346](#)**Funding**

This work was supported by a fund from the National Cancer Center of Korea (No. 1120320).

**Disclosure**

The authors have no potential conflicts of interest to disclose.

**Author Contributions**

Conceptualization: Yang SH, Kim SH, Chung DS. Resources: Kim SH, Yoo H, Chang JH, Kim CY, Chung DS, Yang SH. Data curation: Kim SH, Yoo H, Chang JH, Kim CY, Chung DS. Investigation: Kim SH, Park SH, Lee YS. Formal analysis: Yang SH, Kim SH. Writing - original draft: Yang SH. Writing - review & editing: Kim SH, Yoo H, Chang JH, Kim CY, Chung DS.

## INTRODUCTION

The prognosis for glioblastoma multiforme (GBM) patients remains poor despite advances in surgical techniques, radiotherapy, and chemotherapy. The median overall survival (OS) is expected to be only 14.6 months after maximum safe resection and irradiation with concurrent and adjuvant temozolomide (TMZ) chemotherapy. In spite of multimodal therapies, most patients suffer recurrence and die within 40 weeks,<sup>1,2</sup> and there is no consensus on treating recurrent and TMZ-refractory GBM. Bevacizumab, a humanized monoclonal antibody against vascular endothelial growth factor A, has shown significant biological activity in patients with recurrent GBM and has been under investigation with other target agents.<sup>3</sup> Re-challenge with alternative-dose TMZ for recurrent GBM can be recommended even if the patient has a history of standard TMZ chemotherapy.<sup>4,5</sup>

Nitrosourea has become a second choice after TMZ for malignant gliomas.<sup>6</sup> Retrospective and subgroup analyses suggest higher efficacy for procarbazine, CCNU (lomustine), and vincristine (PCV) chemotherapy than for TMZ in patients with anaplastic glioma, with good prognosis as well.<sup>7,8</sup> With the PCV triple-drug regimen, CCNU (110 mg/m<sup>2</sup>, day 1) and procarbazine (60 mg/m<sup>2</sup>, days 8–21) are administered orally but vincristine is administered intravenously (maximum 2 mg, days 8 and 29). The molecular weight of vincristine is 825 daltons, so that it has less permeability through the blood-brain barrier.<sup>9</sup> It is well-known that vincristine is associated with neurotoxicity and could impair the quality of life in brain cancer patients, and the number of outpatient visits will decrease by omitting intravenous administration of vincristine. Authors of one study reported that reducing CCNU dose by 30% reduced the hematological toxicity (grade 3/4) from 25.6% to 13%.<sup>10</sup> Based on these findings, we designed a modified procarbazine and CCNU therapy protocol for treating recurrent GBM with O<sup>6</sup>-methylguanine-DNA-methyltransferase (MGMT) promoter methylation. The purpose of this study was to evaluate the feasibility of the procarbazine and CCNU chemotherapy for recurrent GBM with MGMT promoter methylation.

## METHODS

### Study population

We enrolled patients at least 20 years of age who had been diagnosed with pathologically confirmed GBM with MGMT promoter methylation, which we assessed by methylation-specific polymerase chain reaction (PCR); we allocated patients with recurrent GBM with an unmethylated MGMT promoter to another trial. Radiographically confirmed tumor progression by magnetic resonance imaging (MRI) following standard external beam fractionated radiotherapy and TMZ chemotherapy was required for enrollment, along with a minimum Karnofsky performance status of 60, adequate hematologic, hepatic, and renal function, and at least a two-week period from any prior surgery or other chemotherapy. The following patient groups were excluded: 1) those with other cancer history, 2) those who had been treated with CCNU or procarbazine, and 3) those with leptomeningeal seeding.

### Treatment schedule

The patients had previously been treated with concurrent chemoradiotherapy (CCRT) with adjuvant TMZ following the initial diagnosis of GBM. We determined recurrence by MRI scans assessed using the Response Assessment in Neuro-Oncology criteria. CCNU (75 mg/m<sup>2</sup>) was administered on day 1 and procarbazine (60 mg/m<sup>2</sup>) was administered through days 11 and

24 every 4 weeks. Administration of CCNU and procarbazine was repeated every 28 days for up to 6 months. We evaluated all toxicities according to the Common Terminology Criteria for Adverse Events version 4.0. All patients underwent brain MRI at the baseline within two weeks of starting CCNU, and they were evaluated by laboratory examinations of blood and neurological evaluation every four weeks; they also underwent gadolinium-enhanced brain MRI after every two cycles of chemotherapy (i.e., every eight weeks). Specifically, we required stable or decreasing corticosteroid dose and stable or improved fluid-attenuated inversion recovery abnormality for a rating of complete response, partial response, or stable disease based on complete, partial, or no decrease in the enhancing tumor burden on standard post-gadolinium T1-weighted sequences.

### Study design and statistical analysis

We calculated the sample size using the following formula:

$$n = pq \left( \frac{z_{\alpha/2}}{d} \right)^2$$

where  $n$  is the required sample size,  $p$  is the known response rate, 0.15,  $q$  is 0.85 ( $1-p$ ),  $\alpha$  is 0.05, and  $d$  is the drop rate, 0.05. Approximately 52 patients needed to be enrolled for the study to achieve a difference from the historical control.

Progression-free survival (PFS) was the primary end point of this study. Secondary end points were OS using Kaplan-Meier estimation and safety of combining CCNU and procarbazine in patients with recurrent GBM.

We estimated PFS from the start of CCNU and procarbazine administration to tumor progression or dropout from the study and OS from the start of CCNU and procarbazine administration to the date of death, irrespective of its cause. We assessed PFS and OS by the Kaplan-Meier product-limit method for all patients using SPSS software version 18.0 (IBM Corp., Chicago, IL, USA).

### Ethics statement

The prospective, multicenter clinical trial was approved by the Institutional Review Board of Korean Ministry of Food and Drug Safety (No. 12096) and recorded with ClinicalTrials.gov Identifier NCT017337346.

## RESULTS

The patients were four males and four females with a median age of 56.5 years (range: 23–67), and their median Karnofsky performance scale at enrollment was 80% (range: 60–100). All patients had previously been treated with CCRT and adjuvant TMZ chemotherapy but no other chemotherapy or targeted agents. The median time between the initial GBM diagnosis and enrollment in the study was 8.75 months (range: 5.5–57).

The median cycle of CCNU and procarbazine was 3.5 (range: 2–6). Seven patients and one patient, respectively, achieved disease progression and stable disease following the administration of CCNU and procarbazine (**Table 1**).

**Table 1.** Patient characteristics

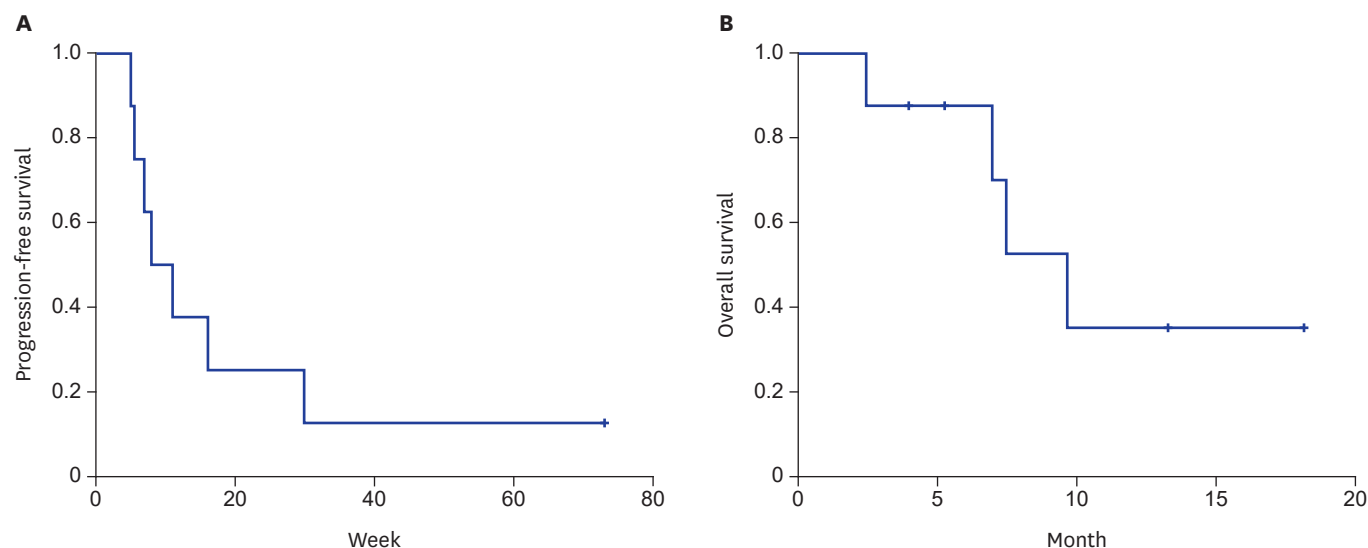
No.	Age	Sex	Initial site	Surgery	CCRT	Adjuvant TMZ, cycle	KPS at recurrence	CCNU and procarbazine, cycle	Response	F/U, mon	Status
1	67	M	Corpus callosum	Biopsy	Y	3	100	3	PD	35.3	Alive
2	52	F	Thalamus	Biopsy	Y	6	60	6	SD	36.7	Alive
3	60	M	Frontal	Craniotomy	Y	6	60	2	PD	64.0	Dead
4	23	F	Parietal	Craniotomy	Y	5	90	6	PD	18.7	Dead
5	60	F	Corpus callosum	Biopsy	Y	4	70	3	PD	13.0	Dead
6	50	F	Temporal	Craniotomy	Y	2	100	2	PD	12.3	Alive
7	31	M	Frontal	Craniotomy	Y	1	80	4	PD	9.0	Dead
8	66	M	Parietal	Craniotomy	Y	5	70	4	PD	12.5	Dead

CCRT = concurrent chemoradiotherapy, TMZ = temozolomide, KPS = Karnofsky performance scale, F/U = follow-up, PD = progression of disease, SD = stable disease.

**Table 2.** Serious adverse events

Adverse events	All	Grade			
		1	2	3	4
Increased alanine aminotransferase	1	-	-	1	-
Leukopenia	1	-	-	1	-
Disseminated intravenous coagulation	3	-	3	-	-
Generalized muscle weakness	1	-	1	-	-
Total	6	-	4	2	-

The median PFS for CCNU and procarbazine therapy to treat recurrent GBM was eight weeks (range: 5–73). PFS rates were 25% and 12.5% at 16 and 30 weeks, respectively, and the median OS from the start of CCNU and procarbazine administration to death was 9.7 months (95% confidence interval: 6.7–12.7, **Fig. 1**). The median OS from the initial diagnosis was 40 months. Serious adverse events are summarized in **Table 2**. Grade 3 toxicities including elevated hepatic enzyme and leukopenia developed in two patients, but they recovered following the delay of CCNU and procarbazine administration. In one patient, generalized muscle weakness developed and recovered without delay of the chemotherapy schedule. One patient had disseminated intravenous coagulation three times during follow-up period and was given conservative care.



**Fig. 1.** Kaplan-Meier analysis. (A) Progression-free survival. (B) Overall survival.

## DISCUSSION

In this study, the median PFS was two months in recurrent and TMZ-refractory GBM patients treated with modified CCNU and procarbazine chemotherapy; all patients had received radiotherapy with concomitant TMZ and cyclic TMZ therapy but no other cytotoxic agents or target therapies. CCNU is increasingly considered an alternative chemotherapeutic agent for GBM treatment because no other treatment has yielded better results in a controlled clinical trial, but PFS rates at six months are only in the range of 15%–25% with CCNU therapy.<sup>11,12</sup> The first randomized trial of PCV versus TMZ in chemotherapy-naïve patients with recurrent malignant glioma found that median PFS was 3.6 months with PCV and 4.7 months with TMZ ( $P = 0.229$ ). In one study,<sup>13</sup> the proportions of patients with at least one grade 3/4 adverse event were 9.2% and 12.2% in the PCV and TMZ arms ( $P = 0.40$ ), respectively, and in a single-institution analysis, grade 3/4 hematological toxicity occurred in 25.6% of patients with recurrent GBM during traditional PCV chemotherapy.<sup>10</sup>

The characteristics of our protocol were that we omitted vincristine administration and we reduced the CCNU dose to increase the treatment's tolerability. Vincristine adds toxicity and CNS penetration is suboptimal,<sup>14-16</sup> and a retrospective analysis of CCNU and procarbazine versus PCV for grades 2 and 3 oligodendrogliomas presented no differences in PFS or OS.<sup>17,18</sup> A greater proportion of patients experienced neutropenia with PCV, but only those who received vincristine experienced neurotoxicity (14% vs. 0%). The NOA-05 multicenter trial analyzed the efficacy of traditional CCNU and procarbazine chemotherapy in patients with gliomatosis cerebri, and these patients achieved median PFS of 14 months. During 124 cycles of chemotherapy, authors observed grade 3/4 hematological toxicity in 15% of patients.<sup>19</sup>

There are no clinical publications that address whether CCNU and procarbazine can be substituted for PCV for newly diagnosed or recurrent GBM. We here attempted to assess the feasibility of modified CCNU and procarbazine chemotherapy for recurrent, TMZ-refractory GBM. We searched for clinical articles using the keywords “recurrent,” “glioblastoma,” “chemotherapy,” and “Korea” in PubMed (Table 3).<sup>20-23</sup> We excluded articles about radiation therapy or radiosurgery. TMZ and the combination of ACNU and cisplatin were analyzed in three reports and one report, respectively. ACNU and cisplatin regimen had myelosuppression issues.<sup>20</sup> Two reports analyzed the efficacy of continuous low-dose TMZ administration for recurrent and TMZ-refractory GBM. They showed different outcomes in terms of PFS and OS.<sup>22,23</sup> In the phase II RESCUE study (continuous TMZ 50 mg/m<sup>2</sup>/d), six-month PFS was 23.9% in patients with recurrent GBM.<sup>24</sup> The efficacy of modified CCNU and procarbazine chemotherapy could be comparable with that of continuous low-dose TMZ therapy as a salvage therapy for recurrent GBM.

**Table 3.** Summary of clinical trials for recurrent glioblastoma treated with chemotherapeutic agents in Korea

Year	No. of patients	Type of study	No. of institution	Chemotherapy regimen	Median progression free survival	Median overall survival	Adverse effects
2005	37	Retrospective	1	ACNU, cisplatin	6 mon	9 mon	Grade 3/4 leukopenia: 41%
2006	16	Retrospective	1	Temozolomide (5 days every 28 days)	8 wk	17 wk	Grade 3/4 leukopenia: 0%
2010	38	Retrospective	1	Temozolomide (daily)	17 wk	41 wk	Grade 3 lymphopenia: 3 patients
2015	30	Retrospective	1	Temozolomide (daily)	8 wk	6 mon	Grade 3/4 leukopenia: 0%
The present study	8	Prospective	6	Procarbazine, CCNU	8 wk	9.7 mon	Grade 3 leukopenia: 1 patient

It cannot yet be determined whether the dose reduction decreased hematological toxicities because of the small number of patients and the short follow-up. Although PCV increased survival among selected patients, its toxic effects led to many dose delays and reductions during the course of treatment, whereas during a total of 30 cycles of modified CCNU and procarbazine chemotherapy, only one cycle was delayed due to leukopenia.

This is the first prospective, multicenter clinical trial for GBM approved by the Korean Food Institute Institutional Review Board. The limitation of the study is the small number of patients. Following the statistic calculation, 52 patients needed to be enrolled to achieve a difference from the historical control; however, this trial terminated before the expected end date because of the progressive deterioration of patients with recurrent GBM and slow candidate enrollment. These experiences and information should encourage clinicians and clinical researchers to suggest more challenging clinical trials in the future.

In conclusion, our findings show marginal efficacy of modified CCNU and procarbazine chemotherapy. This clinical trial suggests the need to develop treatment strategies beyond CCNU and procarbazine for recurrent, TMZ-refractory GBM.

## ACKNOWLEDGMENTS

Three neuropathologists (Drs. Kim SH, Park SH, and Lee YS) independently conducted the pathology reviews.

## REFERENCES

1. Kyritsis AP, Levin VA. An algorithm for chemotherapy treatment of recurrent glioma patients after temozolomide failure in the general oncology setting. *Cancer Chemother Pharmacol* 2011;67(5):971-83. [PUBMED](#) | [CROSSREF](#)
2. Stupp R, Mason WP, van den Bent MJ, Weller M, Fisher B, Taphoorn MJ, et al. Radiotherapy plus concomitant and adjuvant temozolomide for glioblastoma. *N Engl J Med* 2005;352(10):987-96. [PUBMED](#) | [CROSSREF](#)
3. Kreisl TN, Kim L, Moore K, Duic P, Royce C, Stroud I, et al. Phase II trial of single-agent bevacizumab followed by bevacizumab plus irinotecan at tumor progression in recurrent glioblastoma. *J Clin Oncol* 2009;27(5):740-5. [PUBMED](#) | [CROSSREF](#)
4. Franceschi E, Omuro AM, Lassman AB, Demopoulos A, Nolan C, Abrey LE. Salvage temozolomide for prior temozolomide responders. *Cancer* 2005;104(11):2473-6. [PUBMED](#) | [CROSSREF](#)
5. Wick W, Platten M, Weller M. New (alternative) temozolomide regimens for the treatment of glioma. *Neuro Oncol* 2009;11(1):69-79. [PUBMED](#) | [CROSSREF](#)
6. Weller M, van den Bent M, Tonn JC, Stupp R, Preusser M, Cohen-Jonathan-Moyal E, et al. European Association for Neuro-Oncology (EANO) guideline on the diagnosis and treatment of adult astrocytic and oligodendroglial gliomas. *Lancet Oncol* 2017;18(6):e315-29. [PUBMED](#) | [CROSSREF](#)
7. Lassman AB, Iwamoto FM, Cloughesy TF, Aldape KD, Rivera AL, Eichler AF, et al. International retrospective study of over 1000 adults with anaplastic oligodendroglial tumors. *Neuro Oncol* 2011;13(6):649-59. [PUBMED](#) | [CROSSREF](#)
8. Wick W, Roth P, Hartmann C, Hau P, Nakamura M, Stockhammer F, et al. Long-term analysis of the NOA-04 randomized phase III trial of sequential radiochemotherapy of anaplastic glioma with PCV or temozolomide. *Neuro Oncol* 2016;18(11):1529-37. [PUBMED](#)



9. Wang F, Zhou F, Kruh GD, Gallo JM. Influence of blood-brain barrier efflux pumps on the distribution of vincristine in brain and brain tumors. *Neuro Oncol* 2010;12(10):1043-9.  
[PUBMED](#) | [CROSSREF](#)
10. Yang SH, Hong YK, Yoon SC, Kim BS, Lee YS, Lee TK, et al. Radiotherapy plus concurrent and adjuvant procarbazine, lomustine, and vincristine chemotherapy for patients with malignant glioma. *Oncol Rep* 2007;17(6):1359-64.  
[PUBMED](#)
11. Batchelor TT, Mulholland P, Neyns B, Nabors LB, Campone M, Wick A, et al. Phase III randomized trial comparing the efficacy of cediranib as monotherapy, and in combination with lomustine, versus lomustine alone in patients with recurrent glioblastoma. *J Clin Oncol* 2013;31(26):3212-8.  
[PUBMED](#) | [CROSSREF](#)
12. Weller M, Cloughesy T, Perry JR, Wick W. Standards of care for treatment of recurrent glioblastoma--are we there yet? *Neuro Oncol* 2013;15(1):4-27.  
[PUBMED](#) | [CROSSREF](#)
13. Brada M, Stenning S, Gabe R, Thompson LC, Levy D, Rampling R, et al. Temozolomide versus procarbazine, lomustine, and vincristine in recurrent high-grade glioma. *J Clin Oncol* 2010;28(30):4601-8.  
[PUBMED](#) | [CROSSREF](#)
14. Boyle FM, Eller SL, Grossman SA. Penetration of intra-arterially administered vincristine in experimental brain tumor. *Neuro Oncol* 2004;6(4):300-5.  
[PUBMED](#) | [CROSSREF](#)
15. Greig NH, Soncrant TT, Shetty HU, Momma S, Smith QR, Rapoport SI. Brain uptake and anticancer activities of vincristine and vinblastine are restricted by their low cerebrovascular permeability and binding to plasma constituents in rat. *Cancer Chemother Pharmacol* 1990;26(4):263-8.  
[PUBMED](#) | [CROSSREF](#)
16. Levin VA. Relationship of octanol/water partition coefficient and molecular weight to rat brain capillary permeability. *J Med Chem* 1980;23(6):682-4.  
[PUBMED](#) | [CROSSREF](#)
17. Vesper J, Graf E, Wille C, Tilgner J, Trippel M, Nikkhah G, et al. Retrospective analysis of treatment outcome in 315 patients with oligodendroglial brain tumors. *BMC Neurol* 2009;9(1):33.  
[PUBMED](#) | [CROSSREF](#)
18. Webre C, Shonka N, Smith L, Liu D, De Groot J. PC or PCV, that is the question: primary anaplastic oligodendroglial tumors treated with procarbazine and CCNU with and without vincristine. *Anticancer Res* 2015;35(10):5467-72.  
[PUBMED](#)
19. Glas M, Bähr O, Felsberg J, Rasch K, Wiewrodt D, Schabet M, et al. NOA-05 phase 2 trial of procarbazine and lomustine therapy in gliomatosis cerebri. *Ann Neurol* 2011;70(3):445-53.  
[PUBMED](#) | [CROSSREF](#)
20. Gwak HS, Youn SM, Kwon AH, Lee SH, Kim JH, Rhee CH. ACNU-cisplatin continuous infusion chemotherapy as salvage therapy for recurrent glioblastomas: phase II study. *J Neurooncol* 2005;75(2):173-80.  
[PUBMED](#) | [CROSSREF](#)
21. Yang SH, Kim MK, Lee TK, Lee KS, Jeun SS, Park CK, et al. Temozolomide chemotherapy in patients with recurrent malignant gliomas. *J Korean Med Sci* 2006;21(4):739-44.  
[PUBMED](#) | [CROSSREF](#)
22. Kong DS, Lee JI, Kim JH, Kim ST, Kim WS, Suh YL, et al. Phase II trial of low-dose continuous (metronomic) treatment of temozolomide for recurrent glioblastoma. *Neuro Oncol* 2010;12(3):289-96.  
[PUBMED](#) | [CROSSREF](#)
23. Woo JY, Yang SH, Lee YS, Lee SY, Kim J, Hong YK. Continuous low-dose temozolomide chemotherapy and microvessel density in recurrent glioblastoma. *J Korean Neurosurg Soc* 2015;58(5):426-31.  
[PUBMED](#) | [CROSSREF](#)
24. Perry JR, Bélanger K, Mason WP, Fulton D, Kavan P, Easaw J, et al. Phase II trial of continuous dose-intense temozolomide in recurrent malignant glioma: RESCUE study. *J Clin Oncol* 2010;28(12):2051-7.  
[PUBMED](#) | [CROSSREF](#)