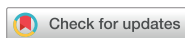

Original Article
Musculoskeletal Disorders



Low Positive Predictive Value of Bone Scan to Predict Impending Complete Fracture among Incomplete Atypical Femoral Fracture

Young-Kyun Lee ,^{1*} You Jin Lee ,^{2*} Na Kyoung Lee ,¹ Jae-Hwi Nho ,³ and Kyung-Hoi Koo ¹

¹Department of Orthopaedic Surgery, Seoul National University Bundang Hospital, Seongnam, Korea

²Department of Internal Medicine, Center for Thyroid Cancer, National Cancer Center, Goyang, Korea

³Department of Orthopaedic Surgery, Soonchunhyang University Hospital, Seoul, Korea



Received: Dec 21, 2017

Accepted: Feb 20, 2018

Address for Correspondence:

Jae-Hwi Nho, MD

Department of Orthopaedic Surgery,
Soonchunhyang University Hospital Seoul,
59 Daesagwan-ro, Yongsan-gu, Seoul 04401,
Korea.

E-mail: huuy@schmc.ac.kr

*Young-Kyun Lee and You Jin Lee equally contributed to this work, and should be considered co-first authors.

© 2018 The Korean Academy of Medical Sciences.

This is an Open Access article distributed under the terms of the Creative Commons Attribution Non-Commercial License (<https://creativecommons.org/licenses/by-nc/4.0/>) which permits unrestricted non-commercial use, distribution, and reproduction in any medium, provided the original work is properly cited.

ORCID iDs

Young-Kyun Lee
<https://orcid.org/0000-0001-6564-4294>

You Jin Lee
<https://orcid.org/0000-0002-1224-0875>

Na Kyoung Lee
<https://orcid.org/0000-0001-7545-9797>

Jae-Hwi Nho
<https://orcid.org/0000-0003-1053-456X>

Kyung-Hoi Koo
<https://orcid.org/0000-0001-5251-2911>

ABSTRACT

Background: Although bone scan might be useful to detect incomplete atypical femoral fractures (AFFs) earlier than radiographs, there is no study on predicting further progression to a complete fracture among incomplete AFFs. Our purposes are to determine whether bone scan detects impending complete fracture among incomplete AFFs.

Methods: We reviewed 18 patients (20 AFFs) who underwent bone scan at the diagnosis of incomplete AFF and were not treated with prophylactic fixation. A diagnosis of impending complete fracture was made, when the femur completely fractured within 6 months after the scan. We correlated radioisotope uptake with the impending complete fracture to calculate sensitivity, specificity, positive predictive value and negative predictive value of bone scan.

Results: Thirteen AFFs (65%, 13/20) showed a positive uptake in bone scan. Among the 13, only one femur was completely fractured within 6 months. None of the 7 femurs without uptake in bone scan fractured. In diagnosing impending complete fracture, the sensitivity of bone scan was 100% and negative predictive value was 100%. However, the specificity (36.8%) and positive predictive value (7.7%) were quite low.

Conclusion: Bone scan has no significant role in detecting the impending complete fracture, and a positive uptake does not mean the necessity of prophylactic fixation of incomplete AFF.

Keywords: Atypical Femoral Fracture; Bone Scan, Prophylactic Fixation; Impending Fracture; Femur

INTRODUCTION

In accordance with the popular use of bisphosphonates to prevent osteoporotic fractures,¹⁻⁴ atypical femoral fracture (AFF) appeared as a challenging problem.^{2,5,6}

AFF is frequently associated with pain and it is diagnosed in the state of incomplete fracture.^{7,8} An incomplete AFF frequently progresses into a complete fracture.^{7,8} Once a complete fracture occurs, the surgery becomes challenging due to high rates of delayed union and non-union.^{5,9,10} Therefore, there is consensus that prophylactic fixation should be done when a complete fracture is impending.^{5,10,11}

Disclosure

The authors have no potential conflicts of interest to disclose.

Author Contributions

Conceptualization: Lee YK, Lee YJ. Data curation: Lee NK. Formal analysis: Lee YK, Lee YJ. Investigation: Lee YK, Lee YJ. Methodology: Lee YK, Lee YJ. Software: Lee NK. Validation: Nho JH. Writing - original draft: Lee YK, Lee YJ. Writing - review & editing: Koo KH.

If the occurrence of complete fracture could be predicted, it would be helpful to decide whether to do a prophylactic fixation.

AFF is a fatigue fracture of the femur caused by repeated stresses over time.¹² It might be difficult to detect early-stage AFF in plain radiographs, because it can be detected several weeks after the onset when the bone begins to remodel.¹³ Tc-99m hydroxymethylene diphosphonate (^{99m}Tc-HDP) bone scan, which reflects the activity of osteoblast, might detect incomplete AFF earlier than radiographs and might predict further progression to a complete fracture. However, there was no study to determine whether bone scan identifies impending complete fracture among incomplete AFFs.

Therefore, the purpose of this study was to evaluate the role of bone scan in detecting impending complete AFFs, which necessitate a prophylactic fixation.

METHODS

We retrospectively reviewed the medical records and radiographs of 57 patients (72 femurs) who were diagnosed as having an incomplete AFF at our hospital from January 2004 to December 2016. The inclusion criteria were: 1) bone scan at the time of diagnosis of an incomplete AFF; 2) no prophylactic fixation within 6 months after the bone scan; and 3) medical records and radiographs available until the time of developing a complete fracture or at least 6 months after the time of bone scan without developing a complete fracture.

A diagnosis of incomplete AFF was made according to the radiographic criteria defined by the Task Force of the American Society for Bone and Mineral Research¹²; 1) location from anywhere distal to the lesser trochanter and proximal to the supracondylar flare of the distal femoral metaphysis, 2) focal or diffuse thickening of the lateral cortex, and 3) an occasional discrete transverse lateral cortex translucency with periosteal callus formation.

Of the 57 patients, 27 patients (35 incomplete AFFs) were studied with bone scan for the diagnostic workup. Among the 8 patients who had bilateral AFFs, 1 patient underwent bilateral prophylactic fixations, and 5 patients underwent unilateral prophylactic fixation within 6 months after the time of bone scan. Among 19 patients who had unilateral AFF, 8 patients underwent prophylactic fixation within the 6 months. The remaining 20 incomplete AFFs in 18 patients were subjects of this study (Fig. 1).

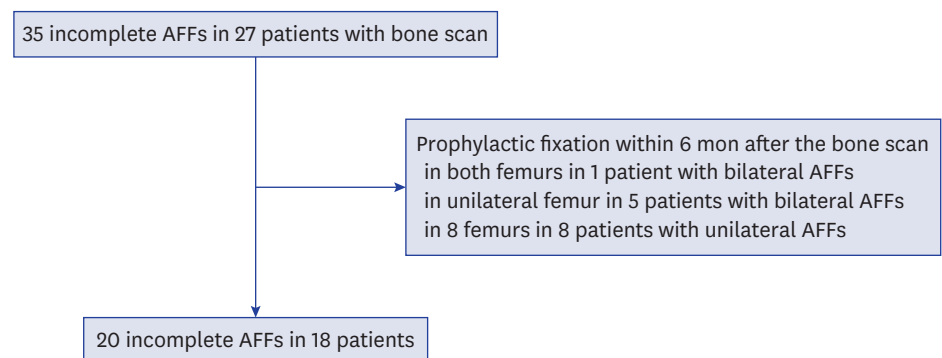


Fig. 1. Flowchart to identify subjects who met the inclusion criteria.
AFF = atypical femoral fracture.

All patients were women with a mean age of 73.4 years (range, 64–83 years) and a mean body mass index (BMI) of 23.8 kg/m² (range, 17.6 to 31.6 kg/m²). In 14 patients, the mean duration of bisphosphonate treatment was 6.6 years (range, 3 to 10 years). Alendronate was used in 11 patients, and ibandronate in 3. Bisphosphonate use was stopped after diagnosis of AFF.

We defined impending fracture as a fracture that progressed to a complete fracture within 6 months after the time of bone scan.^{14,15} The outcome for this study was defined as complete fracture or noncomplete fracture within the 6 months after the bone scan.

^{99m}Tc-HDP bone scan

Bone scanning was performed using ^{99m}Tc-HDP. Four hours prior to bone scanning, patients were injected with 30mCi ^{99m}Tc-HDP intravenously. After injection, anterior and posterior scintigrams of the pelvis, including both hips, were obtained using a gamma camera (NM/CT670; GE Healthcare, Pittsburgh, PA, USA).

Evaluation of bone scans

Visual evaluations of radioisotope uptake in femur were performed independently by two orthopaedic surgeons, who were unaware of patient clinical information and radiological findings. Uptake in the femur on the involved lesion was classified as positive (increased uptake) and negative (normal or reduced uptake) (Fig. 2). When the two observers disagreed on the evaluation of the uptake, the final decision was made by a third observer.

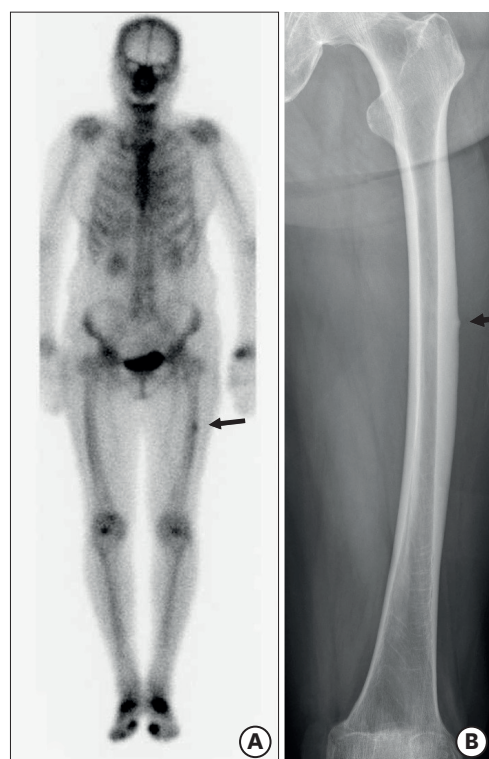

Fig. 2. An 81-year-old woman had left thigh pain for 2 months. (A) Bone scan showed hot uptake (positive finding) at the middle of femoral shaft, and (B) anteroposterior radiograph of femur revealed atypical femoral incomplete fracture. She did not have any pain or complete fracture at 11 months later.

Statistical analysis

To test interobserver agreement on the bone scan, the kappa value was calculated. To determine whether the bone scan could identify impending complete fracture, we calculated sensitivity, specificity, positive predictive value, and negative predictive value of bone scan. We also calculated 95% confidence interval for each value.

Statistical analysis was performed with SPSS software (version 16; Chicago, IL, USA). *P* values, 0.05 were considered statistically significant.

Ethics statement

This study was reviewed and approved by the Institutional Review Board of Seoul National University Bundang Hospital (approval number: B-1705/395-113). Informed consent was submitted by all subjects when they were enrolled.

RESULTS

The kappa value was 0.780, which means a satisfactory agreement in the evaluation of uptake in bone scan. Among 20 femurs, 13 femurs had an increased uptake in bone scan, while the remaining 7 femurs had no increased uptake (**Table 1**).

Among the 13 incomplete AFFs with the positive uptake, only 1 (7.7%, 1/13) completely fractured within 6 months (at 18 days) after the bone scan, while 4 femurs fractured from 14 to 45 months (mean, 28.8 months). Among the 7 incomplete AFFs with the negative uptake, only 1 femur completely fractured at 71 months after the bone scan.

In the remaining 14 AFFs (70%), complete fracture did not occur until a mean follow-up of 50.7 months (12 to 100 months). Thus, only one incomplete AFF was categorized as impending fracture. This incomplete AFF had increased uptake in bone scan.

In terms of bone scan as a predictor of impending complete fracture of incomplete AFFs, the sensitivity was 100% (95% CI, 2.5%–100%), specificity was 36.8% (95% CI, 16.3%–61.6%), positive predictive value was 7.7% (95% CI, 5.6%–10.5%), and negative predictive value was 100%.

DISCUSSION

Incomplete AFF usually requires prophylactic fixation when a patient has prodromal severe pain.⁸ To determine and predict impending fracture is very important because a reasonable prediction can not only facilitate avoidance of complete fracture, but also avoidance of unnecessary surgery. Although positive finding of bone scan can help to diagnose AFF, it does not mean the necessity of prophylactic fixation.

Table 1. Qualitative evaluation of bone scan in the femur with incomplete AFF

| Bone scanning | Impending fracture | Non-fracture within 6 months | <i>P</i> value |
|---------------|--------------------|------------------------------|----------------|
| Positive | 1 | 12 | 1.000 |
| Negative | 0 | 7 | |

AFF = atypical femoral fracture.

In our study, the sensitivity of bone scan was 100% and negative predictive value was 100% in the detection of impending complete fracture among incomplete AFFs. However, the specificity (36.8%) and positive predictive value (7.7%) were quite low. Our results showed that a positive uptake in bone scan does not mean an impending complete fracture, requiring a prophylactic fixation.

Many studies have reported that ^{99m}Tc -HDP bone scans are useful for the detection of stress fracture,¹⁶⁻¹⁹ and several studies used bone scans to diagnose AFF.²⁰⁻²³ AFFs have a characteristic appearance and can be detected on bone scan.²² Some focal thickenings of the femoral cortex, which are seen on plain radiographs, might be inactive scars after a stress reaction. These inactive lesions usually have negative findings on bone scan.¹³ Positive uptake in bone scan means that of radiopharmaceuticals bind to the hydroxyapatite crystals in proportion to increased local blood flow and osteoblastic activity. Therefore, positive finding of bone scan does not mean possibility of complete AFF, but it means just increased bone turnover and increased bone perfusion. Our study showed that positive uptake on bone scan did not mean an impending complete fracture, although it could be useful to diagnose AFF.

We note the limitation of our study. First, this is a retrospective study and the number of subjects was too small. However, considering incomplete AFF is a rare disease and the incidence of progression to a complete fracture is quite low, the number of our subjects was enough to calculate the sensitivity and negative predictive value. Second, we could not evaluate whether the probability of complete fracture would differ according to the degree of hot uptake (uni-cortical versus bi-cortical uptake), because of too small number of patients.

Nevertheless, our results showed that the majority of incomplete AFF with positive uptake in bone scan did not develop a complete fracture until 6 months after the bone scan. Although it is useful in the detection of incomplete AFF, bone scan showed low positive predictive value and has a limited role in identifying impending complete fracture among incomplete AFFs, while it has the perfect sensitivity (100%) and negative predictive value (100%).

REFERENCES

1. Lee YK, Jang S, Ha YC. Management of osteoporosis in South Korea. *Crit Rev Eukaryot Gene Expr* 2015;25(1):33-40.
[PUBMED](#) | [CROSSREF](#)
2. Ha YC, Lee YK, Lim YT, Jang SM, Shin CS. Physicians' attitudes to contemporary issues on osteoporosis management in Korea. *J Bone Metab* 2014;21(2):143-9.
[PUBMED](#) | [CROSSREF](#)
3. Thompson RN, Phillips JR, McCauley SH, Elliott JR, Moran CG. Atypical femoral fractures and bisphosphonate treatment: Experience in two large United Kingdom teaching hospitals. *J Bone Joint Surg Br* 2012;94(3):385-90.
[PUBMED](#) | [CROSSREF](#)
4. Yoon RS, Hwang JS, Beebe KS. Long-term bisphosphonate usage and subtrochanteric insufficiency fractures: A cause for concern? *J Bone Joint Surg Br* 2011;93(10):1289-95.
[PUBMED](#) | [CROSSREF](#)
5. Teo BJ, Koh JS, Goh SK, Png MA, Chua DT, Howe TS. Post-operative outcomes of atypical femoral subtrochanteric fracture in patients on bisphosphonate therapy. *Bone Joint J* 2014;96-B(5):658-64.
[PUBMED](#) | [CROSSREF](#)
6. Meling T, Nawab A, Harboe K, Fosse L. Atypical femoral fractures in elderly women: a fracture registry-based cohort study. *Bone Joint J* 2014;96-B(8):1035-40.
[PUBMED](#) | [CROSSREF](#)

7. Lee YK, Ha YC, Kang BJ, Chang JS, Koo KH. Predicting need for fixation of atypical femoral fracture. *J Clin Endocrinol Metab* 2013;98(7):2742-5.
[PUBMED](#) | [CROSSREF](#)
8. Ha YC, Cho MR, Park KH, Kim SY, Koo KH. Is surgery necessary for femoral insufficiency fractures after long-term bisphosphonate therapy? *Clin Orthop Relat Res* 2010;468(12):3393-8.
[PUBMED](#) | [CROSSREF](#)
9. Egol KA, Park JH, Rosenberg ZS, Peck V, Tejwani NC. Healing delayed but generally reliable after bisphosphonate-associated complete femur fractures treated with IM nails. *Clin Orthop Relat Res* 2014;472(9):2728-34.
[PUBMED](#) | [CROSSREF](#)
10. Prasarn ML, Ahn J, Helfet DL, Lane JM, Lorich DG. Bisphosphonate-associated femur fractures have high complication rates with operative fixation. *Clin Orthop Relat Res* 2012;470(8):2295-301.
[PUBMED](#) | [CROSSREF](#)
11. Weil YA, Rivkin G, Safran O, Liebergall M, Foldes AJ. The outcome of surgically treated femur fractures associated with long-term bisphosphonate use. *J Trauma* 2011;71(1):186-90.
[PUBMED](#) | [CROSSREF](#)
12. Shane E, Burr D, Abrahamsen B, Adler RA, Brown TD, Cheung AM, et al. Atypical subtrochanteric and diaphyseal femoral fractures: second report of a task force of the american society for bone and mineral research. *J Bone Miner Res* 2014;29(1):1-23.
[PUBMED](#) | [CROSSREF](#)
13. Khan AA, Leslie WD, Lentle B, Iles S, Kaiser SM, Frame H, et al. Atypical femoral fractures: a teaching perspective. *Can Assoc Radiol J* 2015;66(2):102-7.
[PUBMED](#) | [CROSSREF](#)
14. Mirels H. Metastatic disease in long bones: A proposed scoring system for diagnosing impending pathologic fractures. 1989. *Clin Orthop Relat Res* 2003; (415 Suppl):S4-13.
[PUBMED](#) | [CROSSREF](#)
15. Min BW, Koo KH, Park YS, Oh CW, Lim SJ, Kim JW, et al. Scoring system for identifying impending complete fractures in incomplete atypical femoral fractures. *J Clin Endocrinol Metab* 2017;102(2):545-50.
[PUBMED](#)
16. Boam WD, Miser WF, Yuill SC, Delaplain CB, Gayle EL, MacDonald DC. Comparison of ultrasound examination with bone scintiscan in the diagnosis of stress fractures. *J Am Board Fam Pract* 1996;9(6):414-7.
[PUBMED](#)
17. Giladi M, Nili E, Ziv Y, Danon YL, Aharonson Z. Comparison between radiography, bone scan, and ultrasound in the diagnosis of stress fractures. *Mil Med* 1984;149(8):459-61.
[PUBMED](#) | [CROSSREF](#)
18. Jones DN, Wycherley AG. Bone scan demonstration of progression of sacral insufficiency stress fracture. *Australas Radiol* 1994;38(2):148-50.
[PUBMED](#) | [CROSSREF](#)
19. Minoves M, Ponce A, Balias R, Til L. Stress fracture of the first metatarsal in a fencer: typical appearance on bone scan and pinhole imaging. *Clin Nucl Med* 2011;36(10):e150-2.
[PUBMED](#) | [CROSSREF](#)
20. Alfahad A, Thet EM, Radwan F, Sudhakar J, Nini K, Tachtatzis P. Spontaneous incomplete transverse subtrochanteric femoral fracture with cortical thickening possibly secondary to risedronate use: a case report. *J Med Case Rep* 2012;6(1):272.
[PUBMED](#) | [CROSSREF](#)
21. Kang SY, Baek JH, Kang BJ, Kim MK, Lee HJ. Is it a simple stress fracture or bisphosphonate-related atypical fracture? *J Bone Metab* 2012;19(2):129-32.
[PUBMED](#) | [CROSSREF](#)
22. Probst S, Rakheja R, Stern J. Atypical bisphosphonate-associated subtrochanteric and femoral shaft stress fractures: diagnostic features on bone scan. *Clin Nucl Med* 2013;38(5):397-9.
[PUBMED](#) | [CROSSREF](#)
23. Kanatlı U, Ataoglu MB, Ozer M, Topcu HN, Cetinkaya M. Surgical treatment of bilateral femoral stress fractures related with long-term alendronate therapy. *Ekleml Hastalik Cerrahisi* 2017;28(1):55-8.
[PUBMED](#) | [CROSSREF](#)