

Pseudo-no-Reflow Phenomenon in Carotid Artery Stenting using FilterWire EX: Successful Recovery by Aspiration Thrombectomy

Distal protection devices such as FilterWire EX have been widely used in carotid artery stenting, however, the large amount of atherothrombotic debris entrapped in the filter could reduce or stop antegrade flow. We present a case of pseudo-no-reflow phenomenon after postdilatation of the stent in a patient with asymptomatic carotid artery stenosis. After several passes using an Export Aspiration catheter, normal flow in the internal carotid artery was restored. Aspiration thrombectomy can successfully recover pseudo-no-reflow phenomenon.

Key Words : Carotid Artery Stenting; Distal Protection Device; Pseudo-no Reflow Phenomenon; Aspiration Thrombectomy

Seung Hwan Han, Woong Chol Kang,
Tae Hoon Ahn, and Eak Kyun Shin

Division of Cardiology, Heart Center, Gil Hospital
Gachon University of Medicine and Science
Incheon, Korea

Received : 24 January 2008

Accepted : 6 May 2008

Address for correspondence

Eak Kyun Shin, M.D.
Division of Cardiology, Gil Heart Center, Gachon
Medical School, 1198 Guwol-dong, Namdong-gu,
Incheon 405-760, Korea
Tel : +82.32-460-3665, Fax : +82.32-460-3117
E-mail : ekshin@gilhospital.com

INTRODUCTION

The interventions for carotid artery stenosis, vein graft and acute myocardial infarction could embolize a large amount of plaque debris, especially unstable, ulcerative, and thrombus containing lesions (1). Distal protection devices such as FilterWire EX have been widely used in carotid artery stenting to prevent distal embolization of plaque debris (2). The large amount of atherothrombotic debris entrapped in the filter could reduce or stop antegrade flow and may be shown as no reflow phenomenon in case using filter type distal protection device.

We present a case of pseudo no-reflow phenomenon after postdilatation of the stent in severe carotid artery stenosis and successful recovery with aspiration thrombectomy using Export Aspiration catheter.

CASE REPORT

A 70-yr-old man was diagnosed with asymptomatic carotid artery stenosis during preoperative risk assessments. He was planned to surgery for rectosigmoid cancer. He was a current smoker and denied history of hypertension and diabetes mellitus. He had been treated in our hospital for congestive heart failure and stable angina for 2 yr. He did not complain of dyspnea or chest pain and had no neurological abnormality.

Carotid angiogram showed no significant stenosis in the left carotid artery and a 90% stenosis in the right internal carotid

artery (Fig. 1). Shuttle sheath (7F, Cook Medical, Bloomington, IN, U.S.A.) was positioned to right common carotid artery via right femoral artery. To prevent distal embolization of plaque debris during angioplasty, FilterWire EX (Boston Scientific, Natick, MA, U.S.A.) was positioned in the right cervical internal carotid artery distal to stenotic lesion. After predilation with 4.0 mm balloon, 8 mm self-expanding Wall stent (Boston Scientific) was positioned across the lesion and was deployed in stenotic lesion. After postdilation of the stent with 6.0 mm balloon, carotid angiogram showed abrupt complete flow interruption (Fig. 2A). We suspected this phenomenon induced by obliteration of filter pore by massive atherosclerotic emboli. We decided to perform aspiration thrombectomy using Export Aspiration catheter (Medtronic AVE, Santa Rosa, CA, U.S.A.) (Fig. 2B). After several passes of Export Aspiration catheter into the basket (over the FilterWire EX), antegrade flow was fully restored (Fig. 3). After retrieval of FilterWire Ex, whitish debris was noted within the basket (Fig. 4). After finishing carotid artery stenting, the patient complained of slight speech disturbance and this neurological abnormality was completely recovered within 24 hr after stenting.

DISCUSSION

Obstructive carotid artery lesions are known to contain friable, ulcerated and thrombotic material that have the potential to embolize during intervention and may be responsible

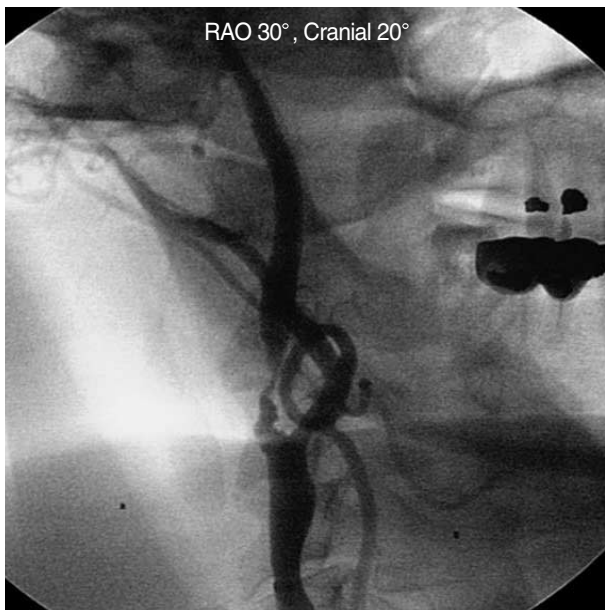

Fig. 1. Carotid angiogram showed severe stenotic lesion in the right internal carotid artery.
RAO, right anterior oblique.

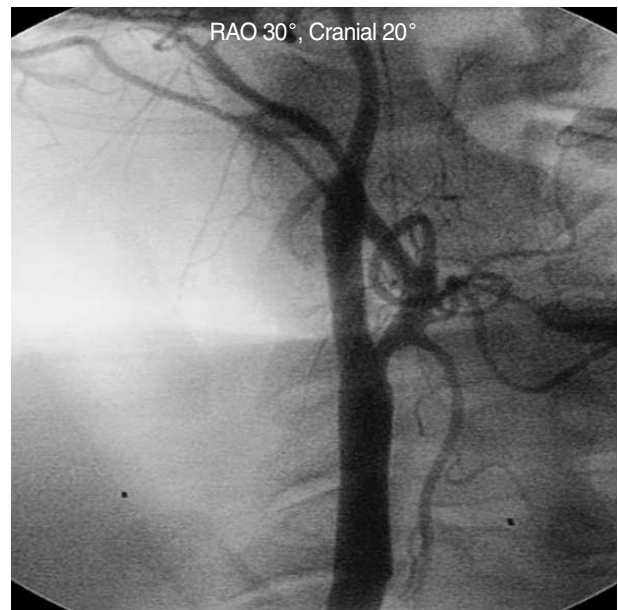

Fig. 3. After aspiration thrombectomy, antegrade flow was fully restored.
RAO, right anterior oblique.

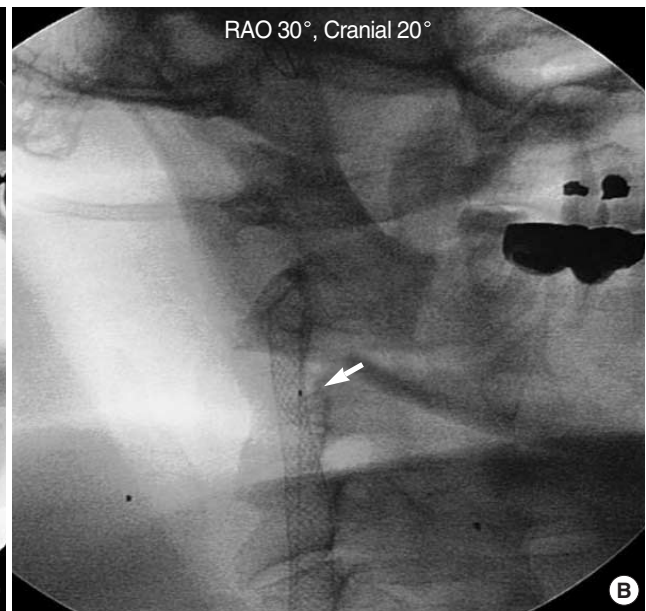
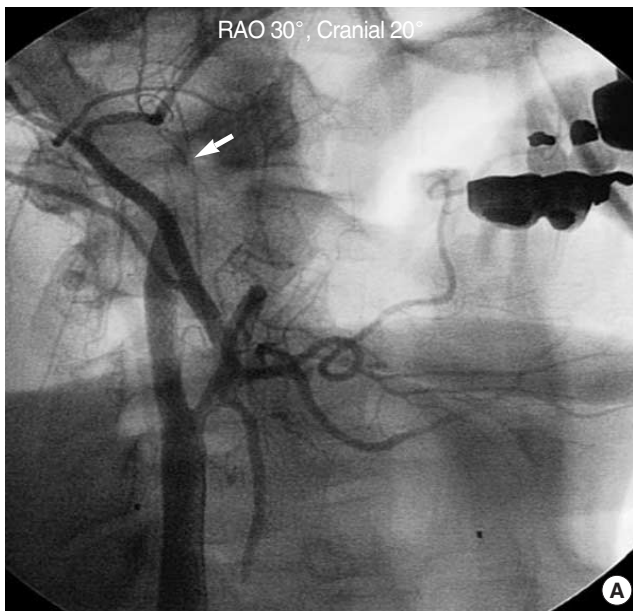


Fig. 2. (A) After postdilatation of the stent, sudden antegrade flow interruption (arrow) developed proximal to FilterWire EX location. (B) Several passes of Export Aspiration catheter (arrow) was performed before FilterWire removal.
RAO, right anterior oblique.

for the majority of the neurologic events during carotid artery stenting (1). A number of “distal protection” strategies, designed to capture embolic debris released during carotid intervention, have been evaluated for their efficacy in minimizing the risk of embolic neurologic events. The intravascular filter type distal protection device offers the advantage of a constant cerebral perfusion during carotid artery stenting and

allows more time for careful and precise intervention (2). During carotid artery stenting using filter type distal protection device, microscopic particles larger than the size of the filter pores (80 to 130 μm) could be captured. Reimers *et al.* (3) reported that carotid artery stenting with filter type distal protection device experienced flow impairment due to filter obstruction in 7.9% of procedures, which was resolved in all

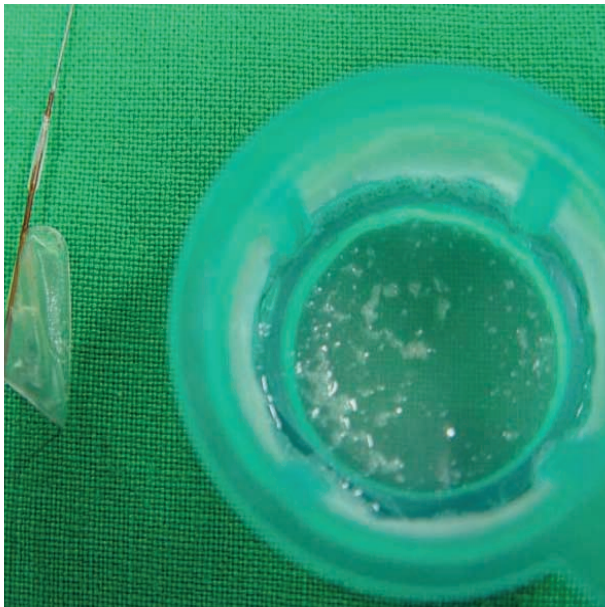

Fig. 4. After retrieval of FilterWire EX, whitish debris was noted within the basket.

cases after filter removal. In our case, complete flow interruption was developed after postdilatation of the stent. We suspected this pseudo-no-reflow phenomenon was induced by obliteration of filter pore by massive atherosclerotic debris. We considered to remove filter by retrieval catheter, however, this process may cause entrapment of filter device to retrieval catheter and embolize massive amount of atherosclerotic debris. Therefore, we choose aspiration thrombectomy using Export Aspiration catheter. After aspiration thrombectomy, flow interruption in the right internal carotid artery was completely restored, therefore, we confirmed this phenomenon as pseudo-no-reflow phenomenon instead of true no-reflow phenomenon. Yadav (4) recommended practically in his review paper if there is no forward blood flow during carotid

angioplasty with filter type distal protection device, this should be aspirated before the filter is collapsed. Our case is the first case report of pseudo-no-reflow phenomenon in carotid artery stenting using filter type distal protection device and successful recovery of this phenomenon by aspiration thrombectomy using Export Aspiration catheter. Lee et al. (5) recently reported that successful management of pseudo-no-reflow phenomenon by the Export Aspiration catheter in ostial saphenous vein graft intervention using FilterWire EX protection.

In conclusion, the large amount of atherothrombotic debris entrapped in the filter during carotid intervention could stop antegrade flow. This phenomenon is pseudo-no-reflow phenomenon instead of true no-reflow phenomenon. Aspiration thrombectomy can successfully recover pseudo-no-reflow phenomenon.

REFERENCES

1. Imparato AM, Riles TS, Gorstein F. *The carotid bifurcation plaque: pathologic findings associated with cerebral ischemia. Stroke* 1979; 10: 238-45.
2. Al-Mubarak N, Colombo A, Gaines PA, Iyer SS, Corvaja N, Cleveland TJ, Macdonald S, Brennan C, Vitek JJ. *Multicenter evaluation of carotid artery stenting with a filter protection system. J Am Coll Cardiol* 2002; 39: 841-6.
3. Reimers B, Schlüter M, Castriota F, Tübler T, Corvaja N, Cemetti C, Manetti R, Picciolo A, Liistro F, Di Mario C, Cremonesi A, Schofer J, Colombo A. *Routine use of cerebral protection during carotid artery stenting: results of a multicenter registry of 753 patients. Am J Med* 2004; 116: 217-22.
4. Yadav JS. *Embolic protection devices: methods, techniques, and data. Tech Vasc Interv Radiol* 2004; 7: 190-3.
5. Lee CH, Low A, Tan HC, Lim YT. *Pseudo-no-reflow phenomenon in ostial saphenous vein graft intervention using FilterWire EX protection. Int J Cardiol* 2005; 104: 233-4.