

## Synchronous Bony and Soft Tissue Metastases from Follicular Carcinoma of the Thyroid

Follicular carcinoma of the thyroid rarely manifests itself as a distant metastatic lesion, and, when present, is usually found in flat bones. A soft tissue metastasis is extremely rare, and synchronous metastases to the bone and soft tissue is not reported in the literature so far. We report such a case of a 42-yr-old male, who presented with a goiter, scalp and forearm soft tissue swellings, and, fine needle aspiration cytology of all these swellings revealed a follicular neoplasm. A wide excision of the forearm swelling was carried out and the histopathology was consistent with features of metastatic follicular carcinoma of the thyroid. The main stay of treatment is surgical resection of the primary tumor. The various modalities of treatment of metastasis is discussed with a review of literature.

**Key Words :** *Thyroid Gland; Adenocarcinoma, Follicular; Neoplasm Metastasis*

**Gabriel Rodrigues, Arnab Ghosh\***

Departments of General Surgery & Pathology\*,  
Kasturba Medical College and Hospital, Manipal,  
Karnataka, INDIA

Received : 23 September 2002

Accepted : 14 February 2003

### Address for correspondence

Gabriel Rodrigues, MS, DNB  
Assistant Professor of Surgery, 157, KMC Quarters  
Madhavanagar Manipal-576 119, Karnataka, INDIA  
Tel : +91.820-2572647, Fax : +91.820-2570061  
E-mail : gabrodrigues@excite.com

### INTRODUCTION

Follicular thyroid carcinoma (FTC) is a slow-growing tumor, and is the second most common cancer of the thyroid. Distant spread may occur commonly to bones, brain and lungs. Soft tissue metastasis is extremely rare and the reported incidence of distant metastasis is between 11 and 25%, while the initial presentation with distant metastasis is uncommon (1). So far to our knowledge, there is no report of a synchronous bone and soft tissue metastases in the literature. We conducted this study based on the extremely rare case of soft tissue metastasis.

### CASE REPORT

A 42-yr-old male presented with a non-toxic solitary thyroid nodule (STN) of 5 yr of duration with swellings on the scalp and on the right forearm with the durations of 3 and 2 months respectively. There was no other significant contributory history.

On examination, the general condition and vital signs were normal. A left STN measuring 5 × 3 cm was present, and was hard in consistency. There was no cervical lymphadenopathy. The left parietal region swelling was firm, non-tender, well-defined and measured 7 × 5 cm. A bony defect was palpable. The right forearm subcutaneous swelling was hard, non-tender, mobile and well-defined (Fig. 1).

Investigations revealed a normal hemogram and chest radiography. Radiography of the skull revealed the erosion of the outer table of the left parietal bone (Fig. 2). Fine needle aspi-

ration cytology (FNAC) from the thyroid nodule, swellings on the scalp and the forearm revealed atypical follicular cells, suggesting a follicular neoplasm. A complete excision with adequate free margins (2 cm) of the swelling on the forearm was carried out under local anesthesia, and the histopathology revealed fibrous septae separating colloid-filled follicles lined by cuboidal follicular cells with areas of Hurthle cell change, anisonucleosis and scalloping of colloid with pseudopapillary hyperplasia (Fig. 3). Serum thyroglobulin (TG) level was found to be 580 ng/mL (normal ≤ 60 ng/mL). Hence, a diagnosis of FTC with synchronous metastases to bone and soft tissue was made.

The patient was operated upon in two phases. First a total thyroidectomy was executed. There were no palpable enlarged lymph nodes, intraoperatively, in the neck. A week later, the scalp swelling was excised widely with adequate margins (2 cm). Final histopathology report showed follicular carcinoma in both specimens (features as described above, with presence of both capsular and vascular invasion). Post-operative period was uneventful. At the end of the 3rd week, serum thyroglobulin levels had reverted back to normal. A <sup>131</sup>I whole body scan at the end of the 5th week showed no residual thyroid tissue in the thyroid bed (neck), except for a hot spot in the scalp which was ablated with <sup>131</sup>I (30 mCi). Patient has been put on thyroxine 0.3 mg/day for life and kept under close follow-up. The patient has been free of symptoms for the next 3 yr.

### DISCUSSION

FTC is the second most common differentiated thyroid ma-

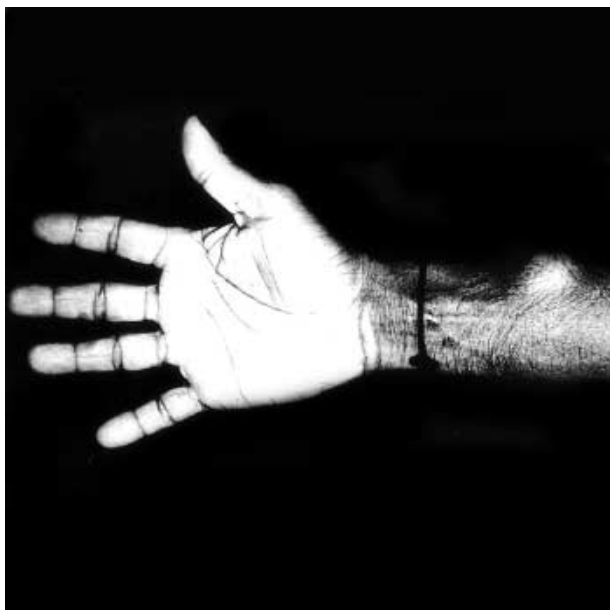


Fig. 1. Photograph showing right forearm swelling.

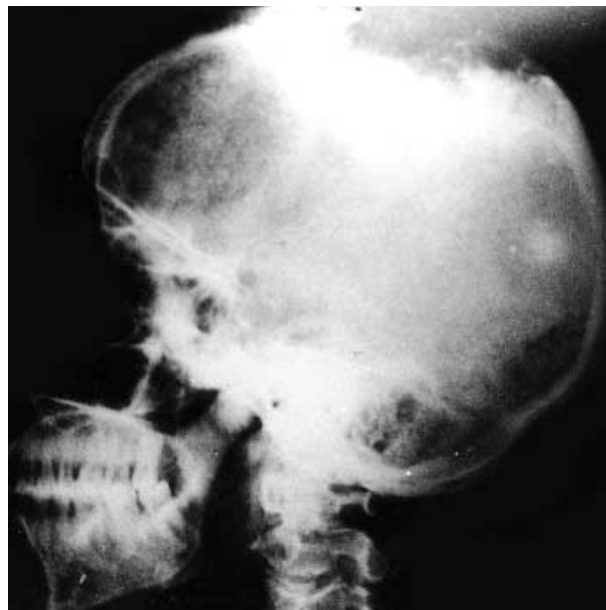


Fig. 2. Lateral radiography of the skull showing bony erosion.

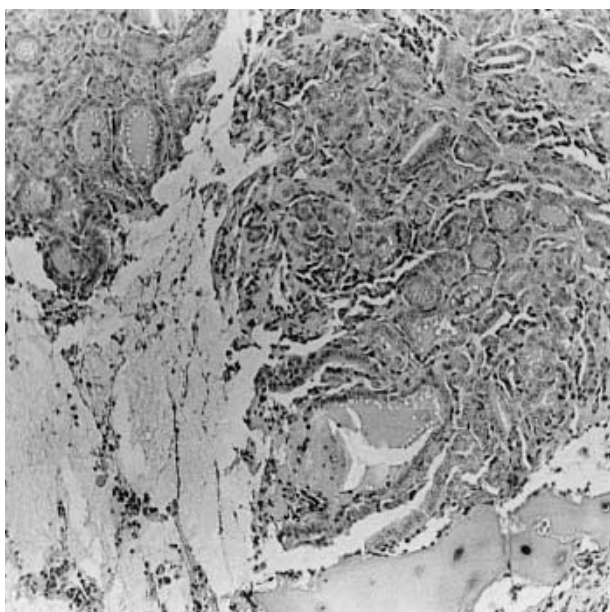


Fig. 3. Photomicrograph showing colloid filled follicles, Hurthle cell change, anisonucleosis and scalloping of colloid with pseudo-papillary hyperplasia (H&E,  $\times 40$ ).

lignancy. It is usually seen in elderly females, unlike our patient, primarily having a long-standing non-toxic multinodular goiter (50.2%) (2). Nearly 80% of patients with FTC are seen to have a STN, and it can also be rarely seen in patients with endemic goiter (3). Neoplastic change in an existing goiter is most probably brought about by chronically elevated TSH levels. In India, for example, the incidence of FTC is 43.9% of all the differentiated thyroid malignancies (2). The incidence of presentation with distant metastasis increases among

patients over 45 yr of age, and the age at presentation is the single most important prognostic factor in differentiated thyroid cancers (4, 5).

A follicular neoplasm should be regarded as potentially malignant and surgically excised, as it is impossible to cytologically differentiate between a follicular adenoma and carcinoma, the diagnosis being based on histological evidence of capsular or vascular invasion. Biopsy of the metastatic lesion makes the diagnosis straightforward (5), as in our case, where histology of the forearm swelling helped establishing the diagnosis of the primary pathology. Hematogenous spread occurs to the bones, lungs, brain, liver and adrenal glands in decreasing order of frequencies (6). Bony metastasis frequently involves the vertebrae, pelvis, sternum, long bones and the ribs (7). There are only a few reports regarding the initial presentation of patients with distant metastasis leading to a diagnosis of FTC. The rate of distant metastasis was reported to be 25% in a series of 448 patients with FTC (6). Emerick et al. (3) reported 2 patients (3.6%) with distant metastasis at presentation, and Shaha et al. (8) reported a higher incidence of distant metastasis (11%) in a series of 1,038 patients with FTC, in which 4% presented initially with distant metastatic disease. However, presentation with synchronous metastases to the bone and soft tissue, as in our case, is an extremely rare event and has not been reported so far. The aggressiveness of FTC varies widely and metastatic disease is the primary cause of death (1).

The management strategy of FTC with distant metastasis is well-defined, and it includes a total thyroidectomy with a block dissection of the neck nodes, when present, followed by whole body scan with 5 mCi of  $^{131}\text{I}$  after 4 to 6 weeks (2). An ablative dose of  $^{131}\text{I}$  ( $\geq 30$  mCi) is given if there is any residual

thyroid tissue or metastases concentrating  $^{131}\text{I}$  (9). All patients receive life long suppressive dose of thyroxine (0.3 to 0.4 mg daily) (2). Preoperative measurement of serum thyroglobulin is an important additional tool for the diagnosis of thyroid carcinoma, and the postoperative level acts as a marker for recurrent disease or distant metastasis (10). Total body radioiodine scan during the first few years is routinely used as the follow-up for high-risk patients.

## REFERENCES

1. Sevinc A, Buyukberber S, Sari R, Baysal T, Mizrak B. *Follicular thyroid cancer presenting initially with soft tissue metastasis*. *Jpn J Clin Oncol* 2000; 30: 27-9.
2. Rao RS, Parikh HK. *Prognostic factors in well differentiated carcinoma of thyroid*. In: Shah DH, Samuel AM, Rao RS, editors, *Thyroid cancer: an Indian perspective (1st edn)*. Mumbai: Quest Publications, 1998; 443-50.
3. Emerick GT, Duh QY, Siperstein AE, Burrow GN, Clark OH. *Diagnosis, treatment and outcome of follicular thyroid carcinoma*. *Cancer* 1993; 72: 3287-95.
4. Reeve TS, Delbridge L, Crummer P. *Total thyroidectomy in the management of differentiated thyroid cancer: a review of 258 cases*. *Aust N Z J Surg* 1986; 56: 829-33.
5. Vittal S. *Current concepts in the malignancy of thyroid*. In: Gupta RL, editor, *Recent advances in surgery (7)*. New Delhi: Jaypee Publishers 2000; 152-8.
6. Girelli ME, Casara D, Rubello D, Piccolo M, Piotta A, Pelizzo MR, Busnardo B. *Metastatic thyroid carcinoma of the adrenal gland*. *J Endocrinol Invest* 1993; 16: 139-41.
7. Paksoy N, Altiner M, Tuzuner S, Ozturk H. *Metastatic follicular carcinoma of the thyroid simulating sarcoma of limb*. *Pathologica* 1994; 86: 314-5.
8. Shaha AR, Shah JP, Loree TR. *Differentiated thyroid cancer presenting initially with distant metastasis*. *Am J Surg* 1997; 174: 474-6.
9. Lin JD, Chao TC, Huang MJ, Weng HF, Tzen KY. *Use of radioactive iodine for thyroid remnant ablation in well differentiated thyroid carcinoma to replace thyroid reoperation*. *Am J Clin Oncol* 1998; 21: 77-81.
10. Hocevar M, Auersperg M. *Role of serum thyroglobulin in the preoperative evaluation of follicular thyroid tumors*. *Eur J Surg Oncol* 1998; 24: 553-7.