

First Male Case of Lymphocytic Hypophysitis in Korea

Lymphocytic hypophysitis is a rare inflammatory disorder which is caused by autoimmune destruction of the pituitary gland. Almost all reported cases have been in women and the disease is often associated with pregnancy. We describe here the first male case of lymphocytic hypophysitis in Korea. The patient presented with headache, impotence, decreased libido, and deteriorated vision. Endocrinologic studies showed panhypopituitarism, and pituitary MRI imaging revealed a homogeneously enhanced pituitary mass with a thickened stalk. Treatment with prednisolone and thyroid hormone for five months was ineffective. Transsphenoidal resection of the pituitary mass was performed successfully with normalization of the visual field defect. Histologic examination revealed diffuse lymphocytic infiltration with dense collagenous fibrosis, consistent with lymphocytic hypophysitis. Lymphocytic hypophysitis should be considered in differential diagnosis even in men with hypopituitarism and an enlarged pituitary gland.

Key Words : Autoimmune Diseases of the Nervous System; Pituitary Gland; Hypopituitarism; Pituitary Diseases; Brain Diseases

Hyun-Kyung Chung, Doh Hyung Kim,
Sang Jun Kim*, Bong Jin Park[†],
Eo-Jin Kim[‡], Na-Hye Myong[‡],
Sang Jeon Choi

Department of Internal Medicine, Radiology*,
Neuro Surgery[†] and Pathology[‡], College of Medicine,
Dankook University, Cheonan, Korea

Received : 18 April 2002
Accepted : 11 June 2002

Address for correspondence

Hyun-Kyung Chung, M.D.
Department of Internal Medicine, College of Medicine,
Dankook University, San 16-5, Anseo-dong,
Cheonan 330-715, Korea
Tel : +82-41-550-3057, Fax : +82-41-556-3256
E-mail : chkendo@dankook.ac.kr

INTRODUCTION

Lymphocytic hypophysitis is a rare disorder of the pituitary gland. It is occasionally associated with other autoimmune diseases including thyroiditis (1), pernicious anemia (2), adrenalitis (3), and systemic lupus erythematosus (4), suggesting an autoimmune pathogenesis. Patients usually present with a pituitary mass lesion and with variable loss of pituitary function. The disease is characterized by diffuse infiltration of lymphocytes and plasma cells followed by necrosis, surrounding parenchymal fibrosis. Surgical removal of the mass is warranted both for confirmative diagnosis and definite treatment (5), especially in cases with deteriorated vision and ongoing mass effects. Most reported cases are in women during late pregnancy or in the postpartum period (6), and only approximately 10 cases have been reported in males. Because of its low prevalence in males, lymphocytic hypophysitis has not often been included in the differential diagnosis of pituitary mass lesions in male patients. In this report, we describe the first male patient with lymphocytic hypophysitis in Korea.

CASE REPORT

A 38-yr-old man presented with an 8-month history of frontal headache. His headache was unremitting, progressive, and associated with dizziness. He also described profound

weakness, constipation, decreased libido, impotence, weight loss of 6 kg over the last 1 yr and combined visual disturbance, nausea, and vomiting of recent one month. He denied any fever, seizures, or motor deficit. He had no significant past medical history. There was no family history of endocrine or autoimmune disease. On admission, his appearance was suggestive of chronic disease. The skin was pale and dry. Blood pressure was 110/70 mmHg; pulse was regular at 78 beats/min. Axillary hair was normal and there was no thyroid enlargement. Fundoscopic examination was normal; however, perimetry revealed a right temporal visual field defect.

Laboratory evaluation demonstrated a white blood cell count of 9,520/ μ L with eosinophilia (1,120/ μ L of blood). Serum glucose and electrolyte levels were normal. Serum TSH was 0.35 (0.25-4.00 μ IU/mL) and free T₄ was 0.42 (0.60-1.80 ng/dL). TSH receptor antibody, antimicrosomal antibody, and antithyroglobulin antibody were negative. Antinuclear antibody was negative. An early morning cortisol level was 4.50 (2.5-25 μ g/dL), serum testosterone was less than 0.1 (2.55-7.53 ng/mL), LH 0.59 (1-8 IU/L), FSH 1.07 (2-10 IU/L), somatostatin-C 268.30 (36-768 ng/mL), and prolactin was 2.81 (0-25 ng/mL). Combined anterior pituitary function test was performed with regular insulin 0.3 U/kg, TRH 400 μ g, and LHRH 100 μ g; the result showed partially retained ACTH and FSH response, but compromised response to GH, TSH, prolactin, and LH (Table 1). MRI imaging of the pituitary gland demonstrated a 2.5 \times 1 cm-sized, isodense, well-enhanced pituitary mass with

suprasellar extension, compressing the optic chiasm and thickened stalk (Fig. 1A).

For treatment of combined paranasal sinusitis which lim-

Table 1. Serum levels of TSH, PRL, FSH, LH, ACTH, GH after administration of TRH, LHRH, and insulin

	0 min	30 min	60 min	90 min	120 min
Glucose (mg/dL)	72	43	83	90	90
TSH (μ U/mL)	0.65	1.57	1.25	1.14	1.09
PRL (mg/L)	2.98	2.07	2.46	2.68	3.05
FSH (IU/L)	0.68	6.31	2.93	3.56	3.23
LH (IU/L)	0.86	1.35	1.09	1.38	0.85
GH (μ g/L)	2.48	0.87	1.05	1.56	2.17
ACTH (pg/mL)	5.101	0.401	1.50	9.20	8.40

ited transsphenoidal approach, we started antibiotics therapy with prednisolone (20 mg/day) and thyroxine (100 μ g/day) replacement. After 5 months treatment, a follow-up MRI did not show any change in the size of the pituitary mass (Fig. 1B). The patient complained of progressive compression symptoms including deteriorated vision, severe headache, and dizziness. Thus, transsphenoidal pituitary mass resection was carried out for diagnostic and therapeutic purposes. The lesion was firm with an ill-defined margin. The histopathologic findings were compatible with lymphocytic hypophysitis: diffuse, non-granulomatous infiltration of lymphocytes, some eosinophils and plasma cells (Fig. 2A) with dense collagenous fibrosis (Fig. 2B). Post-operative course was complicated by diabetes insipidus, which resolved with DDAVP nasal spray.

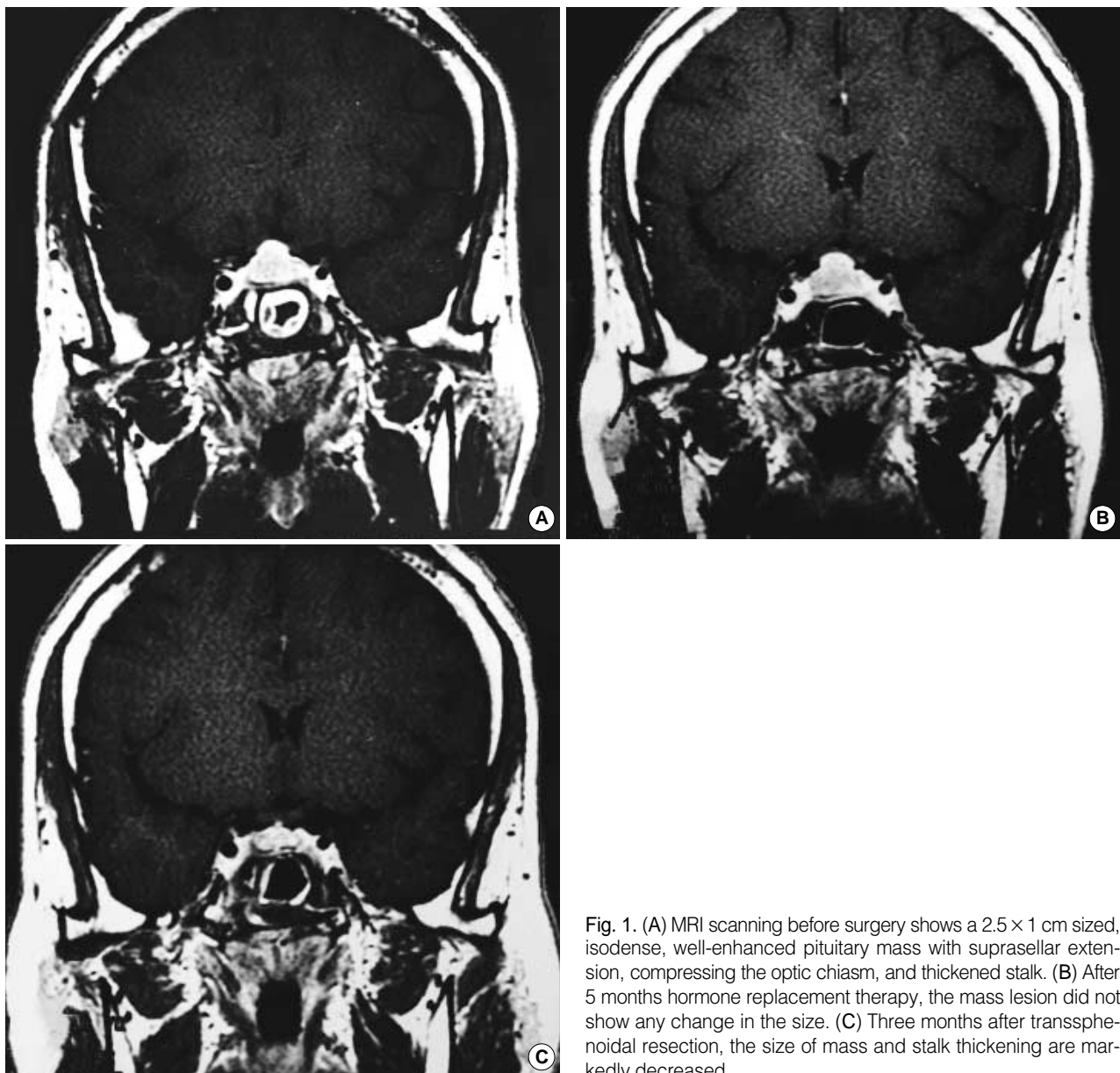


Fig. 1. (A) MRI scanning before surgery shows a 2.5×1 cm sized, isodense, well-enhanced pituitary mass with suprasellar extension, compressing the optic chiasm, and thickened stalk. (B) After 5 months hormone replacement therapy, the mass lesion did not show any change in the size. (C) Three months after transsphenoidal resection, the size of mass and stalk thickening are markedly decreased.

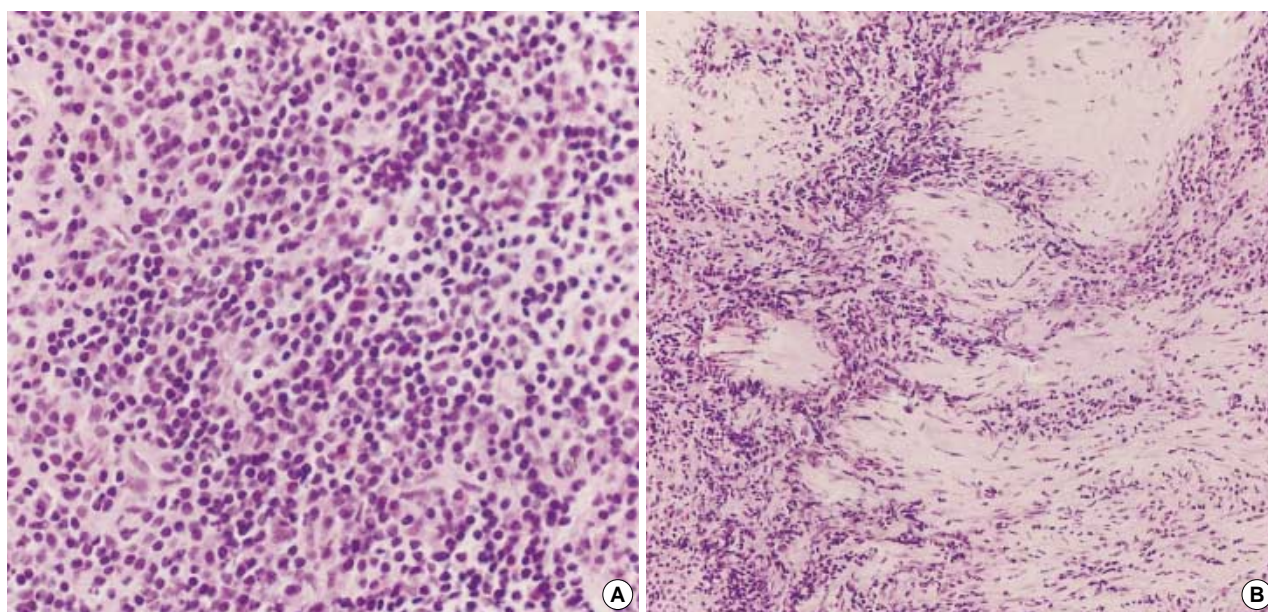


Fig. 2. Microscopic findings of the pituitary mass obtained at surgery. (A) Diffuse, non-granulomatous infiltration of lymphocytes, plasma cells, and some eosinophils with few persistent adenohypophyseal cells (H&E stain, $\times 200$). (B) Dense collagenous fibrosis is also noted (H&E stain, $\times 100$).

The patient's headache, nausea, and visual field defect were normalized soon after surgery, along with normalization of the eosinophil counts in peripheral blood (Fig. 3). MRI scan performed 3 months after surgery revealed a significantly decreased size of pituitary mass and decreased stalk thickening (Fig. 1C). The patient's adrenal and thyroid function improved with glucocorticoid and thyroxine replacement

therapy and his potency has improved in response to testosterone injection.

DISCUSSION

Lymphocytic hypophysitis is a rare inflammatory lesion of the pituitary gland. Since the first report of lymphocytic hypophysitis in 1962 (1), over 100 cases have been described in the English language literature. Almost all of these cases have been in women (6) and only about 10 cases have been in men. Two published cases in Korea were also women (4, 7). This report documents the first male patient with lymphocytic hypophysitis in Korea, who presented with profound fatigue and impotence associated with decreased libido. These symptoms have been documented as the most common symptoms of male patients presenting with lymphocytic hypophysitis (8, 9). The patient also showed a homogeneous contrast-enhancing mass with a thickened stalk, favoring the diagnosis of lymphocytic hypophysitis. Nevertheless, because of the rarity of this condition and the lack of previously reported male cases in Korea, it was considered more likely that the patient might have pituitary macroadenoma or another more common condition than lymphocytic hypophysitis until the diagnosis was made using pathologic findings. Thus, with this report, lymphocytic hypophysitis should be considered in differential diagnosis in men with hypopituitarism and enlarged pituitary glands.

Differential diagnosis of lymphocytic hypophysitis may include consideration of pituitary adenoma, and other parasel-

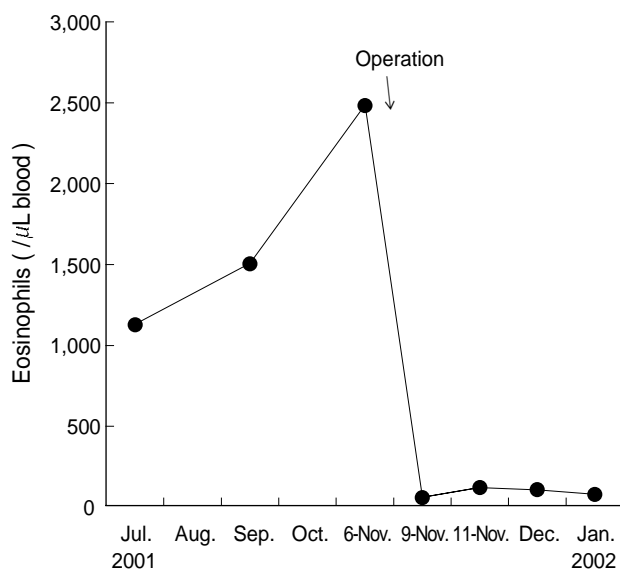


Fig. 3. Clinical course of lymphocytic hypophysitis and eosinophilia. The patient had definite eosinophilia when he presented, and it diminished significantly after operative treatment of lymphocytic hypophysitis.

lar tumors or tumor-like lesions including granulomatous hypophysitis. Among these conditions, pituitary adenoma may be most difficult to distinguish from lymphocytic hypophysitis (10). There are no typical features at presentation that can differentiate between pituitary inflammation and adenoma. Pituitary MRI cannot always differentiate lymphocytic hypophysitis from pituitary adenoma, even though there are some features that may favor a diagnosis of lymphocytic hypophysitis (11). In fact, in previous reports of lymphocytic hypophysitis in men, transsphenoidal exploration of the pituitary gland was usually carried out for putative adenoma (9). In this respect, it would be mandatory to have a better diagnostic imaging method or a reliable serologic marker for this disease, which could reduce the frequency of neurosurgical resection and associated irreversible pituitary failure. Such techniques might also facilitate recognition of lymphocytic hypophysitis in men and women, so that its prevalence and clinical spectrum could be determined with greater accuracy.

The exact etiology of lymphocytic hypophysitis is unknown, but several studies have suggested an autoimmune cause. Autoantibodies against pituitary cells were detected in some patients' sera, and approximately 30% of patients were found to have other organ-specific autoimmune diseases, such as Hashimoto's thyroiditis, adrenalitis, or pernicious anemia (12). In an animal study (13), T lymphocytes appeared to play a crucial role in the pathogenesis of lymphocytic hypophysitis, based on the finding that the disease could be induced by injection of recombinant rubella virus glycoprotein in normal animals, but not in animals subjected to neonatal thymectomy.

In this case study, the patient showed no evidence of combined autoimmune diseases, and several autoantibodies were negative. However, the patient presented with eosinophilia, which could be an indirect evidence of autoimmune basis. He had a definite eosinophilia (blood level of 1,000-2,500/ μ L) at presentation, which subsided significantly after operative treatment (30-50/ μ L). As indicated in a previous report, eosinophilia might be caused by the action of T lymphocytes; for example, CD4-positive helper T lymphocytes contain transcripts for and secrete interleukin-5, which stimulates proliferation of eosinophils (12). Furthermore, lymphocytic hypophysitis was associated with eosinophilia in the previous study (14). Thus, detailed studies of the pathogenic role and diagnostic significance of eosinophilia in patients with lymphocytic hypophysitis could be interesting, and could increase understanding of the pathogenic mechanism of this condition.

The natural history of lymphocytic hypophysitis has not been documented, thus the management of this disease is still controversial. Most studies suggest that the diagnosis of lymphocytic hypophysitis requires a histologic study, however, surgical intervention is not always necessary because the condition may resolve spontaneously (10). It has been proposed that patients without gross visual impairment should

be treated conservatively, including close observation and hormone replacement (15). In the case described herein, however, several points persuaded us to proceed with transsphenoidal resection of the pituitary mass lesion. Our patient complained of progressing, aggravating headache and visual deterioration. He had a definitely abnormal visual field at presentation and his visual acuity was progressively decreasing. We regarded those symptoms and signs as ongoing mass effects. After 5 months of conservative treatment with thyroxine and prednisolone replacement, his symptoms and signs did not improve and the follow-up pituitary MRI did not show any change in the size of the pituitary lesion. As mentioned above, we also could not rule out other causes of pituitary mass lesion such as macroadenoma, and were in need of confirmative histologic diagnosis. Furthermore, it has been suggested that in cases of severe fibrosis, operative treatment is preferred, because there is little chance for recovery with conservative management (16). Retrospectively, our patient had prominent dense collagenous fibrosis with diffuse infiltration of lymphocytes (Fig. 2B). Taken together, we believe that transsphenoidal resection was the optimal treatment for this patient.

In conclusion, we herein report the first male patient with lymphocytic hypophysitis in Korea, and suggest that lymphocytic hypophysitis should be considered in differential diagnosis of men (and women) with hypopituitarism and an enlarged pituitary gland. Furthermore, in cases where visual impairment or radiologic and neurologic deterioration occurs during the course of conservative treatment, surgical intervention is a viable option to make an accurate tissue diagnosis and provide definitive treatment.

REFERENCES

1. Goudie RE, Pinkerton PH. *Anterior hypophysitis and Hashimoto's disease in young woman*. *J Pathol Bacteriol* 1962; 83: 584-5.
2. Megraill KM, Beyerl BD, Black PM. *Lymphocytic adenohypophysitis of pregnancy with complete recovery*. *Neurosurgery* 1987; 20: 791-3.
3. Lack EE. *Lymphoid hypophysitis with end organ insufficiency*. *Arch Pathol* 1975; 99: 215-9.
4. Lim DJ, Chung YG, Lee HK, Lee KC, Suh JK. *Lymphocytic hypophysitis, a case report*. *J Korean Neurosurg Soc* 1998; 27: 1611-4.
5. Jenkins PJ, Chew SL, Lowe DG, Afshar F, Charlesworth M, Besser GM, Wass JA. *Lymphocytic hypophysitis: unusual features of a rare disorder*. *Clin Endocrinol* 1995; 42: 529-34.
6. Thodou E, Asa SL, Kontogeorgos G, Kovacs K, Horvath E, Ezzat S. *Lymphocytic hypophysitis: clinicopathologic findings*. *J Clin Endocrinol Metab* 1995; 80: 2302-11.
7. Kim KT, Kim DG, Ihm SH, Kim BT, Choi MG, Chang YB, Park SW, Shin HS. *A case of lymphocytic hypophysitis*. *Korean J Intern Med* 1992; 43: 255-61.
8. Supler ML, Mickle JP. *Lymphocytic hypophysitis: report of a case*

- in a man with cavernous sinus involvement. Surg Neurol* 1992; 37: 472-6.
9. Lee JH, Laws ER Jr, Guthrie BL, Dina TS, Nochomovitz LE. *Lymphocytic hypophysitis: occurrence in two men. Neurosurgery* 1994; 34: 159-63.
10. Levine SN, Benzel EC, Fowler MR, Shroyer JV III, Mirfakhraee M. *Lymphocytic hypophysitis: clinical, and magnetic resonance imaging characterization. Neurosurgery* 1988; 22: 937-41.
11. Cheung CC, Ezzat S, Smyth HS, Asa SL. *The spectrum and significance of primary hypophysitis. J Clin Endocrinol Metab* 2001; 86: 1048-53.
12. Pestell RG, Best JD, Alford FP. *Lymphocytic hypophysitis. The clinical spectrum of the disorder and evidence for an autoimmune pathogenesis. Clin Endocrinol (Oxf)* 1990; 33: 457-66.
13. Yoon JW, Choi DS, Liang HC, Baek HS, Ko IY, Jun HS, Gillam S. *Induction of an organ-specific autoimmune disease, lymphocytic hypophysitis, in hamsters by recombinant rubella virus glycoprotein and prevention of disease by neonatal thymectomy. J Virol* 1992; 66: 1210-4.
14. Yamaguchi T, Abe H, Matsui T, Kaji H, Fukase M, Tamaki N, Chihara K. *Lymphocytic hypophysitis, pustulosis palmaris et plantaris and eosinophilia. Intern Med* 1994; 33: 150-4.
15. Noto H, Tsukamoto K, Hauashi S, Takano K, Fujita T, Kimura S. *Spontaneous recovery from hypopituitarism in a man with lymphocytic hypophysitis: a case report. Endocr J* 2001; 48: 483-6.
16. Nishioka H, Ito H, Miki T, Akada K. *A case of lymphocytic hypophysitis with massive fibrosis and the role of surgical intervention. Surg Neurol* 1994; 42: 74-8.