

RETAINED SUBINTIMAL PELLET IN A CAROTID ARTERY

MARIA MANOUSHI, MD¹, IOANNIS SARANTITIS, MD¹, SPYROS PAPADOULAS, MD, PHD²,
ATHANASIOS DIAMANTOPOULOS, MD³, STAVROS K. KAKKOS, MD, MSc, RVT, DIC, PHD²,
GEORGE LAMPROPOULOS, MD, PHD² AND IOANNIS A. TSOLAKIS, MD, PHD²

¹DEPARTMENT OF SURGERY, 'ST ANDREW' GENERAL HOSPITAL OF PATRAS, PATRAS, GREECE

²DEPARTMENT OF VASCULAR SURGERY, ³RADIOLOGY, UNIVERSITY HOSPITAL OF PATRAS, PATRAS, GREECE

A shotgun pellet is depicted in the present image in a carotid artery under the intima, which remained intact without local complications for up to six months. There is lack of data regarding the natural history of such a carotid pellet, but the experience from the myocardium is that, in the absence of infection, completely embedded missiles are usually asymptomatic, tolerated well and may be left in place.

KEY WORDS: Gunshot wound · Neck injuries · Foreign bodies · Carotid artery injuries.

A 63-year-old male presented to the emergency department being shot with a hunting shotgun from a distance of more than 10 m. He had multiple entry wounds from pellets in the neck, thorax, abdomen, scrotum and upper extremities, with no exit wounds. He was haemodynamically stable and had a whole body CT scan with no intravenous contrast because of chronic renal insufficiency. A pellet adjacent to the left common carotid artery was demonstrated, accompanied by a limited hematoma. Additionally, a pellet was shown next to the trachea, and multiple pellets throughout his torso. Carotid Duplex demonstrated a pellet embedded in the posterior-medial wall of the left common carotid artery, producing a focal intraluminal protrusion of the intima with no tear (Fig. 1). Bronchoscopy was normal. Repeat duplex and bronchoscopy after 48 hours did not show any change. Clopidogrel 75 mg once daily was prescribed and he was discharged after five days. At six months the patient was asymptomatic and repeat Duplex showed no interval changes.

Retained intramural pellet has not been previously reported for the carotids. Additionally, no retained intramural missiles or foreign bodies elsewhere in the cardiovascular system have been reported except for the myocardium. There is lack of data regarding the natural history of such a carotid pellet, but the experience from the myocardium is that, in the absence of

infection, completely embedded missiles are usually asymptomatic, tolerated well and may be left in place.¹⁾ It is prudent for our patient to be on a life-long follow-up with duplex ultrasound in order to reveal possible complications like dissection, erosion and pseudoaneurysm or arteriovenous fistula formation. Another possible late complication could be intimal erosion and pellet migration to intracranial circulation, as has

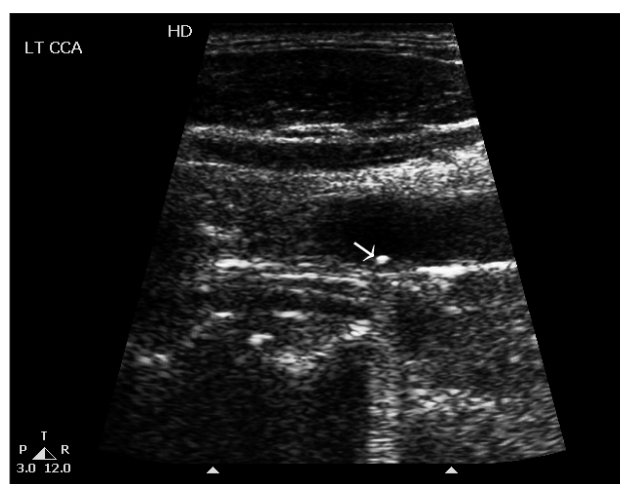


Fig. 1. A Duplex ultrasound six months after the injury depicts the subintimal pellet in the initial position with an acoustic shadow.

• Received: March 6, 2011 • Revised: April 11, 2011 • Accepted: May 25, 2011

• Address for Correspondence: Spyros Papadoulas, Department of Vascular Surgery, University Hospital of Patras, 26504, Rio, Patras, Greece
Tel: +302613603360, Fax: +302613603406, E-mail: spyros.papadoulas@gmail.com

• This is an Open Access article distributed under the terms of the Creative Commons Attribution Non-Commercial License (<http://creativecommons.org/licenses/by-nc/3.0>) which permits unrestricted non-commercial use, distribution, and reproduction in any medium, provided the original work is properly cited.

been previously described in acute cases.²⁾ Lead toxicity, another well-recognized late complication can occur months to years after the event.³⁾

REFERENCES

1. Symbas PN, Picone AL, Hatcher CR, Vlasis-Hale SE. *Cardiac missiles. A review of the literature and personal experience. Ann Surg* 1990;211:639-47; discussion 647-8.
2. Cogbill TH, Sullivan HG. *Carotid artery pseudoaneurysm and pellet embolism to the middle cerebral artery following a shotgun wound of the neck. J Trauma* 1995;39:763-7.
3. Coon T, Miller M, Shirazi F, Sullivan J. *Lead toxicity in a 14-year-old female with retained bullet fragments. Pediatrics* 2006;117:227-30.