

A CASE OF SUCCESSFUL TREATMENT OF FEMORAL ARTERY PSEUDOANEURYSM USING THROMBIN INJECTION

NAM SIK YOON, MD¹, SUN HO HWANG, MD¹, KYE HUN KIM, MD¹, JONG CHUN PARK, MD, PHD¹, JUNG CHAE KANG, MD, PHD¹ AND OCK KYU PARK, MD, PHD²

¹DIVISION OF CARDIOLOGY, HEART CENTER, CHONNAM NATIONAL UNIVERSITY HOSPITAL, GWANGJU, KOREA

²DIVISION OF CARDIOLOGY, WONKWANG UNIVERSITY HOSPITAL, IKSAN, KOREA

KEY WORDS: Pseudoaneurysm · Thrombin.

A seventy years-old female complained of a pulsating mass in right inguinal area after elective percutaneous coronary intervention. The size of mass was about 3 cm.

Femoral artery US was performed. A 3.2 cm × 1.5 cm × 15 cm sized pseudoaneurysm which was surrounded by some hematoma was identified. Doppler revealed high velocity

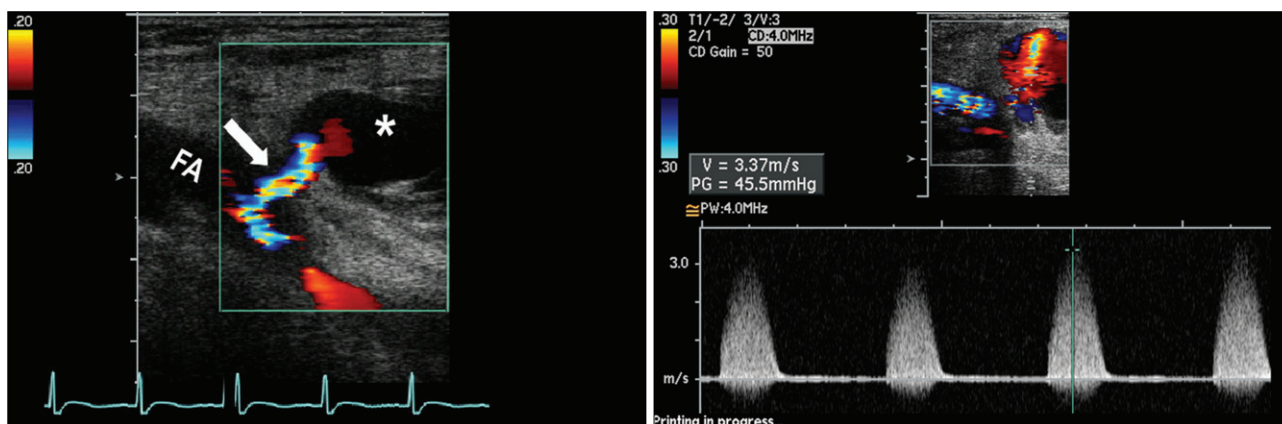


Fig. 1. Duplex ultrasound image showed 3.2 × 1.5 cm sized pseudoaneurysm (*) and high velocity flow through a neck (arrow) from femoral artery (FA).

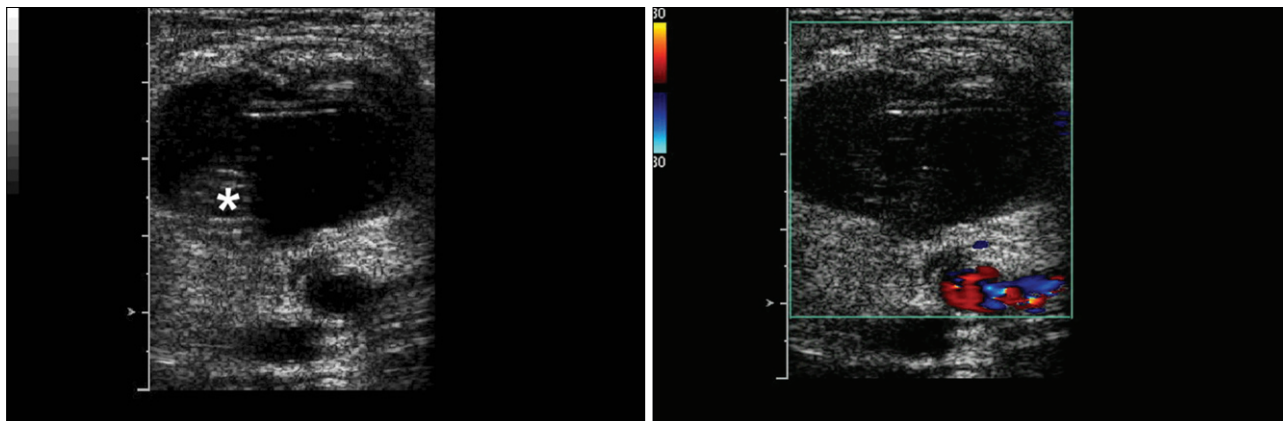


Fig. 2. During thrombin injection, rapidly developed thrombus (*) was identified within aneurysm sac.

• Received: September 5, 2006 • Accepted: April 29, 2008

• Address for Correspondence: Jung Chae Kang, Division of Cardiology, Heart Center, Chonnam National University Hospital, 8 Hak-dong, Dong-gu, Gwangju 501-757, Korea Tel: +82-62-220-5784, Fax: +82-62-223-3105, E-mail: jcpark@chonnam.ac.kr

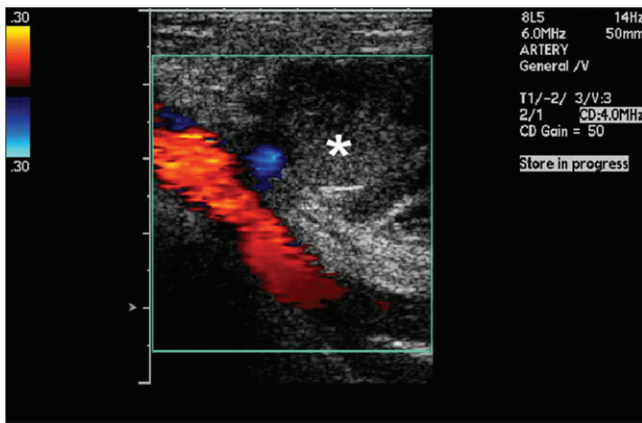


Fig. 3. After 2,000 units of thrombin injection, pseudoaneurysm was filled with thrombus (*) and high velocity flow was nearly completely disappeared.

blood flow from femoral artery to pseudoaneurysm (Fig. 1). First of all, manual compression was done. Despite of manual compression, there was no definite decrease in size. So, we planned to perform thrombin injection. Thus, total 2000 U of thrombin was injected to pseudoaneurysm, after thrombin injection, with clot formation, blood flow to pseudoaneurysm was nearly disappeared and minimal leak was noted (Fig. 2 and 3).¹⁾²⁾

REFERENCES

1. Middleton WD, Dasyam A, Teefey SA. *Diagnosis and treatment of iatrogenic femoral artery pseudoaneurysms. Ultrasound Q* 2005;21:3-17.
2. Lennox AF, Griffin MB, Chesire NJ, Peters NS, Foale RA, Nicholaides AN. *Treatment of an iatrogenic femoral artery pseudoaneurysm with percutaneous duplex-guided injection of thrombin. Circulation* 1999; 100:e39-41.