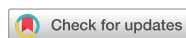

Images in Cardiovascular Medicine



Optical Coherence Tomography-guided Treatment of Multiple Stent Fracture in Patients with Overlapping Drug-eluting Stents

Jung-Hee Lee , MD, PhD and Ung Kim , MD, PhD

Division of Cardiology, Yeungnam University Medical Center, Yeungnam University College of Medicine, Daegu, Korea

OPEN ACCESS

Received: Apr 19, 2018

Accepted: Jul 31, 2018

Correspondence to

Jung-Hee Lee, MD, PhD

Division of Cardiology, Yeungnam University
College of Medicine, Yeungnam University
Medical Center, 170, Hyeonchung-ro, Nam-gu,
Daegu 42415, Korea.

E-mail: seranflute@gmail.com,
seranflute@yu.ac.kr

Copyright © 2018. The Korean Society of
Cardiology

This is an Open Access article distributed
under the terms of the Creative Commons
Attribution Non-Commercial License (<https://creativecommons.org/licenses/by-nc/4.0>)
which permits unrestricted noncommercial
use, distribution, and reproduction in any
medium, provided the original work is properly
cited.

ORCID iDs

Jung-Hee Lee

<https://orcid.org/0000-0002-0342-6360>

Ung Kim

<https://orcid.org/0000-0002-6009-1843>

Funding

This work was supported by a grant from the
Yeungnam University, Korea.

Conflict of Interest

The authors have no financial conflicts of
interest.

A 71-year-old man presented with exertional angina. Ten years ago, he had undergone treatment for myocardial infarction with two heterogeneous drug-eluting stents (DESs) in the right coronary artery (RCA): 4.0×30-mm Endeavor™ (Medtronic, Minneapolis, MN, USA) and 3.5×32-mm Taxus™ (Boston Scientific, Natick, MA, USA). Coronary angiography revealed intraluminal haziness in the middle of the previous RCA stent without significant in-stent restenosis (**Figure 1A**). However, magnified fluoroscopic images showed suspicious complete separation with displacement of the DES overlapping site (**Figure 1B**). Optical coherence tomographic (OCT) images showed multiple stent fractures with four gaps, confirmed on 3-dimensional (3D) reconstructed strut images (**Figure 1C and D**). The first gap was located at the Taxus™, the second gap with displacement was at overlapping site, and the third / fourth gaps were at the Endeavor™. Cross-sectional OCT images revealed tight stenosis with false lumen at the stent displacement point (**Figure 1, a-d**); the minimal lumen area was 1.68 mm². Before percutaneous coronary intervention, the concern was guide-wire position, which might be out of the fractured stent. However, the OCT images showed that the guide-wire was located clearly within the fractured stents (**Figure 1E**). The distance between the first gap and the fourth gap was more than 35 mm, as confirmed by longitudinal OCT images (**Figure 1C**). However, the purpose of a newer stent implantation was not the whole coverage of the pervious stent fracture, but treatment of the tight stenosis at the stent displacement point. Therefore, the lesions including both fracture sites were treated with implantation of 4.0×18-mm Resolute Onyx™ (Medtronic, Minneapolis, MN, USA), corresponding to the length of the tight stenotic lesion. Unfortunately, we could not perform a post-stent OCT imaging because of the risk of contrast-induced nephropathy. However, the final angiogram revealed good distal flow without any residual stenosis or dissection (**Figure 1F**).

Multiple stent fracture after DES implantation is extremely rare, associated with a higher rate of adverse clinical outcomes.¹⁾ The risk factors of stent fracture are stenting in the RCA, longer and overlapped stents, hinge movement and vessel angulation; our case showed all these findings.^{2,3)} This case shows that the OCT-guided procedure easily identified multiple fracture, whereas conventional angiography could not.

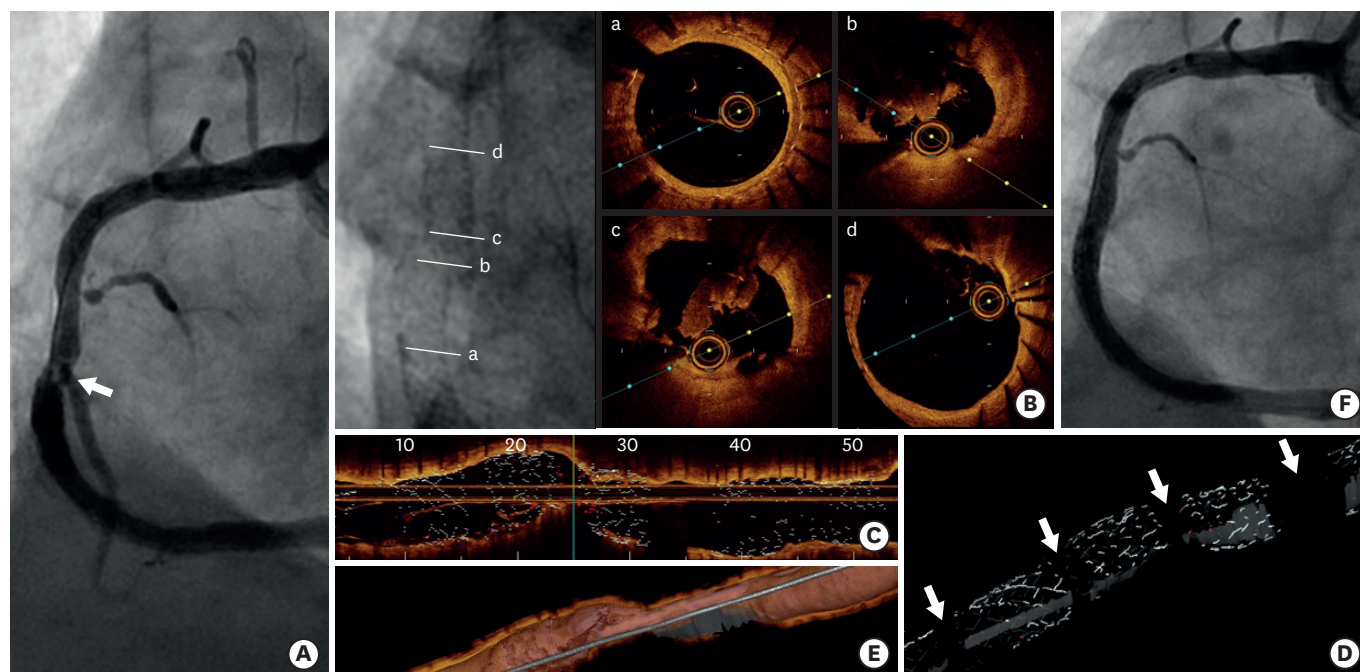


Figure 1. (A) Coronary angiography shows intraluminal haziness (arrow) at the mid portion of the previous right coronary artery stent without significant in-stent restenosis. (B) Magnified fluoroscopic images showed suspicious complete separation with displacement of the previous drug-eluting stent overlapping site. (a-d) show each site of axial optical coherence images. (C) Longitudinal optical coherence tomographic images showed multiple stent fractures with 4 gaps. (D) 3D reconstructed stent strut images clearly demonstrated multiple stent fracture with 4 gaps (arrows). (E) 3D reconstructed images showed that the guide-wire was clearly inside the whole fractured stents. (F) After 4.0x18-mm Onyx (Medtronic, Minneapolis, MN, USA) implantation, the final angiogram revealed good distal flow without any residual stenosis or dissection. 3D = 3-dimensional.

Author Contributions

Conceptualization: Lee JH; Data curation: Lee JH; Formal analysis: Lee JH; Investigation: Lee JH; Methodology: Lee JH; Writing - original draft: Lee JH; Writing - review & editing: Lee JH, Kim U.

REFERENCES

1. Kan J, Ge Z, Zhang JJ, et al. Incidence and clinical outcomes of stent fractures on the basis of 6,555 patients and 16,482 drug-eluting stents from 4 centers. *JACC Cardiovasc Interv* 2016;9:1115-23. [PUBMED](#) | [CROSSREF](#)
2. Kim U, Kim DI, Kim DK, et al. Long-term clinical and angiographic outcomes of patients with sirolimus-eluting stent fracture. *Int J Cardiol* 2012;158:83-7. [PUBMED](#) | [CROSSREF](#)
3. Doi H, Maehara A, Mintz GS, et al. Classification and potential mechanisms of intravascular ultrasound patterns of stent fracture. *Am J Cardiol* 2009;103:818-23. [PUBMED](#) | [CROSSREF](#)