

Original Article

Feasibility of *In vivo* Proton Magnetic Resonance Spectroscopy for Lung Cancer

Soon Ho Yoon¹, Chang Min Park^{1,2}, Chang Hyun Lee^{1,3}, In-Chan Song¹, Hyun Ju Lee¹, Jin Mo Goo^{1,2}

¹Department of Radiology, Seoul National University College of Medicine, Institute of Radiation Medicine, Seoul National University Medical Research Center, Seoul, Korea

²Cancer Research Institute, Seoul National University, Seoul, Korea

³Seoul National University Hospital, Healthcare Gangnam Center, Seoul, Korea

Purpose : To investigate the feasibility of *in vivo* proton magnetic resonance spectroscopy (MRS) for evaluation of lung cancer.

Materials and Methods: This prospective study was approved by the institutional review board of our hospital and informed consent was obtained in all patients. Ten patients (7 men, 3 women; mean age, 64.4) with pathologically-proven lung cancer (mean, 56.8 mm; range, 44–77 mm) were enrolled to 1.5 T MRS using a single-voxel respiration-triggered point-resolved spectroscopic sequence. Technical success rate and the reason of technical failure, if any, were investigated.

Results: Out of 10 lung cancers, analyzable MRS spectra were obtained in 8 tumors (technical success rate, 80%). Two MRS datasets were not able to be analyzed due to serious baseline distortion. Choline and lipid signals were detected as major metabolites in analyzable MRS spectra.

Conclusion: *In vivo* proton MRS method using a single-voxel respiration-triggered point-resolved spectroscopic sequence is feasible in obtaining the MR spectra of lung cancer because these spectra were analyzable and high success rate was shown in our study although there was the limitation of small patient group.

Index words : Magnetic resonance · Spectroscopy · Lung cancer

INTRODUCTION

Lung cancer is currently the leading cause of cancer-specific death worldwide, with a death toll greater

than breast, prostate and colorectal cancer combined (1). However, at the time of diagnosis, over 75% of persons with lung cancer have loco-regional spread or distant metastases, substantially reducing the chance of survival (2). Thus, in patients with inoperable lung cancer, radiation therapy and chemotherapy are the most common treatment strategies employed. In order to optimize and avoid ineffective treatment, there is a critical need for the early evaluation of response to these treatments as well as early and precise prediction of survival probabilities, which will facilitate more appropriate therapeutic planning in patients with lung cancer.

Recently, the diagnosis of lung cancer and planning of cancer treatment have become more advanced due to the continued improvement of diagnostic imaging

• Received; February 20, 2012 • Revised; April 25, 2012

• Accepted; April 25, 2012

This study was supported by the Seoul National University Hospital Research Fund (grant 04-2007-0870) and Basic Science Research Program through the National Research Foundation of Korea (NRF) funded by the Ministry of Education, Science and Technology (grant number: 2011-0022379).

Corresponding author : Jin Mo Goo, M.D., Department of Radiology, Seoul National University Hospital, 101 Daehangno, Jongno-gu, Seoul 110-744, Korea.

Tel. 82-2-2072-2624, Fax. 82-2-743-7418

E-mail : jimgoo@plaza.snu.ac.kr

tools. Among them, in vivo proton magnetic resonance spectroscopy (MRS) which has been proven to provide additional information in characterizing and detecting the cellular chemistry of most brain tumors (3, 4), prostate (5), breast (6), and uterine cervix (7), is one of the most promising imaging tools for monitoring the treatment response of lung cancer to radiation therapy, or chemotherapy, or for screening patient populations with certain types of cancer treatment.

Previous studies dealing with in vitro proton MRS of the lung have shown higher levels of lactate at 1.3 ppm and choline-containing compounds at 3.2 ppm in lung cancer than in normal lung parenchyma (8–11). However, in vivo detection of choline using absolute measurement methods have not been easy due to variations in signal amplitudes measured in the lesions and the reference owing to magnetic field inhomogeneities which lead to uncertainties in concentration estimation (12). In addition, due to lung motion, performance of a spectroscopic examination with an absolute concentrations protocol required a considerable period of time.

Most recently, an acquisition and detection method for MRS using the point-resolved spectroscopic (PRESS) sequence has been introduced and proved to be sufficiently sensitive while requiring less time in MRS of breast (13) or liver tumors (14). However, to the best of our knowledge, there have been no studies regarding in vivo proton MRS of lung cancer. Therefore, the purpose of the present study was to investigate the feasibility of in vivo proton MRS for evaluation of lung cancer.

MATERIALS AND METHODS

This prospective study was approved by the institutional review board of our hospital and informed consent was obtained from all patients prior to MR examination.

Study Population

Between June 2007 and March 2009, 10 patients (7 men and 3 women; mean age, 64.4 years; age range, 44–77 years) with alleged lung cancer 40 mm or more (mean diameter, 56.8 mm, diameter range, 44–77 mm) were included in this prospective MRS study. The

patients with alleged lung cancer less than 40 mm were excluded as the acquisition of MRS data was expected to be easily failed considering the cardiorespiratory movement of alleged lung cancer.

MRI Technique

All MRI and proton MRS were performed using a whole-body 1.5-T scanner (General Electric EXITE HD, Milwaukee, WI) with a built-in body coil. Our chest MR protocol consisting of fast spin-echo T2-weighted (TR 611.3 msec, TE 86.7 msec, slice thickness 7 mm, slice gap 8.4 mm), three dimensional fast spoiled gradient echo fat-saturated T1-weighted (FSPGR; TR 4.1 msec, TE 2.0 msec, slice thickness 5 mm, slice gap 2.5 mm), and contrast-enhanced dynamic three-dimensional FSPGR T1W axial imaging was performed prior to acquisition of spectroscopic data to localize the lung mass. Localizing images for spectroscopic data acquisition was acquired by a spin-echo sequence (TR/TE, 350/30 msec; matrix size, 256×256 ; number of excitations, 1). Single-voxel MRS using the point resolved spectroscopy sequence (PRESS) was done with repetition time (TR) varying according to patients' respiration rate from 2050 to 3000 msec; echo time of 30 msec; number of excitations, 96; voxel size, $10 \times 10 \times 10$ mm; spectral width, 2500 Hz; and 2048 data points. Total acquisition time for each MR spectrum was 10 to 12 minutes including localization, pre-scan for shimming and other parameter adjustments, and real spectral acquisition ranging from 4.8 to 8.6 minutes. Location of a voxel of interest (VOI) was determined by one experienced radiologist (C.H.L. with 6 years of experience in chest MR imaging). Based on noncontrast T2-weighted, T1-weighted and contrast-enhanced MR images, the largest homogeneously enhancing solid portion of lung tumors was chosen, with attention paid to avoid inclusion of necrotic or cystic portions. Each patient was explained by the techniques of shallow and regular breathing prior to the procedure and these techniques were maintained during MRS data acquisition.

MR Image and Spectra Analysis

All MRIs of lung tumors were assessed by one chest radiologist (C.M.P. with 4 years of experience in chest MR imaging) and one MR physicist (I-C. S. with 15 years of experience in MRS) blinded to MR imaging

features and clinical data. MRS data were analyzed using commercially available software (SAGE 7.2, GE Medical Systems). All spectra were processed with 5-Hz Gaussian apodization and zero-filled to 4096 points.

We also assessed the technical success rate and investigated the reason of technical failure, if any, in those cases. MR spectra were defined to be analyzable quality if the line width of lipid peak at 1.2 ppm was less than 30 Hz after 5 Hz line broadening in spectral post-processing. Criteria for determining whether choline and lactate resonance was present were the peak at 3.2 ppm for choline and 1.3 ppm for lactate with a line width less than 15 Hz and signal-to-noise ratio (SNR) greater than 3. Spectra that revealed no significant choline or lactate resonance but met the criteria for analyzable quality were included. Those with serious baseline distortion impeding the recognition of lipid resonance, a broad lipid line width, or no observable lipid resonance were excluded from analysis. The choline-to-lipid ratio was measured by dividing the peak area of choline at 3.2 ppm by the peak area of lipid at 1.2 ppm.

RESULTS

All patients (n = 10) were finally diagnosed with lung cancer, i.e., squamous cell carcinoma (n = 4), adenocarcinoma (n = 3), small cell carcinoma (n = 2),

and adenoid cystic carcinoma (n = 1) histopathologically from specimens obtained by lobectomy (n = 3), pneumonectomy (n = 2), percutaneous biopsy (n = 3), and bronchoscopic biopsy (n = 2). The mean duration between the pathologic diagnosis and the MR scans was 7.8 days (range: 1 ~ 35 day). Three lesions were located in the left upper lobe, three in the left lower lobe, two in the right middle lobe and two in the right lower lobe.

Table 1 summarizes the MR spectroscopic findings of lung cancers in the 10 patients. Among the 10 lung cancers, spectra of analyzable quality were obtained in 8 tumors (technical success rate, 80%). Two MRS datasets could not be analyzed due to serious baseline distortion. Among the eight patients with analyzable MR spectra, resonance at 3.2 ppm attributed to a choline-containing compound was detected in four patients (two patients with adenocarcinoma, one with small cell carcinoma and one adenoid cystic carcinoma, Figure 1). In the remaining four patients (three patients with squamous cell carcinoma, and one with small cell carcinoma), a choline peak was not detected. Lactate was not detected in any patient. Mean choline SNR of lung cancers was 10.0 ± 14.4 (range, 0 – 31.2). Mean lipid SNR of lung cancers was 152.1 ± 97.7 (range, 11.1 – 290.0). The mean choline-to-lipid ratio of lung cancers was 0.2 ± 0.34 (range, 0 – 0.96). All negative findings were confirmed based on the absence of any identifiable signal at 3.2 ppm for choline and 1.3 ppm for lactate above the baseline noise on the spectra.

Table1. In Vivo Proton Magnetic Resonance Spectroscopic and Pathologic Findings

No.	Age	Sex	Tumor location	Tumor size (mm)	Pathologic diagnosis	Analyzable spectra	Choline peak	Lactate peak	Lipid peak	Choline to lipid ratio
1	67	M	LUL	77	Squamous cell carcinoma	yes	0	0	171.3	0
2	73	M	LLL	56	Squamous cell carcinoma	yes	0	0	152.5	0
3	70	M	LLL	44	Small cell carcinoma	yes	31.2	0	66.8	0.47
4	44	M	LLL	48	Squamous cell carcinoma	yes	0	0	74.9	0
5	54	F	RLL	57	Adenocarcinoma	yes	10.7	0	11.1	0.96
6	66	M	LUL	45	Small cell carcinoma	yes	0	0	182	0
7	65	M	RML	50	Squamous cell carcinoma	no	–	–	–	–
8	69	F	RML	65	Adenoid cystic carcinoma	yes	41	0	268	0.15
9	74	M	LUL	65	Adenocarcinoma	no	–	–	–	–
10	68	M	RLL	61	Adenocarcinoma	yes	27	0	290	0.09

Note. = number, M= male, F= female, LUL = left upper lobe, LLL = left lower lobe, RLL = right lower lobe, RML = right middle lobe.

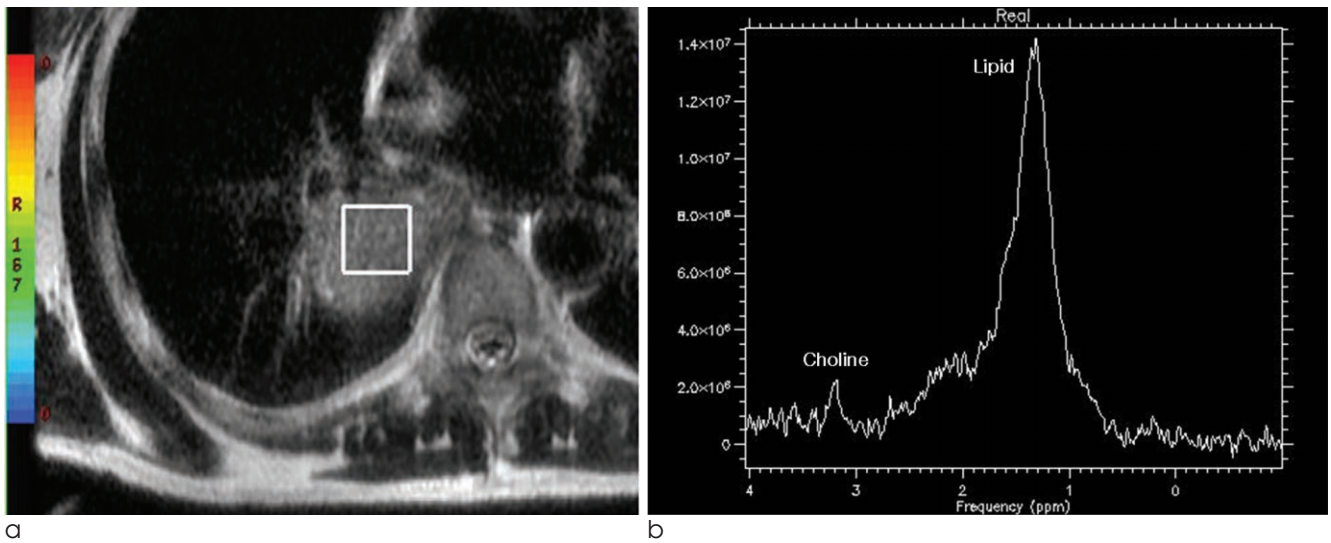


Fig. 1. In vivo proton magnetic resonance spectroscopy of a pathologically-proven adenocarcinoma in a 68-year-old man.
 a. Fast spin-echo T2-weighted axial image shows a large homogenous mass with intermediate high signal intensity in the superior segment of the right lower lobe. The voxel of interest is located within the mass. b. In vivo proton magnetic resonance spectroscopy spectra shows Choline peak at 3.2 ppm and Lipid peak at 1.2 ppm. The SNR of Choline peak was 27.0. The Choline to Lipid ratio is 0.09.

DISCUSSION

The main findings obtained in our preliminary study were that we successfully obtained analyzable in vivo MRS spectra of lung cancer in most patients and that choline compounds were detected in a limited number of patients. In vivo MRS of lung cancer has been rarely attempted due to the various technical difficulties including compromised localization on MRS using the stimulated-echo acquisition mode. However, the PRESS sequence with continued respiration-triggered acquisition as we have experienced was able to overcome these difficulties in part and provided analyzable spectra within 10–12 minutes using a clinical MR scanner.

There were two failure cases having serious baseline distortion on MRS spectra. The mean size of lung cancers in failure cases was similar with that in success cases (mean size, 57.5 mm vs. 56.6 mm). We failed to find any specific tendency in the tumor location or pathologic subtype of failure cases compared to those of success cases. The possible cause of failure in acquiring analyzable spectra was a intratumoral heterogeneity. Although we did not analyze a tumor texture quantitatively, T2 signal intensity of lung cancer in failure cases was visually more heteroge-

neous than that in success cases. Given that a loss of homogeneity leads to inconsistent acquisition of MRS spectra (15), the intratumoral inhomogeneity of lung cancer may increase a baseline noise and disturb an accurate acquisition of peak height of metabolites.

In this study, choline was detected in four of the eight patients with analyzable MRS spectra. Choline-containing compounds are known to be involved in both the synthesis and degradation of cellular membranes. Previous in vitro MRS studies revealed that choline could be detected in the extracts of both normal lung parenchyma and lung cancer, with lung cancer showing higher concentrations than normal lung parenchyma (9–11). Even though choline-containing compounds could be detected either in lung parenchyma or in lung cancer on in vitro MRS, the detected choline SNR in our study was thought to be truly detected within lung cancer rather than lung parenchyma considering following two aspects. First, MRS data was acquired within a voxel confined to the tumor using continued respiration-triggered acquisition. Additionally, in regard to lung parenchyma, MR signal of in vivo lung parenchyma could not be easily detected not only due to the low proton density of lung parenchyma compared to that of tissue extract, but also due to the predominant field inhomogeneity of lung parenchyma. The SNR of lung cancer in our

study was relatively high when it was compared with malignancies in other sites (16). The current result leads us to conclude that *in vivo* analysis of tumor metabolites using MRS may possibly be introduced for lung cancer along with the most advanced MRS technique to date which may overcome the pre-existing limitations of MRS.

Lactate, the end product of anaerobic glycolysis, is known to reflect tumor glucose metabolism. According to earlier researches (9, 17), lactate might be more useful than choline in predicting the prognosis of lung cancer. However, in the present study, although we tried to avoid placing the VOI in a nonviable portion of lung cancer such as a cystic or necrotic area by reviewing the contrast enhanced MR images, lactate was not detected in any enrolled patient. Even though contrast material within voxel may affect the acquisition of MRS signal, we do not believe that it is significant based on the results of the previous study (18). When we reviewed the analyzable MR spectra, lipid peak tended to be widened even though there were variations in their degrees. Given that the resonance peak of lactate and lipid is close, lipid signals may hinder the detection of lactate signals if the lipid peak is widened. Our observation is similar to the concern of Yokota et al. in that lipid signals could overlap and hinder the lactate signal on *in vivo* MRS (9). This result suggests that the detection of lactate remains a challenge with the current *in vivo* MRS technique.

One possible cause of failure in detecting choline and lactate is the field-strength of MR. Considering that MRS at 3.0 T increases the SNR of chemical compounds as well as chemical shift dispersion in comparison with MRS at 1.5 T (19), the detectability of choline compounds and lactate may be improved using the higher field-strength of 3.0 T MR. However, given that higher field strength increases field inhomogeneity which is one of the major problems of chest MR, it is not conclusive whether 3.0 T MR would improve the detectability of a trace amount of chemical compounds on chest MRS. Further study is warranted to address this issue.

The error of peak height of metabolites in spectra can be caused by variable elongations of TR ranging from 2050 to 3000 msec in this study as compared with that of conventional PRESS (1500 msec). The variably elongated TR according to patients' respira-

tion rate is somewhat inevitable as the lack of use of respiratory triggering results in trouble acquiring analyzable spectra in MRS for evaluating lung parenchymal lesions. These errors may be overcome by the postprocessing that gathers and analyzes the spectra with similar TRs among patients after multiple acquisition of MR spectroscopic data.

Respiratory and cardiac movements are supposed to hinder the detection of small amounts of metabolites within lung cancers (20). Given that the maximum three-dimensional movement of lung cancer was up to approximately 2 cm at normal respiration (21), 10 mm³ sized voxels might be transiently off the initially chosen location, or further the boundary of lung cancer during the acquisition of MRS data despite of continued respiration-triggered acquisition. Additionally, the respiratory movement of lung cancer might be intensified by the heartbeat of patient although the impact of heartbeat depends on how the lung cancer is close to heart (16). During cardiopulmonary movement, not only change of tumor tissue within the voxel but also change of surrounding tissues around the voxel may make the SNR of metabolites less significant.

Interestingly, lipid was detected in all patients with analyzable MRS spectra in our study. Based on *in vitro* MRS results, the concentration of lipid was higher in lung cancer than normal lung tissue (10, 11). Considering the paucity of lipid in normal lung parenchyma, the detection of lipid peak within the tumor on *in vivo* MRS might play a role in the evaluation of lung cancer. However, prior to interpretation of the significance of lipid peak, further investigation is required regarding whether the lipid signal on MRS was contributed by necrotic component within the tumor or by non-necrotic tumor component itself.

Considering the results of recent observations of *ex vivo* MRS in tissue metabolites of human lung cancers, *in vivo* MRS is expected to have a role in predicting benignity or malignancy of parenchymal lung lesion. There has been consistent results reporting the elevation of lactate, choline materials including phosphocholine, glycerophosphocholine and the reduction of glucose, acetate, myo-inositol and etc (8–11, 22). Furthermore, the differences between histologic subtype of lung cancer were also observed in *ex vivo* MRS (10). If the pre-existing difficulties in *in vivo* MRS for evaluating lung cancer can be

overcome, MRS can be used widely beyond current morphologic evaluation of lung cancer in the future.

There are some limitations in the present study. First, it is limited by a relatively small number of enrolled patients. Second, the pathologic diagnoses of lung cancer were heterogeneous. However, this may have been to some degree inevitable as the patients were prospectively enrolled prior to a pathologic diagnosis. Third, inflammatory lesions or benign neoplasms were not included as a control in this study. If included, the undertone of choline to lipid ratio might be assessed with regards to differentiating malignancies from benign lesion. However, we had focused lung cancer which is known to show an abnormal peak of choline and lactate on MRS, as the goal of our study was to investigate the technical feasibility of in vivo MRS in detecting metabolites within lung cancers.

In conclusion, in vivo proton MRS using the PRESS sequence with continued respiration-triggered acquisition is feasible but provides limited information in the evaluation of large (> 40 mm in diameter) lung cancers in regards to choline detection. In vivo acquisition of metabolite concentration in lung cancer may aid in tumor characterization even though it currently still remains challenging. Further studies using other sequences such as multivoxel MRS, averaging TE technique (23), or short echo time MRS (24) will be needed in order to improve the detection of chemical compounds.

Acknowledgements

This study was supported by the Seoul National University Hospital Research Fund (grant 04-2007-0870) and Basic Science Research Program through the National Research Foundation of Korea (NRF) funded by the Ministry of Education, Science and Technology (grant number: 2011-0022379).

References

- Brescia FJ. Lung cancer--a philosophical, ethical, and personal perspective. *Crit Rev Oncol Hematol* 2001;40:139-148
- Mulshine JL, Sullivan DC. Clinical practice. Lung cancer screening. *The New England Journal of Medicine* 2005;352:2714-2720
- Golder W. Magnetic resonance spectroscopy in clinical oncology. *Onkologie* 2004;27:304-309
- Howe FA, Barton SJ, Cudlip SA, et al. Metabolic profiles of human brain tumors using quantitative in vivo ¹H magnetic resonance spectroscopy. *Magn Reson Med* 2003;49:223-232
- Scheidler J, Hricak H, Vigneron DB, et al. Prostate cancer: localization with three-dimensional proton MR spectroscopic imaging-clinicopathologic study. *Radiology* 1999;213:473-480
- Yeung DKW, Cheung HS, Tse GMK. Human breast lesions: characterization with contrast-enhanced in vivo proton MR spectroscopy. *Initial results. Radiology* 2001;220:40-46
- Allen JR, Prost RW, Griffith OW, Erickson SJ, Erickson BA. In vivo proton (¹H) magnetic resonance spectroscopy for cervical carcinoma. *Am J Clin Oncol* 2001;24:522-529
- Hanaoka H, Yoshioka Y, Ito I, Niitu K, Yasuda N. In vitro characterization of lung cancers by the use of ¹H nuclear magnetic resonance spectroscopy of tissue extracts and discriminant factor analysis. *Magn Reson Med* 1993;29:436-440
- Yokota H, Guo J, Matoba M, Higashi K, Tonami H, Nagao Y. Lactate, choline, and creatine levels measured by vitro ¹H-MRS as prognostic parameters in patients with non-small-cell lung cancer. *J Magn Reson Imaging* 2007;25:992-999
- Duarte IF, Rocha CM, Barros AS, et al. Can nuclear magnetic resonance (NMR) spectroscopy reveal different metabolic signatures for lung tumours? *Virchows Arch* 2010;457:715-725
- Rocha CM, Barros AS, Gil AM, et al. Metabolic profiling of human lung cancer tissue by ¹H high resolution magic angle spinning (HRMAS) NMR spectroscopy. *J Proteome Res* 2010;9:319-332
- Christiansen P, Henriksen O, Stubgaard M, Gideon P, Larsson HB. In vivo quantification of brain metabolites by ¹H-MRS using water as an internal standard. *Magn Reson Imaging* 1993;11:107-118
- Stanwell P, Mountford C. In vivo proton MR spectroscopy of the breast. *Radiographics* 2007;27 Suppl 1:S253-S266
- Qayyum A. MR spectroscopy of the liver: principles and clinical applications. *Radiographics* 2009;29:1653-1664
- Opstad KS, Wright AJ, Bell BA, Griffiths JR, Howe FA. Correlations between in vivo (¹H) MRS and ex vivo (¹H) HRMAS metabolite measurements in adult human gliomas. *J Magn Reson Imaging* 2010;31:289-297
- Seppenwoolde Y, Shirato H, Kitamura K, et al. Precise and real-time measurement of 3D tumor motion in lung due to breathing and heartbeat, measured during radiotherapy. *Int J Radiat Oncol Biol Phys* 2002;53:822-834
- Guo J, Higashi K, Yokota H, et al. In vitro proton magnetic resonance spectroscopic lactate and choline measurements, ¹⁸F-FDG uptake, and prognosis in patients with lung adenocarcinoma. *J Nucl Med* 2004;45:1334-1339
- Smith JK, Kwok L, Castillo M. Effects of contrast material on single-volume proton MR spectroscopy. *AJNR Am J Neuroradiol* 2000;21:1084-1089
- Dydak U, Schar M. MR spectroscopy and spectroscopic imaging: comparing 3.0 T versus 1.5 T. *Neuroimaging Clin N Am* 2006;16:269-283
- Gabr RE, Sathyanarayana S, Schar M, Weiss RG, Bottomley PA. On restoring motion-induced signal loss in single-voxel magnetic resonance spectra. *Magn Reson Med* 2006;56:754-760
- Weiss E, Wijesooriya K, Dill SV, Keall PJ. Tumor and normal tissue motion in the thorax during respiration: analysis of volumetric and positional variations using 4D CT. *Int J Radiat Oncol Biol Phys* 2007;67:296-307
- Chen W, Zu Y, Huang Q, et al. Study on metabonomic characteristics of human lung cancer using high resolution magic-angle spinning ¹H NMR spectroscopy and multivariate data analysis. *Magn Reson Med* 2011;66:1531-1540
- Kuo YT, Li CW, Chen CY, Jao J, Wu DK, Liu GC. In vivo

proton magnetic resonance spectroscopy of large focal hepatic lesions and metabolite change of hepatocellular carcinoma before and after transcatheter arterial chemoembolization using 3.0-T MR scanner. J Magn Reson Imaging 2004;19:598-604

24. Gold GE, Pauly JM, Leung AN, et al. Short echo time MR spectroscopic imaging of the lung parenchyma. J Magn Reson Imaging 2002;15:679-684

대한자기공명의과학회지 16:40-46(2012)

폐암의 생체 수소자기공명분광법의 실행가능성

¹서울대학교 의과대학 영상의학교실, 서울대학교 의학연구원 방사선의학연구소

²서울대학교 암연구소

³서울대학교병원 강남센터

윤순호¹ · 박창민^{1, 2} · 이창현^{1, 3} · 송인찬¹ · 이현주¹ · 구진모^{1, 2}

목적: 폐암의 생체 수소자기공명분광법의 실행가능성을 탐색하고자 하였다.

대상과 방법: 이 전향적 연구는 해당병원의 임상시험심사위원회로 승인을 받았고 모든 환자로부터 사전동의를 받았다. 병리적으로 폐암으로 확인된 (평균 직경, 56.8 mm; 범위, 44-77 mm) 10명의 환자들에서 (남자 7명, 여자 3명; 평균나이, 64.4세) 단일 복셀 수소자기공명분광기법으로 호흡 유발 PRESS (point-resolved spectroscopic sequence)를 사용하여 1.5 T 수소자기공명 분광법을 시행하였다. 스펙트럼 습득의 기술적 성공률을 평가하고 실패한 증례들의 이유를 고찰하였다.

결과: 10개의 폐암 중 8개 폐암에서 분석 가능한 수소자기공명 분광 스펙트럼을 획득했다 (기술적 성공률, 80%). 두 개의 수소자기공명 분광 데이터는 심각한 기준치 왜곡으로 분석할 수 없었다. 대표적인 대사물질로 choline과 lipid들이 관찰되었다.

결론: 비록 제한적 수의 환자에서의 결과이지만 폐암에서 얻어진 생체 수소 자기공명 분광 스펙트럼이 분석가능하고 높은 성공률로 획득하였기 때문에 폐암 환자에서 호흡 유발 PRESS 방법을 사용한 생체 수소자기공명분광법이 실행 가능하다고 판단된다.

통신저자 : 구진모, (110-744) 서울시 종로구 대학로 101, 서울대학교병원 영상의학과
Tel. (02) 2072-2624 Fax. (02) 743-7418 E-mail: jmgoo@plaza.snu.ac.kr