

중복 자궁경부와 질중격을 가진 완전 중격 자궁의 변형

서울대학교 의과대학 산부인과학교실¹, 분당서울대학교병원 산부인과²

신미선¹ · 한경희¹ · 김수아¹ · 정희정¹ · 황은주¹ · 지병철^{1,2} · 서창석^{1,2}

A variant of complete septate uterus with double cervix and vagina: A case report

Mi Sun Shin, M.D.¹, Kyung Hee Han, M.D.¹, Su Ah Kim, M.D.¹, Hee Jung Jung, M.D.¹,
Eun Ju Hwang, M.D.¹, Byung Chul Jee, M.D.^{1,2}, Chang Suk Suh, M.D.^{1,2}

¹Department of Obstetrics and Gynecology, Seoul National University College of Medicine, Seoul;

²Department of Obstetrics and Gynecology, Seoul National University Bundang Hospital, Seongnam, Korea

Rare müllerian anomalies without any present classification were sometimes reported. A 30-year-old nulligravid woman was referred to our hospital with 2-year history of primary infertility. Laparoscopic examination revealed a relatively intact uterine fundus with both patent fallopian tubes. Hysteroscopic exam confirmed the presence of double vagina and cervix, as well as complete uterine septum with opening at the lower segment. Hysteroscopic septotomy was successfully performed through the right-sided cervix. A variant of complete septate uterus with double cervix that communicated at the isthmic portion could be successfully treated by hysteroscopic operation.

Key Words: Septate uterus, Double cervix, Longitudinal vaginal septum, Hysteroscopic septotomy

The septate uterus, the most common form of structural uterine anomaly, has significant effects on preterm labor, fetal presentation, infertility and spontaneous abortion.^{1,2} A rare variant of septate uterus, as combined with cervical duplication and a longitudinal vaginal septum, has been anecdotally reported.²⁻⁶ Although it is not included in the American Fertility Society classification of müllerian anomalies, it could be successfully treated by excision of the complete longitudinal vaginal septum followed by hysteroscopic

septotomy, sparing the double cervix.^{7,8}

The traditional embryologic hypothesis of müllerian development is the fusion of two ducts followed by unidirectional (caudal to cranial) absorption of intervening septum. However, the above mentioned anomalies support the bidirectional theory, i.e., absorption of septum proceeds from uterine isthmus into both directions.^{6,9}

Interesting cases of apparently normal uterus with blinded cervical pouch, dual cervices and complete sagittal vaginal septum were reported.^{10,11} Similar but unique cases were also reported; the women have a quite normal uterus with a longitudinal vaginal septum and double cervices that communicated at the in-

접 수 일 : 2010. 5. 19.
채 택 일 : 2010. 7. 26.
교신저자 : 서창석
E-mail : suhcs@snu.ac.kr

ternal os.¹²⁻¹⁴ All of these rare müllerian duct anomalies are inconsistent with the classical understanding of linear caudal-to-cephalad fusion. Here we report a case of complete septate uterus with a longitudinal vaginal septum and double cervixes that communicated at the lower segment of intervening septum.

Case Report

A 30-year-old nulligravid woman was referred to our hospital with 2-year history of primary infertility and suspicious uterovaginal anomaly. She had regular menstrual cycles ranged 30 to 32 days but complained of severe dysmenorrhea. Pelvic examination revealed a longitudinal vaginal septum and two distinct cervixes. The hysterosalpingogram was obtained by instillation of contrast medium into the left cervical canal, but the right hemi-uterus could be visualized concomitantly (Fig. 1A). The initial impression was a double uterus with both patent fallopian tubes. In addition, possible communication of both hemi-uteri at the lower segment was firstly suspected.

Further evaluation such as magnetic resonance imaging was not performed. An abdominal ultrasound showed both kidneys present. We decided to perform laparoscopy and concomitant hysteroscopy for the evaluation and correction of the uterovaginal anomaly. Both cervixes were ripened by vaginal insertion of 200 µg of prostaglandin E1 (misoprostol) into the left and right vaginal posterior fornix for preparation of hysteroscopy.

Laparoscopic exam revealed a relatively intact uterine fundus with normally located fallopian tubes (Fig. 1B). There was no evidence of uterine didelphys or bicornuate uterus. Periovarian filmy adhesion and moderately obliterated uterosacral ligament was identified and then lysed (Fig. 1C). Several superficial endometriotic foci in the pelvic peritoneum were excised and then coagulated.

Before introduction of hysteroscope, two 14-French Foley catheters were inserted into the uterus through each cervix (Fig. 1D). Hysteroscope was gently inserted into the right cervical canal and confirmed the presence of uterine septation with broad fundal base. Hysteroscopic exam through the right cervix also revealed the Foley catheter inserted through the left cervical canal. Hysteroscopic exam approached into the left cervix also identified the Foley catheter inserted through the right cervix (Fig. 1E). Thus small communication at the lower segment of intervening septum was confirmed. Final hysteroscopic septotomy was performed through the right sided cervix under assistance by laparoscopy and transabdominal sonography (Fig. 1F).

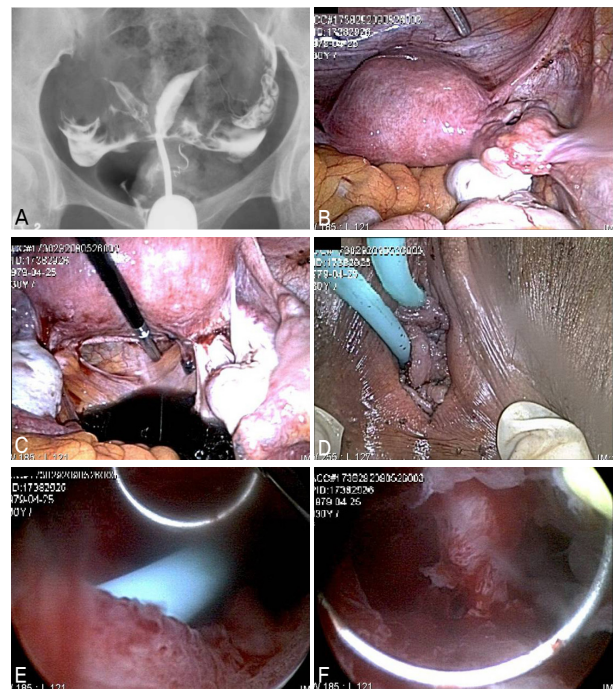


Fig. 1. A case of variant complete septate uterus with double cervix and vagina. (A) Preoperative hysterosalpingogram demonstrating both hemi-uteri by instillation of the left-sided cervix. Both tubes are patent. (B) A laparoscopic view of uterine fundus. (C) A laparoscopic view of uterine adnexa. (D) Two Foley catheters inserting through each cervix. (E) A hysteroscopic view of uterine cavity and septum with communication at the lower segment (through right-sided cervix). (F) A hysteroscopic view of excised septum (through right-sided cervix).

A test of tubal patency using indigocarmine solution confirmed the patency of both fallopian tubes. Finally viscoelastic gel (Gaurdix; Hanmi Pharma, Seoul, Korea) was applied around both uterine adnexa for adhesion prevention. We did not excise the longitudinal vaginal septum because she did not have difficulty in sexual intercourse. Also, we thought it best not to interfere with the following delivery by surgical intervention. The operation took about 100 minutes. The pathologic result of intrauterine septum was reported as proliferative endometrium with small myometrial tissue. Peritoneal biopsy was fibrous tissue with organizing hematoma. Her postoperative course was unremarkable, and she was discharged one day later without any events. We recommended oral cyclic estrogen-progestin for 3 months. After hormone treatment, she is now trying to become pregnant by ovarian stimulation.

Discussion

We described a rare and unique case of complete septate uterus with a longitudinal vaginal septum and double cervixes that communicated at the lower segment of intervening septum. Our case was similar to a case of septate bicervical uterus with isthmic communication shown in previous report by Acién et al⁶; however, a longitudinal vaginal septum was absent in that case report.

Our case could not be classified by traditional caudal-to-cranial müllerian fusion. An alternative embryologic mechanism was hypothesized that fusion occurs at the level of uterine isthmus and simultaneously proceeds in both cranial and caudal directions.⁹ Midline resorption also begins at the isthmus and is first directed caudally, unifying the cervix and vagina.

Our case was unique because it could be hypothesized that the müllerian fusion might be failed in the caudal direction and the septal resorption be failed in the cranial direction, sparing only small portion of intervening septum at the level of uterine isthmus.

Hysteroscopic metroplasty significantly improved the subsequent reproductive outcome for the septate uterus in women with recurrent spontaneous abortion.¹⁵ With no metroplasty, prognosis of pregnancy is relatively good in cases of complete septate uterus, but metroplasty can improve the reproductive outcome of complete septate uterus with spontaneous abortion.¹⁶

Management of septate uterus in women with otherwise unexplained infertility remains controversial. Previous reports indicate that improvement of pregnancy was modest after hysteroscopic metroplasty in women with septate uterus and otherwise unexplained infertility.^{1,15} However, there have been several reports regarding negative impact of septum on embryo implantation and improvement of implantation by resection of septum.¹⁷⁻²⁰ Therefore, prophylactic hysteroscopic metroplasty in asymptomatic women is recommended because it may prevent miscarriage or other obstetric complications and to optimize pregnancy outcomes.¹⁶ The metroplasty is strongly recommended especially in women with prolonged infertility, in women >35 years old, and in women contemplating assisted reproductive technologies.⁷

In conclusion, hysteroscopic septotomy under laparoscopy and/or transabdominal sonography is a simple and safe procedure in case of complete septate uterus with a longitudinal vaginal septum and double cervixes, irrespective of isthmic communication. The addition of a classification category allowing alternative developmental models should be considered.

References

- Grimbizis GF, Camus M, Tarlatzis BC, Bontis JN, Devroey P. Clinical implications of uterine malformations and hysteroscopic treatment results. *Hum Reprod Update* 2001; 7: 161-74.
- Wai CY, Zekam N, Sanz LE. Septate uterus with double cervix and longitudinal vaginal septum. A case report. *J Reprod Med* 2001; 46: 613-7.
- Fatum M, Rojansky N, Shushan A. Septate uterus with cervical duplication: rethinking the development of mullerian anomalies. *Gynecol Obstet Invest* 2003; 55: 186-8.
- Duffy DA, Nulsen J, Maier D, Schmidt D, Benadiva C. Septate uterus with cervical duplication: a full-term delivery after resection of a vaginal septum. *Fertil Steril* 2004; 81: 1125-6.
- Pavone ME, King JA, Vlahos N. Septate uterus with cervical duplication and a longitudinal vaginal septum: a mullerian anomaly without a classification. *Fertil Steril* 2006; 85: 494.e9-10.
- Acien P, Acien M, Sanchez-Ferrer ML. Mullerian anomalies "without a classification": from the didelphys-unicollis uterus to the bicervical uterus with or without septate vagina. *Fertil Steril* 2009; 91: 2369-75.
- Wang JH, Xu KH, Lin J, Chen XZ. Hysteroscopic septum resection of complete septate uterus with cervical duplication, sparing the double cervix in patients with recurrent spontaneous abortions or infertility. *Fertil Steril* 2009; 91: 2643-9.
- Patton PE, Novy MJ, Lee DM, Hickok LR. The diagnosis and reproductive outcome after surgical treatment of the complete septate uterus, duplicated cervix and vaginal septum. *Am J Obstet Gynecol* 2004; 190: 1669-75.
- Taylor E, Gomel V. The uterus and fertility. *Fertil Steril* 2008; 89: 1-16.
- Candiani M, Busacca M, Natale A, Sambruni I. Bicervical uterus and septate vagina: report of a previously undescribed Mullerian anomaly. *Hum Reprod* 1996; 11: 218-9.
- Dunn R, Hantes J. Double cervix and vagina with a normal uterus and blind cervical pouch: a rare mullerian anomaly. *Fertil Steril* 2004; 82: 458-9.
- Goldberg JM, Falcone T. Double cervix and vagina with a normal uterus: an unusual Mullerian anomaly. *Hum Reprod* 1996; 11: 1350-1.
- Varras M, Akrivis C, Demou A, Kitsiou E, Antoniou N. Double vagina and cervix communicating bilaterally with a single uterine cavity: report of a case with an unusual congenital uterine malformation. *J Reprod Med* 2007; 52: 238-40.
- Shirota K, Fukuoka M, Tsujioka H, Inoue Y, Kawarabayashi T. A normal uterus communicating with a double cervix and the vagina: a mullerian anomaly without any present classification. *Fertil Steril* 2009; 91: 935.e1-3.
- Pabuccu R, Gomel V. Reproductive outcome after hysteroscopic metroplasty in women with septate uterus and otherwise unexplained infertility. *Fertil Steril* 2004; 81: 1675-8.
- Heinonen PK. Complete septate uterus with longitudinal vaginal septum. *Fertil Steril* 2006; 85: 700-5.
- Lavergne N, Aristizabal J, Zarka V, Erny R, Hedon B. Uterine anomalies and in vitro fertilization: what are the results? *Eur J Obstet Gynecol Reprod Biol* 1996; 68: 29-34.
- Attia KI, Hug-Koronya M, Ginsburg ES, Hornstein MD. Effects of Mullerian anomalies on in vitro fertilization outcome. *J Assist Reprod Genet* 2001; 18: 544-7.
- Ozgur K, Isikoglu M, Donmez L, Oehninger S. Is hysteroscopic correction of an incomplete uterine septum justified prior to IVF? *Reprod Biomed Online* 2007; 14: 335-40.
- Mollo A, De Francis P, Colacurci N, Cobellis L, Perino A, Venezia R, et al. Hysteroscopic resection of the septum improves the pregnancy rate of women with unexplained infertility: a prospective controlled trial. *Fertil Steril* 2009; 91: 2628-31.

= 국문초록 =

현재의 분류에는 포함되지 않는 드문 형태의 뿔러관 기형이 최근 보고되고 있다. 30세의 미산부 여성이 2년간의 불임을 주소로 내원하였다. 복강경상 자궁 저부 및 난관의 상태는 정상이었다. 자궁경상 중복 자궁경관 및 질중격을 확인하였고 자궁 하단 부에서 교통이 있는 완전 중격 자궁을 확인하였다. 오른쪽 자궁경관을 통해 자궁경하 중격제거술을 성공적으로 시행하였다. 자궁협부에 교통이 있는 중복 자궁경관 및 질중격을 가진 완전 중격 자궁의 변형된 예로서 자궁경을 통한 수술을 통해 치료될 수 있었다.

중심단어: 중격 자궁, 중복 자궁 경관, 질중격, 자궁경하 중격제거술