

김신태, 이선녕, 이석정, 정필문, 박홍준, 신명상, 김종환, 이부길, 김상하, 리원연, 신계철, 용석중

2 Cases of *Mycoplasma pneumoniae* Infection with Severe Pneumonia

Shin-Tae Kim, M.D., Shun Nyung Lee, M.D., Seok Jeong Lee, M.D., Pil Moon Jung, M.D.,
Hong Jun Park, M.D., Myung Sang Shin, M.D., Chong Whan Kim, M.D., Bu Ghil Lee, M.D.,
Sang-Ha Kim, M.D., Won-Yeon Lee, M.D., Kye Chul Shin, M.D., Suk Joong Yong, M.D.
Department of Internal Medicine, Yonsei University Wonju College of Medicine, Wonju, Korea

Mycoplasma pneumoniae (*M. pneumoniae*) is the leading cause of pneumonia in older children and young adults. Normally, it does not progress to a condition requiring hospitalization but improves spontaneously or has a mild clinical course. We report two cases of *M. pneumoniae* pneumonia with different clinical manifestations from the normal course. The patients were young healthy individuals. The diagnoses were made by serology. However, it could not be determined beforehand that they had *M. pneumoniae* pneumonia. Based on the empirical treatment strategy of severe community acquired pneumonia, the patients were treated with broad-spectrum antibiotics including cephalosporin, quinolone and macrolide. After administering the antibiotics, they showed a gradually favorable clinical course and recovered without residual complications. A *M. pneumoniae* infection should be considered as a cause of severe community acquired pneumonia, and empirical treatment targeting this organism might be helpful in treating patients with the severe manifestation. (*Tuberc Respir Dis* 2007;63:515-520)

Key Words: *Mycoplasma pneumoniae*, Severe pneumonia, Quinolone, Macrolide

서 론

M. pneumoniae

M. pneumoniae , , , , ,

2

5~10%

증 례

증례 1

29

가 4

. 8

가

가

M. pneumoniae

가

(anti-human immunodeficiency virus antibody, HIV)

가

Address for correspondence: Suk Joong Yong, M.D.
Department of Internal Medicine, Yonsei University Wonju
College of Medicine, 162, Ilsan-dong, Wonju 220-701, Korea
Phone: 82-33-741-1232, Fax: 82-33-746-4667
E-mail: sjyong@yonsei.ac.kr

Received: Oct. 12, 2007

Accepted: Nov. 6, 2007

130/90 mmHg,

96 / ,

20 /

38°C

3

cefoperazone,
sulbactam isepamicin levofloxacin

6,110/mm³ (86.3%, 9.2%,
2.4% 1.3%), 9.1 g/dl, 241,000/
mm³ 가 pH 7.431, PaCO₂ 36.2
mmHg, PaO₂ 65.2 mmHg, HCO₃⁻ 23.5 mmol/L,
93.5% , , ,
(PCR)
C- 32.30 mg/d , 가 ,
X- .
X-
2 *M.*
pneumoniae IgG 457.8 HL/D/P(>100), *M. pneu-*

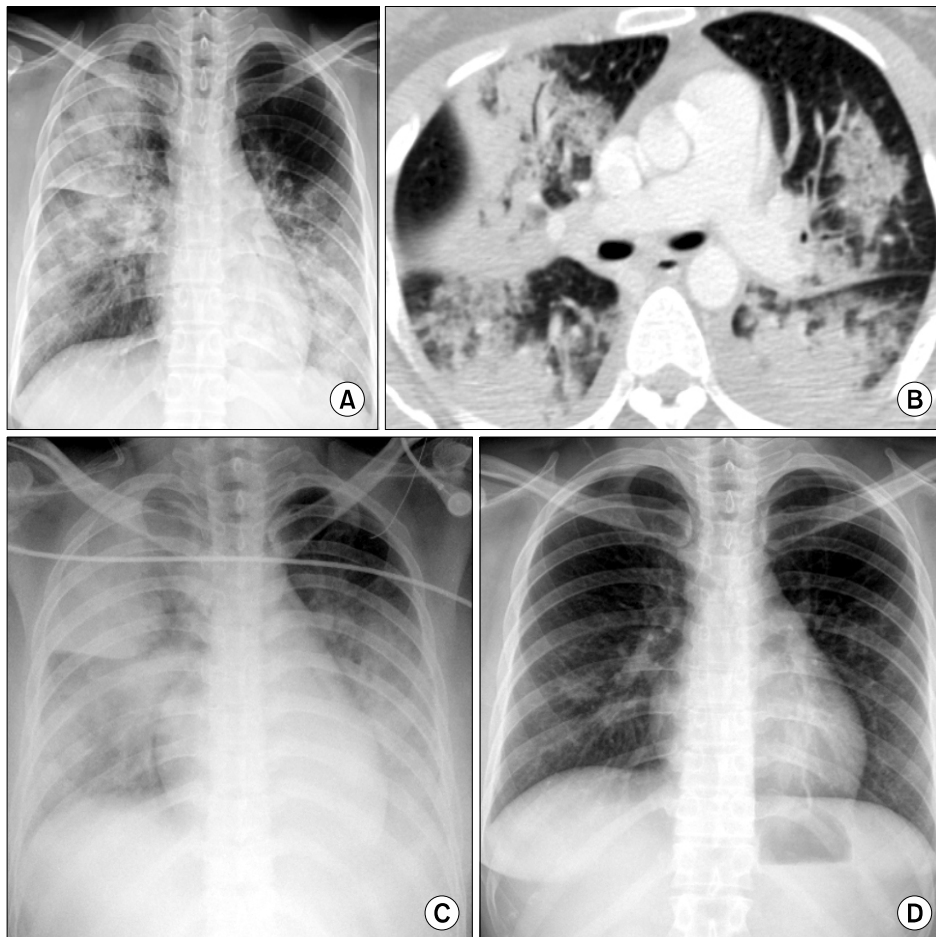


Figure 1. A 29-year-old woman with *M. pneumoniae* pneumonia. Chest radiograph at admission reveals bilateral, patch and lobar consolidation in right upper and left lower lung field (A). Chest CT scan, 2 days later, shows multi-focal consolidation (B). Follow up chest radiograph, 3 days later, shows more extensive bilateral consolidation (C). Follow up chest radiograph, 9 days later, shows nearly complete resolution (D).

moniae IgM 269.5 HL/D/P(>770) 5 증례 2
 clarithromycin 1,000 mg 가 29 가 7
 7 2 L/min 가 ,
 pH 7.445, PaCO₂ 39.7 mmHg, PaO₂ 69.1 가 HIV
 mmHg, HCO₃⁻ 26.7 mmol/L, 94.5% .
 X- 7 130/70 mmHg,
 가 1 : 16 84 / , 20 / , 36.9°C
 1 : 64 가 , 11 M.
pneumoniae IgG/IgM 4200/1733.9 HL/D/P
M. pneumoniae 8,720/mm³ (88.4%,
 11 7.3%, 2.9% 0.7%), 13.9
 g/dL, 273,000/mm³ 가
 pH 7.402, PaCO₂ 38.9 mmHg, PaO₂ 76.3 mmHg, HCO₃⁻
 23.7 mmol/L, 95.3% .

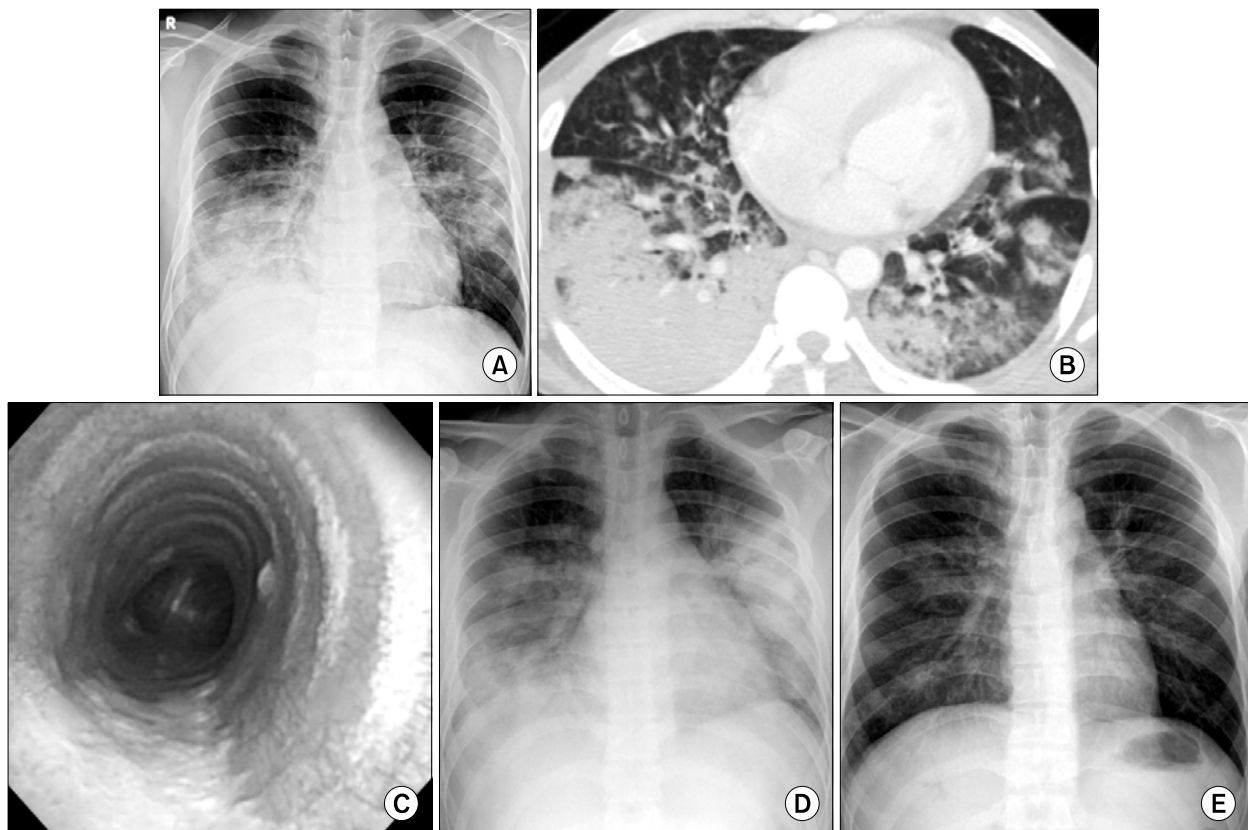


Figure 2. A 29-year-old man with *M. pneumoniae* pneumonia. Chest radiograph at admission reveals bilateral , patch and lobar consolidation in right lower and left upper lung field (A). Chest CT scan shows multi-focal lobar consolidation, mainly in right lower lobe, with pleural effusion (B). Fiberoptic bronchoscopy shows ulcerative lesion covered with necrotic exudation on the posterior wall of trachea (C). Follow up chest radiograph, 3days later, shows more aggravated consolidation (D). Follow up chest radiograph, 13 days later, shows improved state (E).

Table 1. Cases of *M. pneumoniae* pneumonia with severe manifestation in Korea

Age/Sex	Clinical manifestation	Cold agglutinin titer	<i>M. pneumoniae</i> Ab	Treatment	Reference
27/F	ARDS, pleural effusion, Raynaud's phenomenon	1 : 512	≥1 : 10,240	Cephalosporin, Aminoglycoside → Erythromycin added	8
43/F	ARDS	?	Positive*	Treated by erythromycin after extubation	9
25/M	ARDS, seizure, hemolytic anemia	1 : 1,024	1 : 20,480	Cephalosporin, Aminoglycoside → Erythromycin added	10
19/F	Extensive bilateral airspace consolidation, pneumonia, pleural effusion	1 : 40	1 : 160	Empirical antibiotics(?)+ Methylprednisolone	11
68/M	ARDS, erythematous skin lesion	1 : 640 [†]	1 : 64 [†]	Cefamandole, Roxithromycin → Cefotaxime, Tobramycin, Roxithromycin+Prednisolone	12

*titer not described, [†] negative in initial finding.
ARDS=Acute respiratory distress syndrome.

M. pneumoniae

IgG가 ,
IgM
IgG , 2
M. pneumoniae
1.
가
,
가
9,
M. pneumoniae
10.
가
11.
가
12.

M. pneumoniae

IgG . 2
(upper trachea)
M. pneumoniae
. 2.
,
1990
levofloxacin, moxifloxacin
clarithromycin
erythromycin
90%
¹³. *M. pneumoniae*가

M. pneumoniae

요 약

M. pneumoniae

가

M. pneumoniae 2

M. pneumoniae

가

M.

pneumoniae IgG IgM

가

M. pneumoniae

가

M. pneumoniae

가

참 고 문 헌

1. Cassell GH. Severe Mycoplasma disease: rare or under-diagnosed? West J Med 1995;162:172-5.
2. Murray JF, Nadel JA. Textbook of respiratory medicine.

- 4th ed. Philadelphia: Elsevier Saunders; 2005.
3. Petitjean J, Vabret A, Gouarin S, Freymuth F. Evaluation of four commercial immunoglobulin G (IgG)- and IgM-specific enzyme immunoassays for diagnosis of *Mycoplasma pneumoniae* infections. J Clin Microbiol 2002;40:165-71.
4. Jang BI, Kim HI, Kim SS, Lee CK, Chung JH, Lee KH, et al. A case of *Mycoplasma pneumoniae* complicated with acute respiratory failure. Tuberc Respir Dis 1992; 39:194-8.
5. Kim ES, Lee WS, Lee KR, Lee JA, Baek YJ, Lee GS, et al. A case of *Mycoplasma pneumoniae* which progressed to ARDS. Tuberc Respir Dis 1996;43:645-50.
6. Kwag JS, Ko TY, Chung BS, Lee SB, Oh KS, Park SJ, et al. A case of fulminant *Mycoplasma pneumoniae* complicated with ARDS and hemolytic anemia. Tuberc Respir Dis 1998;46:636-42.
7. Choi SM, Han CM, Kang JH, Chang WI, Kim CH, Kim KH, et al. Extensive bilateral airspace consolidation. Tuberc Respir Dis 1999;46:735-40.
8. Yu CW, Cheong HJ, Kang MS, Woo HJ, Kim WJ, Kim MJ, et al. A case *Mycoplasma pneumoniae* pneumonia with acute respiratory distress syndrome (ARDS). Korean J Med 2000;70:94-100.
9. Chan ED, Welsh CH. Fulminant *Mycoplasma pneumoniae* pneumonia. West J Med 1995;162:133-42.
10. Fraley DS, Ruben FL, Donnelly EJ. Respiratory failure secondary to *Mycoplasma pneumoniae* infection. South Med J 1979;72:437-40.
11. Taylor-Robinson D, Furr PM. Models of infection due to mycoplasmas, including *Mycoplasma fermentans*, in the genital tract and other sites in mice. Clin Infect Dis 1993;17:S280-2.
12. Brunner H, Horswood RL, Chanock RM. More sensitive methods for detection of antibody to *Mycoplasma pneumoniae*. J Infect Dis 1973;127:S52-5.
13. Waites KB, Talkington DF. *Mycoplasma pneumoniae* and its role as a human pathogen. Clin Microbiol Rev 2004;17:697-728.