

An Atraumatic Fracture of the Odontoid Process in a Newly Diagnosed Rheumatoid Arthritis Patient

Doo-Ho Lim, Seung-Hyeon Bae, Jong Han Choi, Dong Hui Cho, Yong-Gil Kim, Chang-Keun Lee, Bin Yoo

Division of Rheumatology, Department of Internal Medicine, Asan Medical Center, University of Ulsan College of Medicine, Seoul, Korea

Rheumatoid arthritis (RA) is a systemic autoimmune disorder which can affect all of the synovial joints including the cervical spine. Cervical involvement typically begins early in the disease process and shows relatively slow progression. Fractures of the odontoid process are mainly noted after a major trauma to the cervical spine. A case of a 77-year-old woman with paresthesia of the extremities caused by spontaneous atraumatic fracture of the odontoid process, which was revealed as a manifestation of RA, is presented in this report. (*J Rheum Dis* 2015;22:102-105)

Key Words. Spontaneous fractures, Odontoid process, Rheumatoid arthritis

INTRODUCTION

Rheumatoid arthritis (RA) is a chronic inflammatory disease with an unknown etiology marked by a progressive, commonly symmetric and erosive synovitis of the peripheral joints. RA also has a predilection for the cervical spine and is the most common inflammatory disorder affecting the spine [1]. The prevalence of radiologic cervical spine involvement in RA ranges from 17% to 85% and cervical involvement typically begins early in disease process and is progressive slowly. The most prevalent abnormality of the cervical spine in RA is atlantoaxial subluxation, followed by atlantoaxial impaction and subaxial subluxation [1]. However, fracture of the odontoid process rarely occurs.

Odontoid fractures are mostly manifested after trauma to the cervical spine. However, an RA patient may undergo an odontoid fracture spontaneously, and it is supposed to be related with a long disease duration and steroid therapy [1,2]. To our knowledge, atraumatic odontoid fractures in RA have been reported in 13 cases with more than 1 year duration of treatment [2-8]. Here, we present the case of spontaneous odontoid fracture in newly diagnosed RA patient.

CASE REPORT

A 77-year-old woman was admitted to our hospital with one month history of paresthesia in both her forearms and legs. She also complained of intermittent posterior neck pain without a recent trauma history. She did not appeal arthralgia and she was full time housewife. This patient had been diagnosed with diabetes mellitus 20 years and hypertension 10 years previously. She took metformin (500 mg twice daily), glimepiride (2 mg twice daily), losartan (50 mg once daily) and amlodipine (5 mg once daily).

Upon examination, her vital signs were stable. She showed motor strength grade 5/5 in four extremities and no abnormal neurologic reflexes. Swelling of the right 4th proximal interphalangeal (PIP) joint was detected with mild tenderness. No other swollen or tender joints were evident. Initial laboratory findings included an erythrocyte sedimentation rate of 51 mm/h (normal range, 0 to 20 mm/h), C-reactive protein level of 0.23 mg/dL (0.0 to 0.6 mg/dL), rheumatoid factor level of 10.6 IU/mL (0 to 15 IU/mL), and an anticyclic citrullinated peptide antibody count of more than 340 U/mL (0 to 7 IU/mL). A complete blood cell count and liver function tests gave results that

Received : March 3, 2014, **Revised :** April 30, 2014, **Accepted :** May 14, 2014

Corresponding to : Yong-Gil Kim, Division of Rheumatology, Department of Internal Medicine Asan Medical Center, University of Ulsan College of Medicine, 88 Olympic-ro 43-gil, Songpa-gu, Seoul 138-736, Korea. E-mail: bestmd2000@amc.seoul.kr.

pISSN: 2093-940X, eISSN: 2233-4718

Copyright © 2015 by The Korean College of Rheumatology. All rights reserved.

This is a Free Access article, which permits unrestricted non-commercial use, distribution, and reproduction in any medium, provided the original work is properly cited.

were within normal limits. Simple radiography analysis of both hands revealed space narrowing with bone erosion in the right 4th PIP joint and marginal bone erosion in the right 5th PIP and left 5th metacarpophalangeal joints (Figure 1). Considering these findings, a diagnosis of RA was established in accordance with the 2010 RA classification criteria of the American College of Rheumatology Board of Directors and the European League against Rheumatism (EULAR) Executive Committee [9].

Plain radiographs of the lateral cervical spine in this patient revealed atlantoaxial subluxation but no odontoid process fracture (Figure 2A and 2B). However, subsequent computed tomography (CT) scans of her cervical spine indicated a type II fracture of the odontoid

process and anterior displacement of the C1 vertebra (Figure 2C and 2D). Magnetic resonance imaging (MRI) revealed spinal cord compression at the C2 level (Figure 2E). The dual-energy x-ray absorptiometry (DEXA) exam showed osteopenia (T score of L1 to L4: -2.0 , T score of femur: -1.6) but there was no compression fracture of the spine.

The patient subsequently underwent a posterior decompression and occipital-C4 fusion (Figure 3). She began to take methotrexate (10 mg once per week) and methylprednisolone (4 mg once daily). She wore a halo vest for 10 weeks and had an uneventful recovery. At one-year follow up, this patient has been free of paresthesia and neck pain.

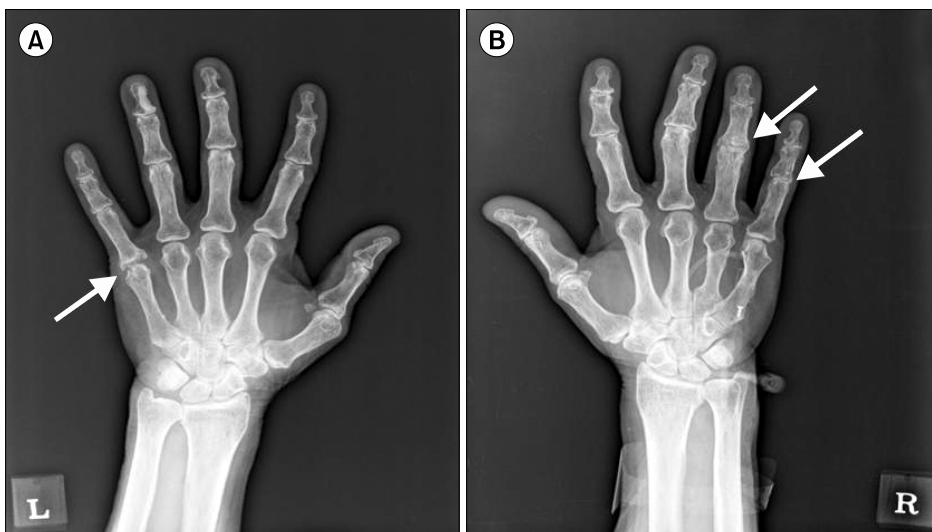


Figure 1. Plain radiographs of both hands showed a marginal bone erosion in the left 5th metacarpophalangeal joint (A; white arrow) and joint space narrowing with marginal bone erosion in the right 4th and 5th proximal interphalangeal joints (B; white arrows).

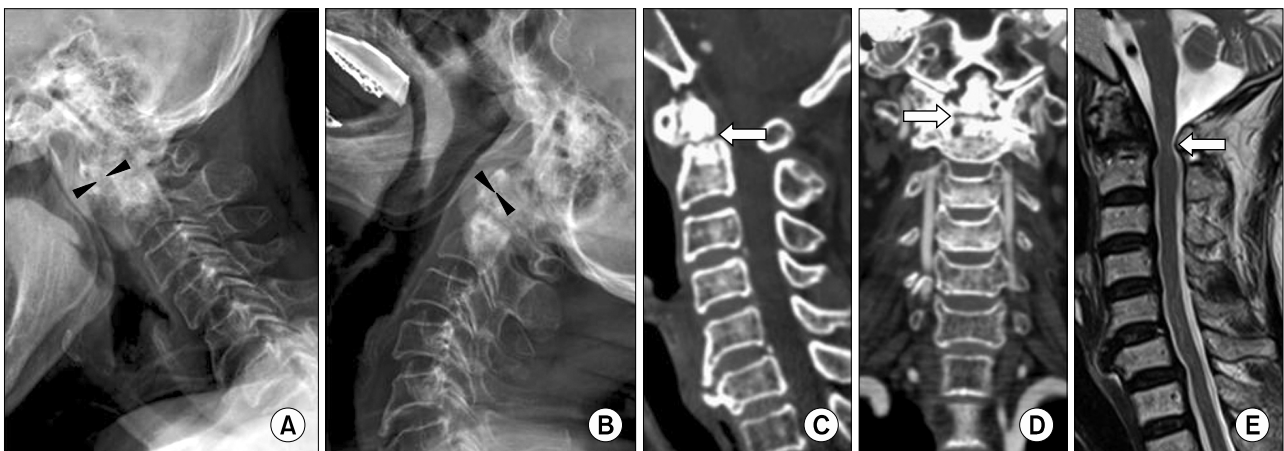


Figure 2. Lateral radiographs of the cervical spine in flexion (A) and extension (B). In flexion, the distance between the posterior aspect of the anterior ring of atlas and the anterior surface of the odontoid process (arrowheads) was 6 mm and showed atlantoaxial subluxation. Computed tomography scanning revealed a fracture of the odontoid process (C and D; white arrows). T2 weighted sagittal magnetic resonance imaging revealed C2 level spinal cord compression (E; white arrow).

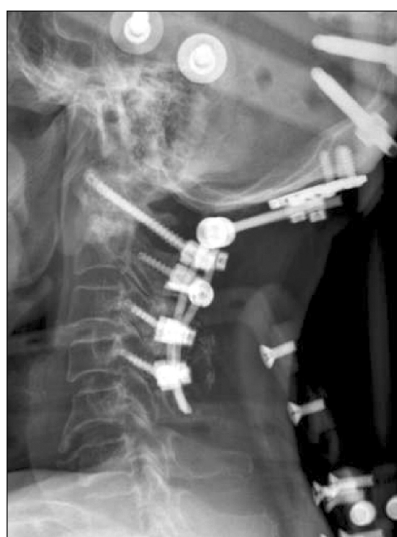

Figure 3. Postoperative lateral plain radiograph of the cervical spine showing posterior occipital-C4 fusion.

DISCUSSION

Cervical involvement in RA typically begins early in the disease course and is both frequently progressive and potentially devastating [1]. One study prospectively followed a cohort of 140 patients with definite or classical RA that initially had no cervical involvement for at least 5 years. At the end of the follow-up in that series, 43.6% of the patients had developed cervical instabilities, which were judged as severe in 12.9% of the total cases [10]. The most frequent abnormality of the cervical spine is atlantoaxial subluxation with a frequency of 65% in RA patients. This is followed by atlantoaxial impaction (cranial settling) and subaxial subluxation with frequency of up to 20% and 15%, respectively [1]. Atraumatic odontoid fractures in RA patients are rare and several cases have been reported to date [2-8]. The symptoms caused by odontoid fracture often appear very suddenly and vary from neck pain and occipital headache, vertigo, and limitation of neck motion to myelopathic symptoms such as paresthesia, parareflexia and gait disturbance. In this case, she was suffered from sensory change in four extremities and intermittent posterior neck pain without motor deficit. We believe that relatively low degree of cord impingement was not enough to develop motor problem.

Simple radiographs are limited to diagnose an odontoid process fracture as the degeneration and osteopenia that accompanies RA can mask this adverse event. CT scan is more sensitive in this regard. However, the preferred modality in cases of myelopathy is MRI as it provides in-

formation about the size of the rheumatoid pannus, the status of the spinal cord, and the relationship between the structures in the upper cervical spine [1,2]. In the present case study, simple radiography did not reveal the odontoid process fracture whereas CT scans revealed this fracture clearly, with anterior displacement of the C1 vertebra. Furthermore, MRI scans revealed spinal cord compression at the C2 level, which accounts for the neurologic symptoms in this patient.

Several underlying processes could contribute to the development of an atraumatic odontoid fracture. Firstly, bone loss and synovial proliferation may lead to the destruction of the odontoid process as well as the occipital condyles and the lateral masses of the atlas. Secondly, pannus proliferation may destroy the base of the odontoid process and ligamentous structures. Third, critical vascularization of the odontoid process might cause lysis and fracture of this bony structure [2-4]. Toyama et al. [5] displayed that fatigue fracture of the odontoid process in RA patients might be caused from long disease duration, steroid induced osteoporosis, and the dynamic load to atlantoaxial subluxation. In elderly patients, spontaneous odontoid fracture can be attributed to osteoporosis or tumor. However, osteoporosis does not lead usually to atraumatic vertebral fracture above T4 [11]. In the present case, osteoporosis was not detected in DEXA and also no tumor evidence around cervical lesion was found. Therefore, we believe that synovial proliferation and inflammation in the atlantoaxial joint played important roles in the onset of the atraumatic odontoid fracture.

Indications for surgery in RA patients with cervical spine involvement include pain, instability and actual or impending myelopathy [2,4]. In RA patients with myelopathy, surgery contributes to a prolonged life span whereas conservatively treated patients have a much higher mortality rate and lower probability of neurologic improvement [1]. Type II odontoid fractures are known as the most common type of odontoid fractures and are considered relatively unstable. They occur at the base of the odontoid, between the level of the transverse ligament and the C2 vertebral body. Treatments for a type II fracture can include surgical management (anterior odontoid fixation, occipital-cervical fusion or posterior C1 ~ C2 fusion) or conservative management (cervical collar or halo vest) [12]. In the case presented herein, the patient had an odontoid fracture with anterior displacement of her C1 vertebra and atlantoaxial subluxation with neurological deficit. She underwent a posterior decompression and oc-

capital-C4 fusion followed by halo vest and her symptoms were resolved effectively.

SUMMARY

The atlantoaxial joint is commonly involved in RA whereas an atraumatic fracture of the odontoid process rarely occurs in this disease but may occasionally be fatal. A rare case of a spontaneous odontoid fracture in RA patient is here presented and was successfully treated by urgent surgery. Although previous reports show that atraumatic odontoid fractures are associated with long disease duration and steroid therapy, it also can be a manifestation of newly diagnosed RA patient.

CONFLICT OF INTEREST

No potential conflict of interest relevant to this article was reported.

REFERENCES

1. da Côtê FC, Neves N. Cervical spine instability in rheumatoid arthritis. *Eur J Orthop Surg Traumatol* 2014;24 Suppl 1:S83-91.
2. Al Khayer A, Sawant N, Emberton P, Sell PJ. Spontaneous odontoid process fracture in rheumatoid arthritis: diagnostic difficulties, pathology and treatment. *Injury* 2006;37:659-62.
3. Lewandrowski KU, Park PP, Baron JM, Curtin SL. Atraumatic odontoid fractures in patients with rheumatoid arthritis. *Spine J* 2006;6:529-33.
4. Ballard WT, Clark CR. Increased atlanto-axial instability secondary to an atraumatic fracture of the odontoid process in a patient who had rheumatoid arthritis. A case report. *J Bone Joint Surg Am* 1995;77:1245-8.
5. Toyama Y, Hirabayashi K, Fujimura Y, Satomi K. Spontaneous fracture of the odontoid process in rheumatoid arthritis. *Spine (Phila Pa 1976)* 1992;17(10 Suppl):S436-41.
6. Byrne RP, Woodward HW. Occult fracture of the odontoid process: report of case. *J Oral Surg* 1972;30:684-6.
7. Storms GE, Kruijsen MW, Van Beusekom HJ, Van de Putte LB, Boerbooms AM, Penn WH, et al. Pathological fracture of the odontoid process in rheumatoid arthritis. *Neth J Med* 1980;23:120-22.
8. Kim TH, Kim DY, Jun JB, Jung SS, Lee IH, Bae SC, et al. A case of odontoid fracture in rheumatoid arthritis. *J Korean Rheum Assoc* 1995;2:197-201.
9. Aletaha D, Neogi T, Silman AJ, Funovits J, Felson DT, Bingham CO 3rd, et al. 2010 Rheumatoid arthritis classification criteria: an American College of Rheumatology/European League Against Rheumatism collaborative initiative. *Arthritis Rheum* 2010;62:2569-81.
10. Yurube T, Sumi M, Nishida K, Miyamoto H, Kohyama K, Matsubara T, et al; Kobe Spine Conference. Incidence and aggravation of cervical spine instabilities in rheumatoid arthritis: a prospective minimum 5-year follow-up study of patients initially without cervical involvement. *Spine (Phila Pa 1976)* 2012;37:2136-44.
11. Ea HK, Weber AJ, Yon F, Lioté F. Osteoporotic fracture of the dens revealed by cervical manipulation. *Joint Bone Spine* 2004;71:246-50.
12. Elgafy H, Dvorak MF, Vaccaro AR, Ebraheim N. Treatment of displaced type II odontoid fractures in elderly patients. *Am J Orthop (Belle Mead NJ)* 2009;38:410-6.