

Pediatric Neurotrauma and Child Abuse

Chae-Yong Kim,^{1,2} Seung-Ki Kim^{1,3}

Editor of the 'Pediatric Issue',¹ Journal of Korean Neurosurgical Society, Seoul, Korea
 Chair,² Publication Committee, Korean Society for Pediatric Neurosurgery, Seoul, Korea
 President,³ Korean Society for Pediatric Neurosurgery, Seoul, Korea

Since 2015, the Korean Society for Pediatric Neurosurgery (KSPN) has published an official journal known as the *Pediatric Issue* as a supplement to the *Journal of Korean Neurosurgical Society (JKNS)*, which is the official journal of the Korean Neurosurgical Society (KNS). The *Pediatric Issue* has made a significant contribution to the enhancement of the academic level of the *JKNS*, as well as the field of pediatric neurosurgery, by covering a wide range of topics from 2015 to 2021, such as Moyamoya disease (edited by Professor Kyu-Chang Wang and Seung-Ki Kim, 2015), craniosynostosis (invited editor : Professor Joon-Ki Kang, 2016), the era of neuroendoscopy (invited editor : Professor Joong-Uhn Choi, 2017), pediatric malignant brain cancers in the molecular era (invited editor : Professor James T. Rutka, 2018), pediatric epilepsy surgery (invited editor : Professor Byung-Kyu Cho, 2019), changing concepts in spinal dysraphism during the last two decades (invited editor : Professor Dachling Pang, 2020), and secondary neurulation : the central in spinal dysraphism (invited editor : Professor Kyu-Chang Wang, 2021). The topic of the 2022 *JKNS Pediatric Issue* is pediatric neurotrauma.

Abusive head trauma is damage to the brain caused by maltreatment of the child. The collective name 'triad' has been adopted for abusive head trauma (subdural hematoma, retinal hemorrhage, and encephalopathy; Fig. 1). However, the scien-

tific evidence of this trait is limited and insufficient. Therefore, it is necessary for clinicians to better understand the pathophysiology of abusive head trauma and to establish clinical management guidelines¹⁾.

The topic of this year is 'Pediatric neurotrauma', and this issue includes child abuse. The articles of this *Pediatric Issue* will undoubtedly provide readers with current concepts and future management guidelines for pediatric neurotrauma, including the brain and spinal cord. Ten articles were contributed by leading researchers in the field from Japan and Korea. World-class scholars have participated in the writing of this *Pediatric Issue*. Dr. Junbum Park summarized the epidemiology of pediatric head trauma in Korea, and Dr. Sangjoon Chong contributed an article regarding birth injury, including cephalhematoma and subgaleal hematoma. Dr. Sang Dae Kim provided information on minor head trauma, such as growing skull fracture, traumatic cerebrospinal fluid leakage, and concussion. Dr. Eun Jin Ha contributed a major pediatric head trauma update. Dr. Seung-Jae Hyun summarized pediatric spinal traumatic injury and provided a deep perspective on spinal trauma. This issue also heavily addressed child abuse. Dr. Young Ho Gwak, who is the pediatric trauma specialist in emergency medicine, provided an overview of abusive head trauma in infants, showing us the current situation in Korea

• Received : January 26, 2022 • Accepted : February 21, 2022

• Address for reprints : **Seung-Ki Kim**

Division of Pediatric Neurosurgery, Seoul National University Children's Hospital, Seoul National University College of Medicine, 101 Daehak-ro, Jongno-gu, Seoul 03080, Korea
 Tel : +82-2-2072-2350, Fax : +82-2-744-8459, E-mail : nstthomas@snu.ac.kr, ORCID : <https://orcid.org/0000-0002-0039-0083>

This is an Open Access article distributed under the terms of the Creative Commons Attribution Non-Commercial License (<http://creativecommons.org/licenses/by-nc/4.0>) which permits unrestricted non-commercial use, distribution, and reproduction in any medium, provided the original work is properly cited.

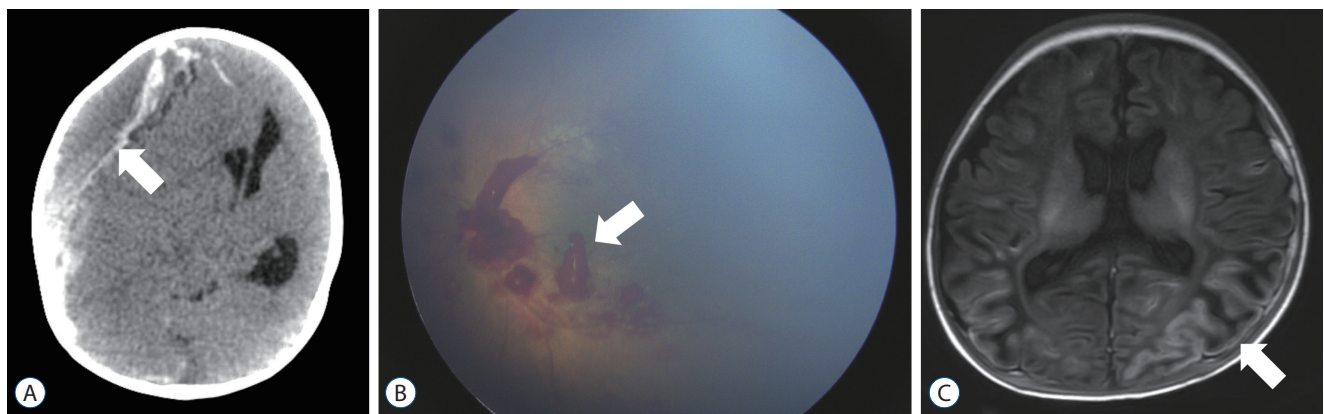


Fig. 1. Triad of abusive head trauma. A : Subdural hematoma, computed tomography axial scan. B : Retinal hemorrhages, disc photography in the left eye. C : Encephalopathy, T2-weighted axial magnetic resonance image. Each lesion is marked with an arrow.

and the perspective of the Korean social point of view. In contrast to Dr. Gwak's article, Dr. Masahiro Nonaka, an outstanding pediatric neurosurgeon in Japan, provided an overview of abusive head trauma in infants, showing us the current situation in Japan and the perspective of the Japanese social point of view. The author described subdural hematoma and child abuse in Japan compared with those in Western countries. It is interesting to note that the age distribution of subdural hematoma due to household trauma differs between Japan and the West (Japan : 8–10 months vs. Western : 2 months). Dr. Young-Soo Park, one of the leading pediatric neurosurgeons in Japan, detailed a comprehensive review regarding the complex pathophysiology of abusive head trauma with poor neurological outcomes in infants. In particular, three patterns, the underlying pathophysiology, and illustrated cases of extensive low density on brain computed tomography, were clearly described. Dr. Ji Hye Kim and Dr. Jung-Eun Cheon, pediatric radiologists in Korea, provided the basic concepts and perspectives regarding the radiologist's role in child abuse, focusing on the imaging protocol and differential diagnosis. Dr. Jae Won Kim, a pediatric psychiatrist in Korea, provided an article on the psychological aspects of child abuse and care programs as a pediatric psychologist. As child maltreatment is the damage that the child can suffer from the closest caregiver, psychological support should be initiated from the initial stage.

We deeply appreciate the brilliant minds from Korea and Japan, who actively participated in the 2022 *Pediatric Issue*. Through this special issue, we hope that many doctors facing

and treating infants and children will acquire basic knowledge about pediatric neurotrauma and related child abuse. We also hope that these small efforts will help protect children from trauma or abuse in the future.

AUTHORS' DECLARATION

Conflicts of interest

No other potential conflict of interest relevant to this article was reported.

Author contributions

Conceptualization : CYK, SKK; Project administration : CYK, SKK; Writing - original draft : CYK, SKK; Writing - review & editing : CYK, SKK

Data sharing

None

Preprint

None

ORCID

| | |
|---------------|---|
| Chae-Yong Kim | https://orcid.org/0000-0001-9773-5553 |
| Seung-Ki Kim | https://orcid.org/0000-0002-0039-0083 |

Reference

1. Elinder G, Eriksson A, Hallberg B, Lynøe N, Sundgren PM, Rosén M, et al. : Traumatic shaking: the role of the triad in medical investigations of suspected traumatic shaking. **Acta Paediatr 107 Suppl 472(Suppl Suppl 472)** : 3-23, 2018